3D Echocardiography in Mitral Para-valvular Leak

Dr. Hani Mahmoud-Elsayed

MBBCh, MSc, MD, FESC, FASE, FEACVI

Consultant cardiologist, Director of Echocardiography Lab
Aswan Heart Centre, Magdi Yacoub Foundation, Egypt

CIC
مركز فحوصات القلب
CARDIAC INVESTIGATION CENTER

Disclosure

All members of the Faculty have provided a declaration of potential or actual All members conflict of interest''

Introduction

Prosthetic paravalvular leak (PVL) is a serious complication after surgical or percutaneous valve replacement secondary to an ***inappropriate sealing*** *of the prosthetic ring to the native cardiac tissue producing peri-prosthetic regurgitation.*

Lázaro et al. Cardiovasc Diagn Ther 2014;4(4):307-313

Incidence

The real incidence of PVL is unknown and differs widely between different registries.

PVLs are more commonly detected in mechanical valves, especially in mitral position.

Paravalvular mitral leaks (PVMLs) occur in approximately 7-17% of the cases while paravalvular aortic leaks (PVALs) in 2-10% of them.

Ionescu A, et al. Heart 2003;89:1316-21

Therapy

Surgery *has been the treatment of choice in symptomatic PVLs.*

However, ***percutaneous transcatheter closure*** *is emerging as a novel and less invasive option with good outcomes in selected cases.*

Echocardiography

Echocardiography *plays an essential role in:*

- *The initial diagnosis*
- *The identification of suitable patients to undergo transcatheter intervention*
- *The intra-procedure guidance*
- *Follow up*

Hani Mahmoud-Elsayed, Echocardiography, 2020 Jun;37(6):954-964

Echocardiography

Three-dimensional (3D) TEE *has shown better diagnostic accuracy compared to two-dimensional (2D) in:*

Evaluation of leaks

In patients with multiple defects.

Hani Mahmoud-Elsayed, Echocardiography, 2020 Jun;37(6):954-964

3DTEE

Added values of 3DTEE:

- *Better localization of the leak*
- *Better definition of the size and shape*
- *Guiding percutaneous closure*

made this technique the gold standard for PVL evaluation.

Hani Mahmoud-Elsayed, Echocardiography, 2020 Jun;37(6):954-964

Localization

Hani Mahmoud-Elsayed, Echocardiography, 2020 Jun;37(6):954-964

Localization

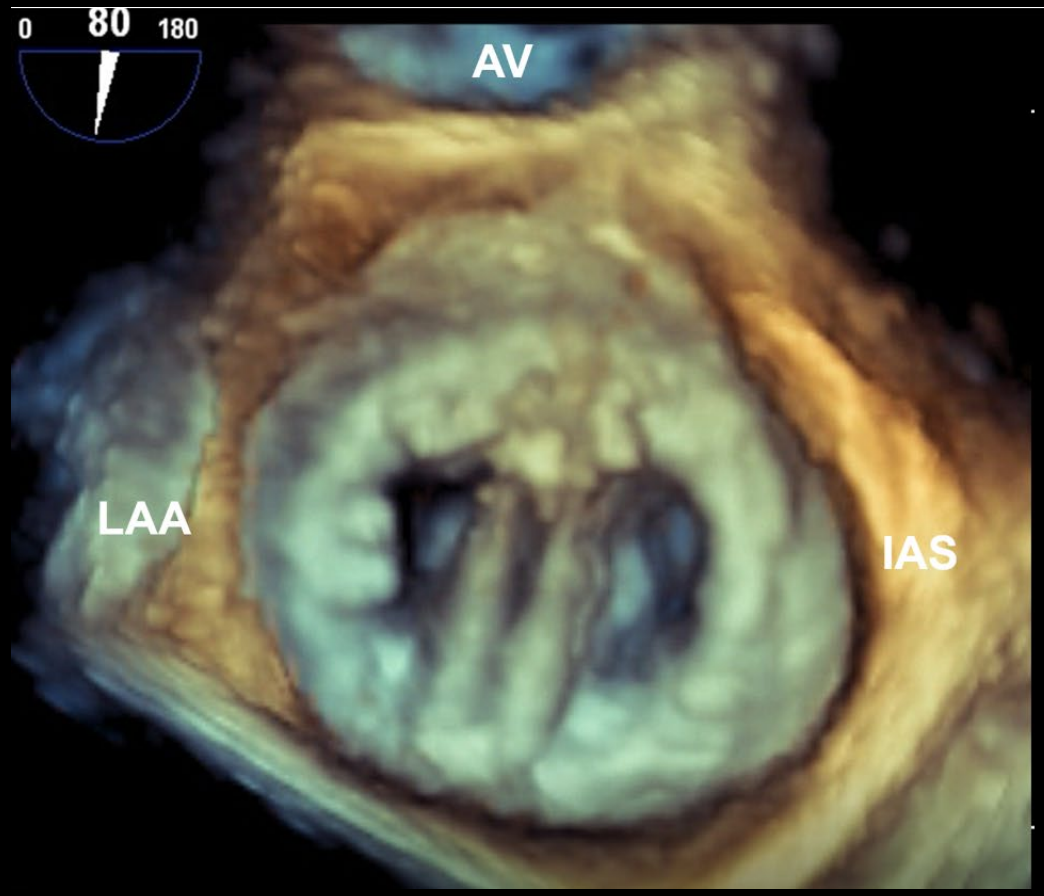

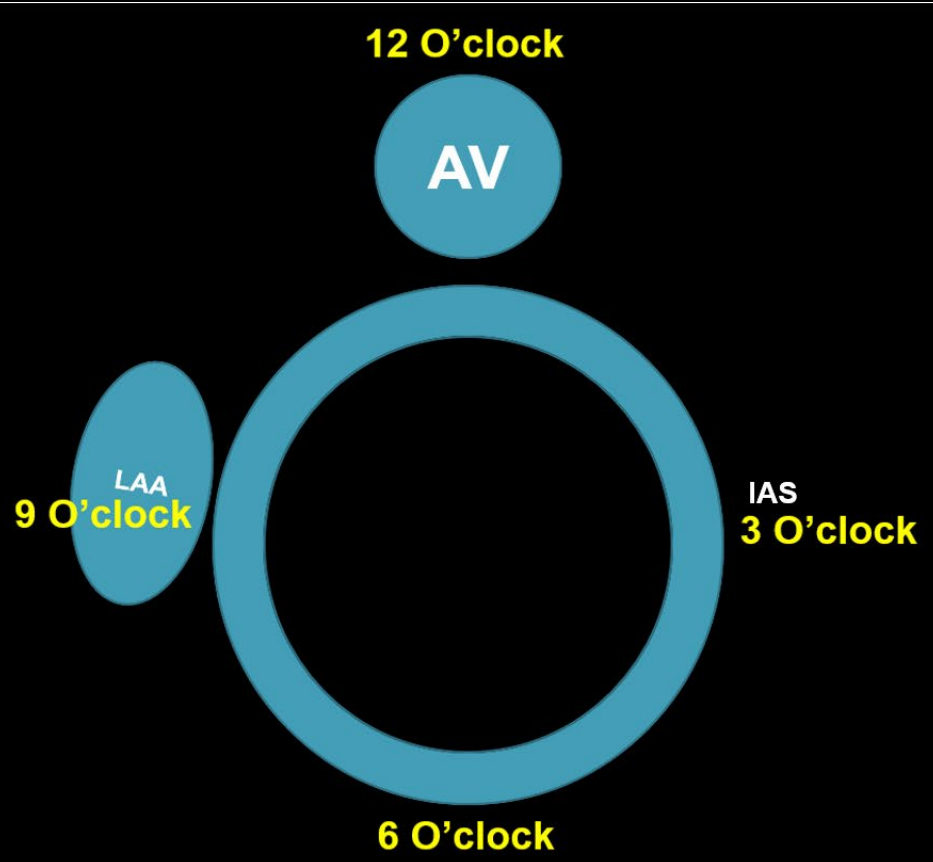

Hani Mahmoud-Elsayed, Echocardiography, 2020 Jun;37(6):954-964

Localization

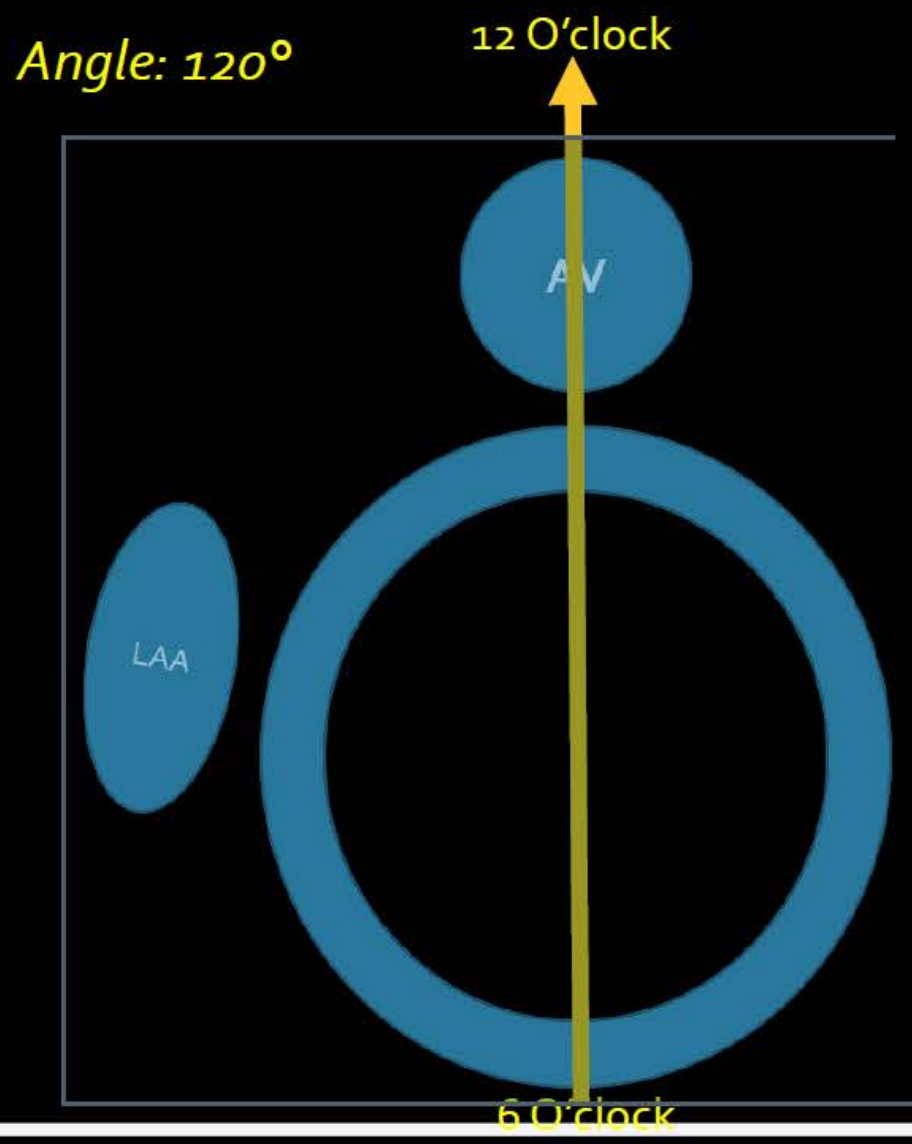

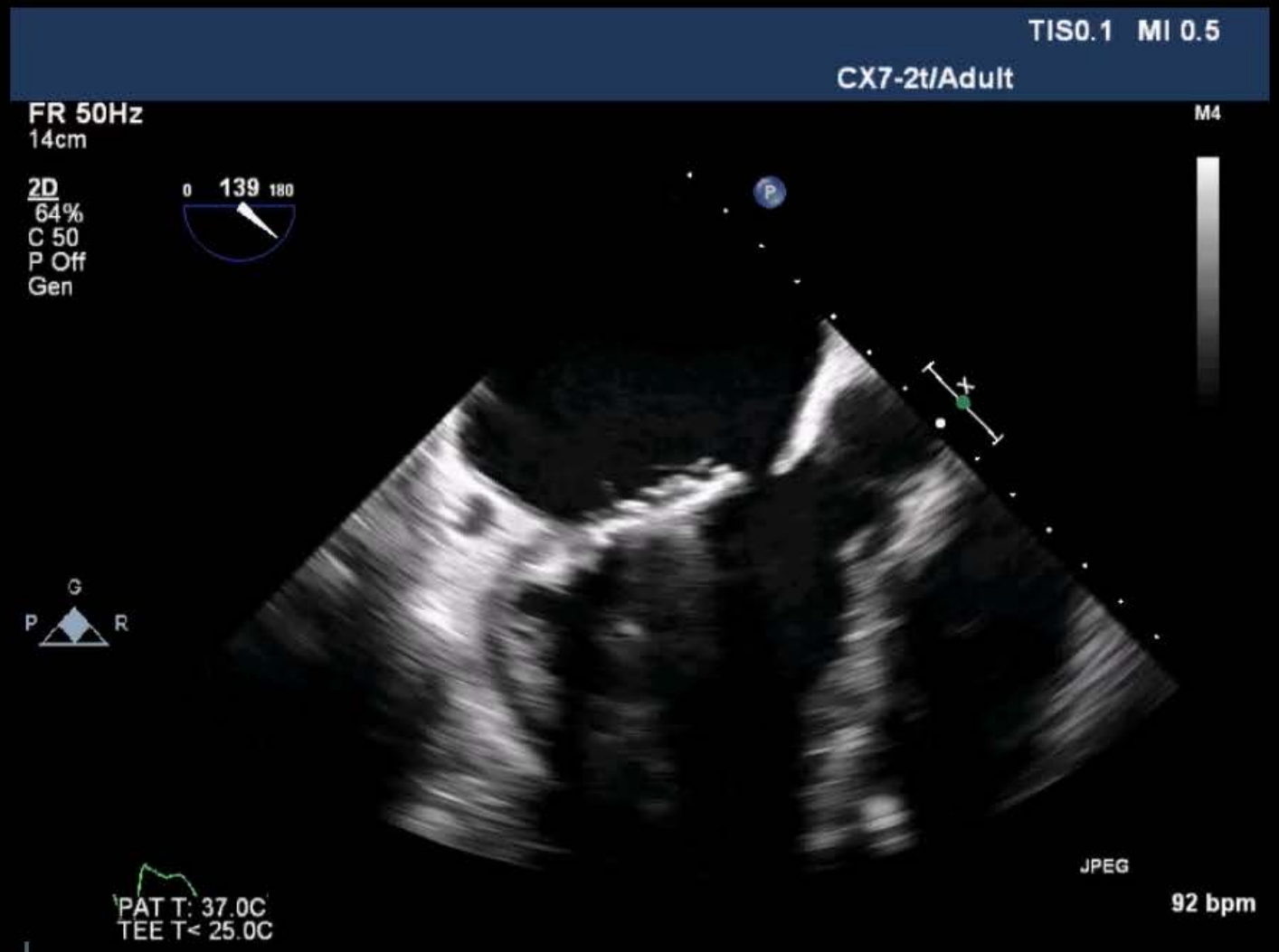

Hani Mahmoud-Elsayed, Echocardiography, 2020 Jun;37(6):954-964

Localization

Angle: 60° (3 & 6 O'clock)

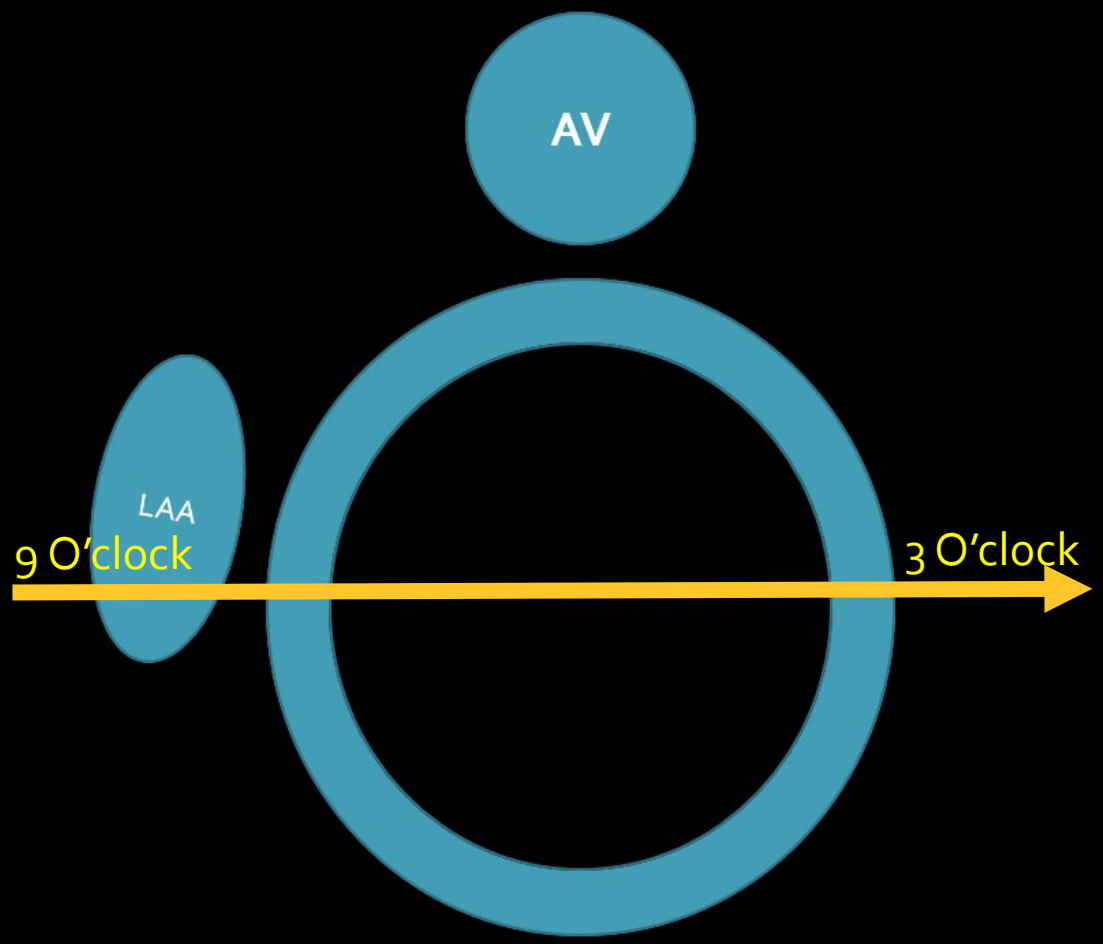

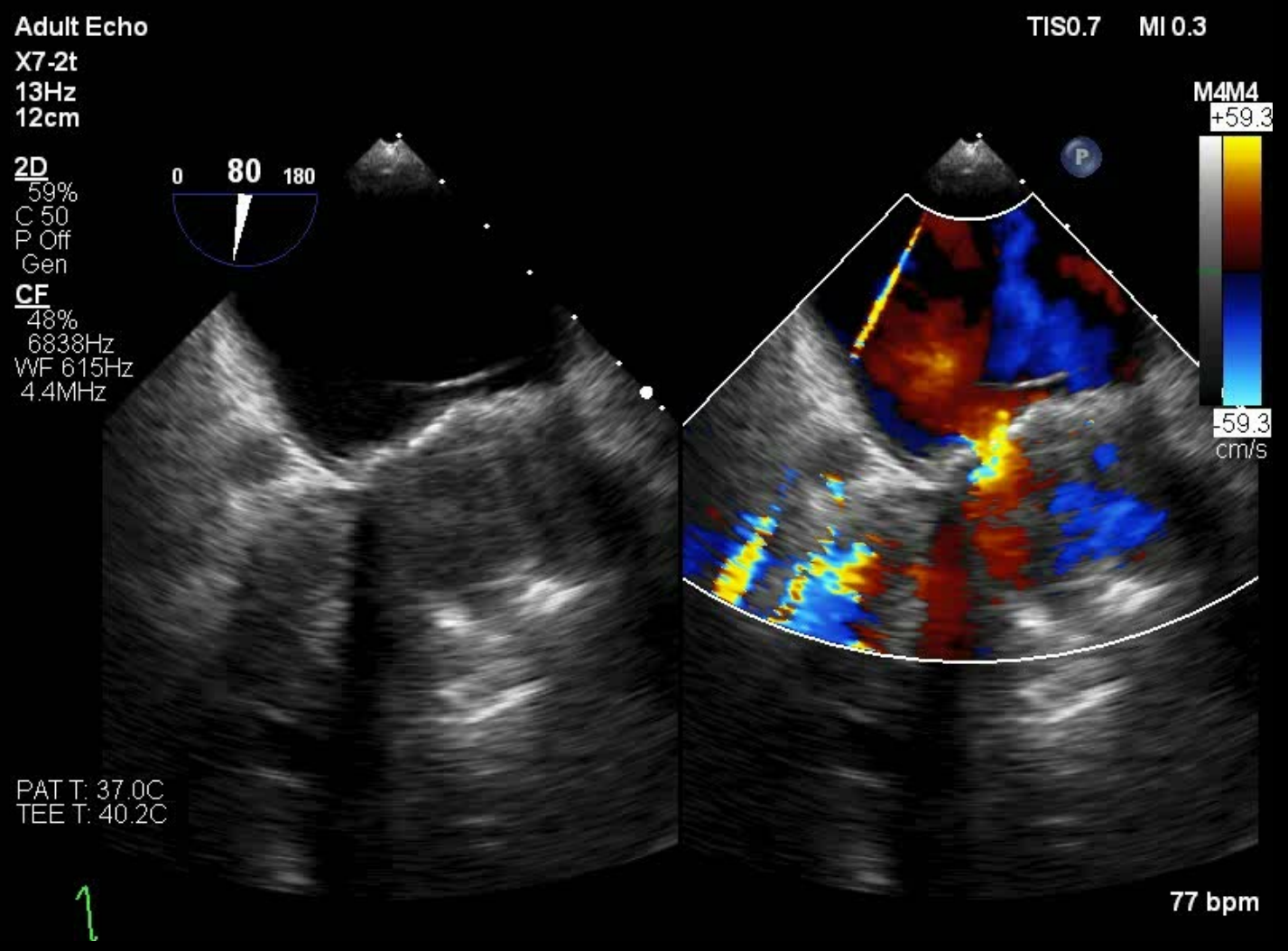

Hani Mahmoud-Elsayed, Echocardiography, 2020 Jun;37(6):954-964

Proposed protocol of imaging PVLs

Hani Mahmoud-Elsayed, Echocardiography, 2020 Jun;37(6):954-964

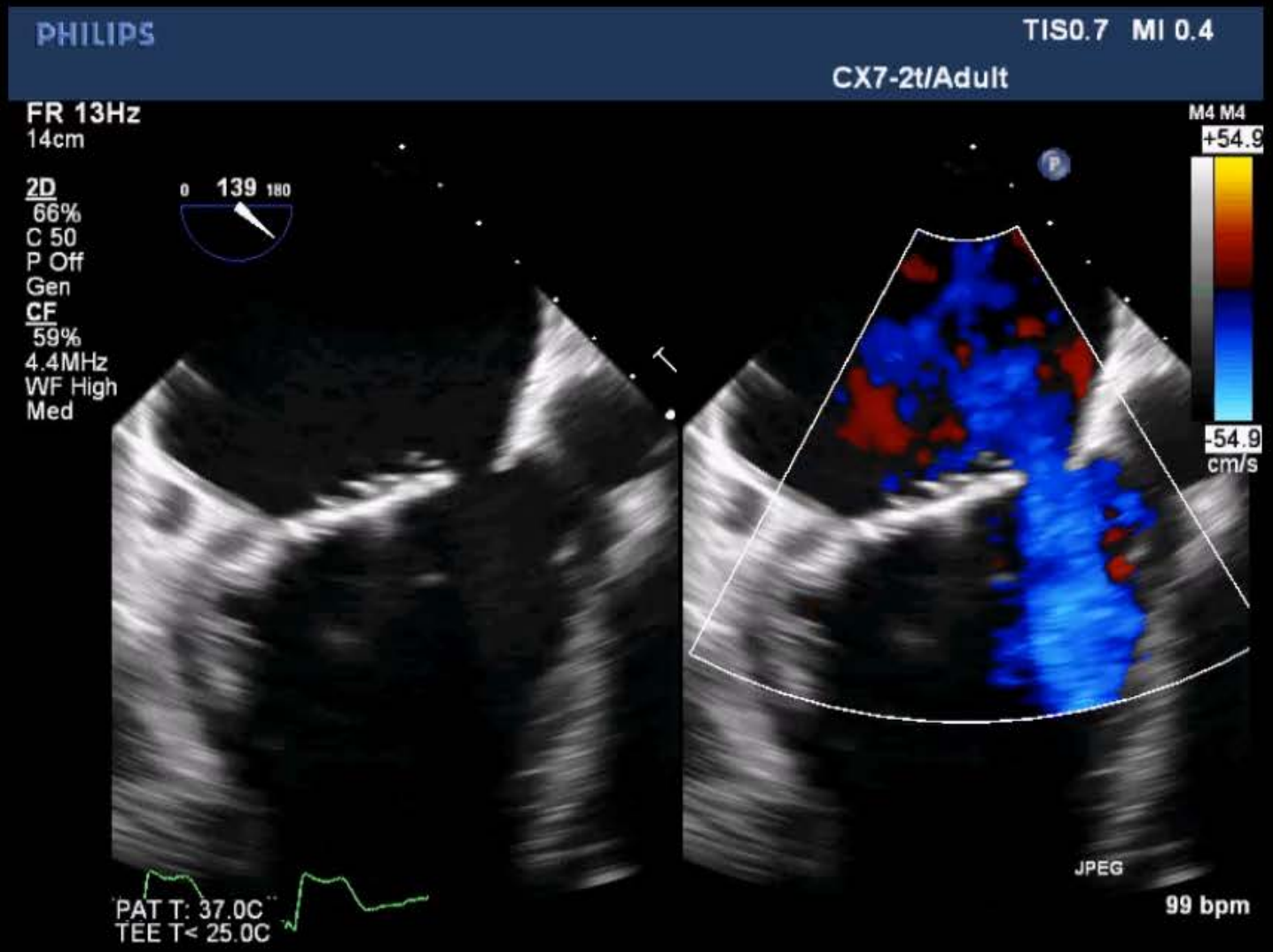

Hani Mahmoud-Elsayed, Echocardiography, 2020 Jun;37(6):954-964

Hani Mahmoud-Elsayed, Echocardiography, 2020 Jun;37(6):954-964

Hani Mahmoud-Elsayed, Echocardiography, 2020 Jun;37(6):954-964

Hani Mahmoud-Elsayed, Echocardiography, 2020 Jun;37(6):954-964

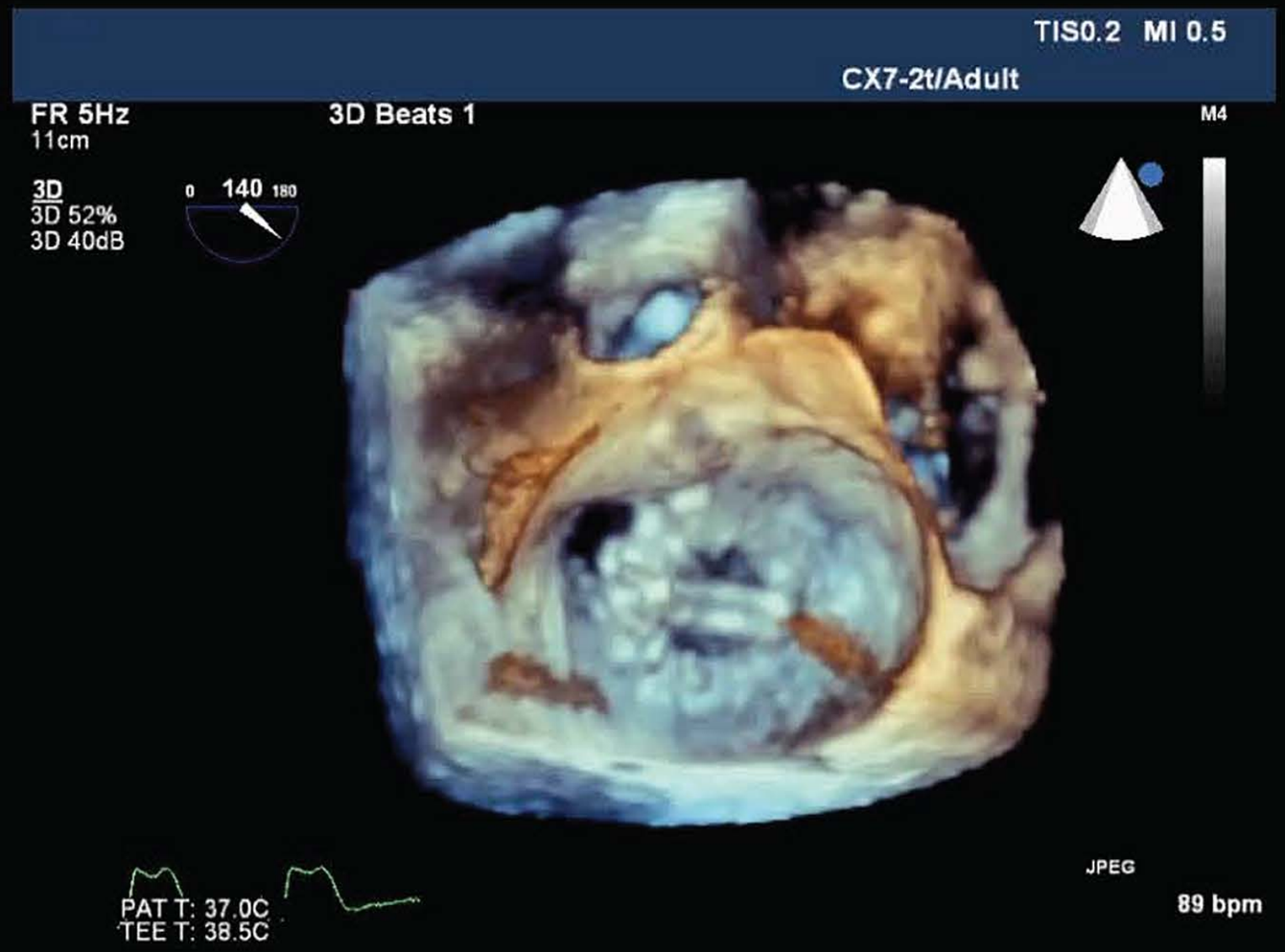

Hani Mahmoud-Elsayed, Echocardiography, 2020 Jun;37(6):954-964

Hani Mahmoud-Elsayed, Echocardiography, 2020 Jun;37(6):954-964

Imaging protocol

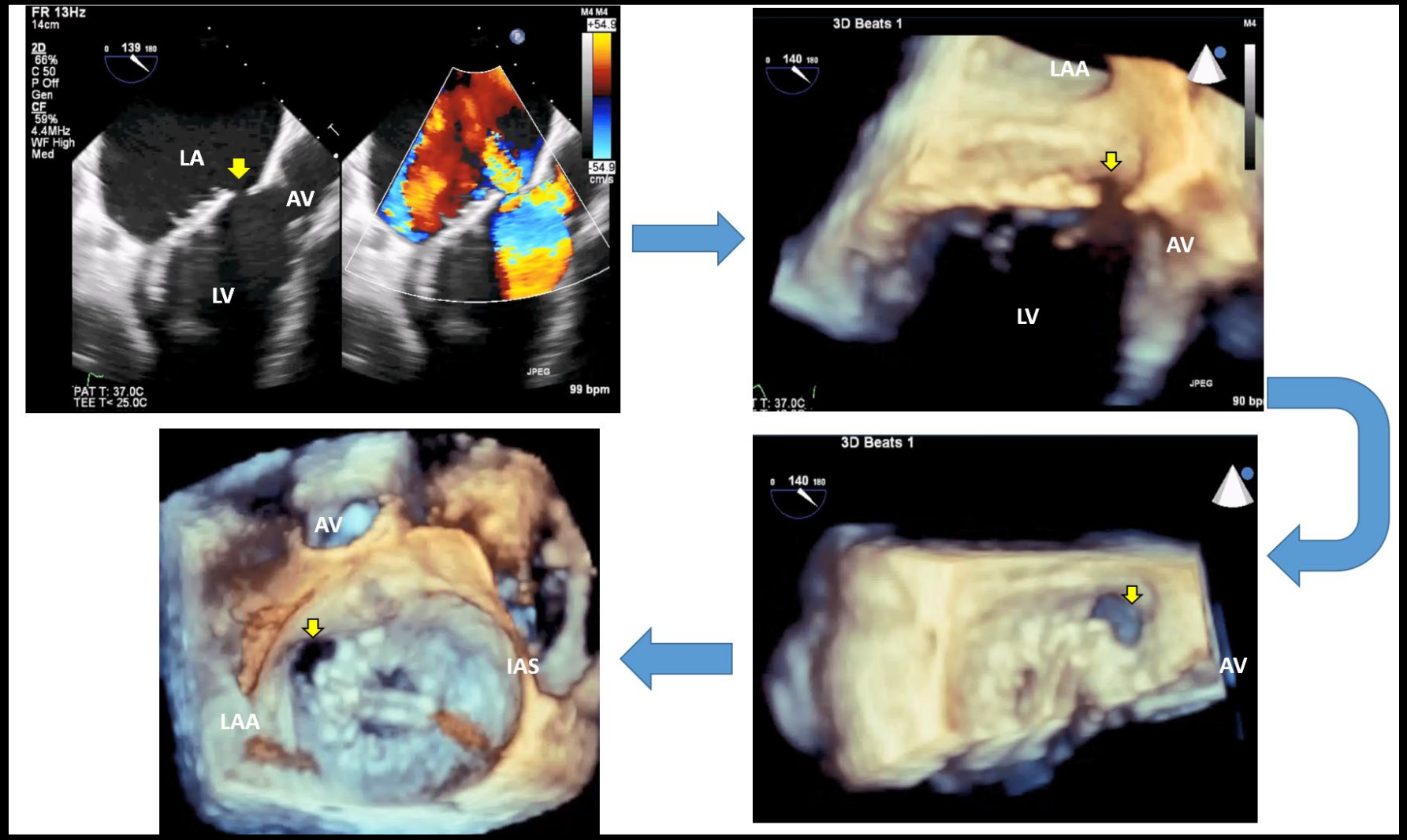

Hani Mahmoud-Elsayed, Echocardiography, 2020 Jun;37(6):954-964

PVL closure

Why?

Hani Mahmoud-Elsayed, Echocardiography, 2020 Jun;37(6):954-964

PVL closure

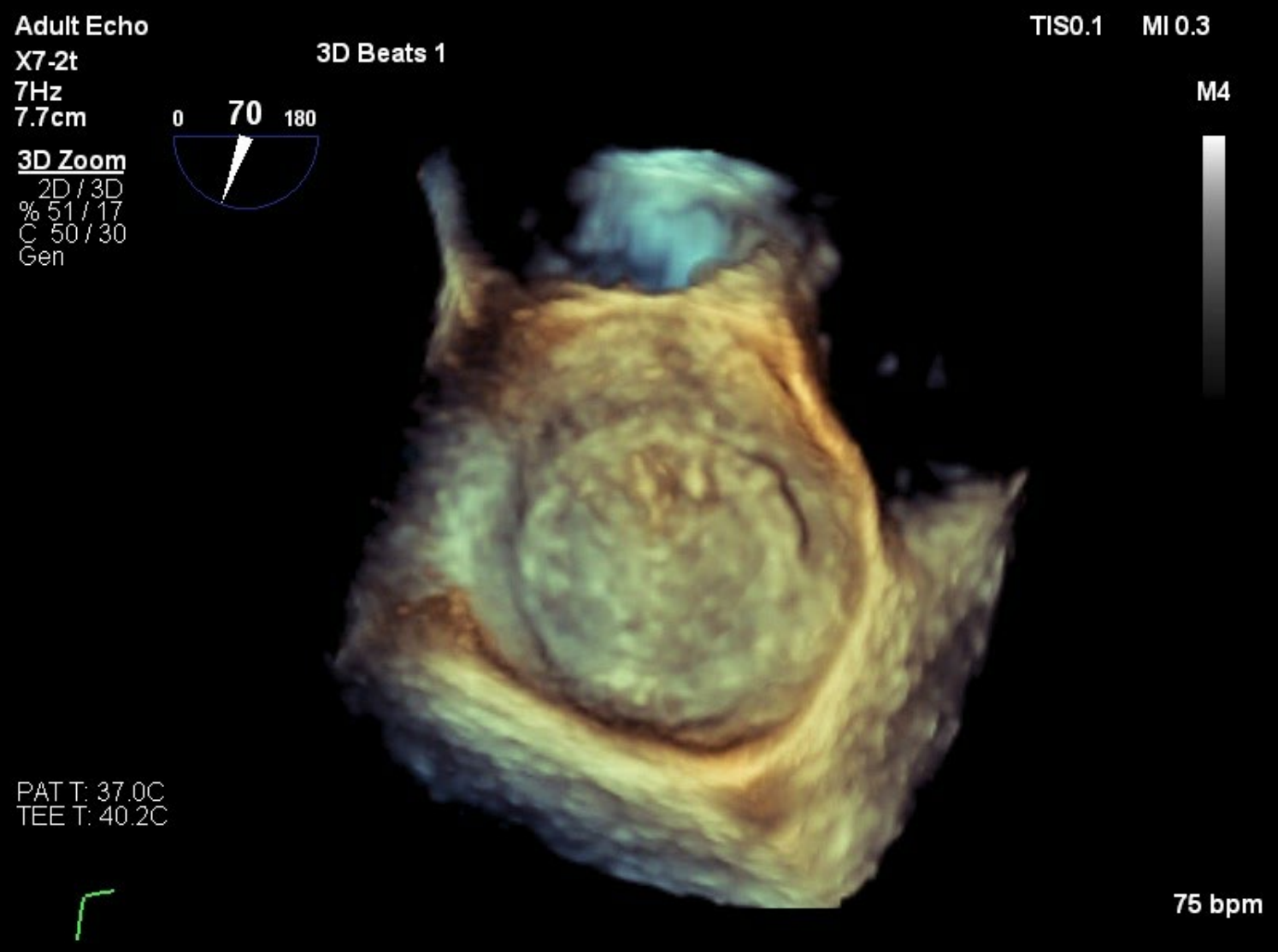

Hani Mahmoud-Elsayed, Echocardiography, 2020 Jun;37(6):954-964

PVL closure

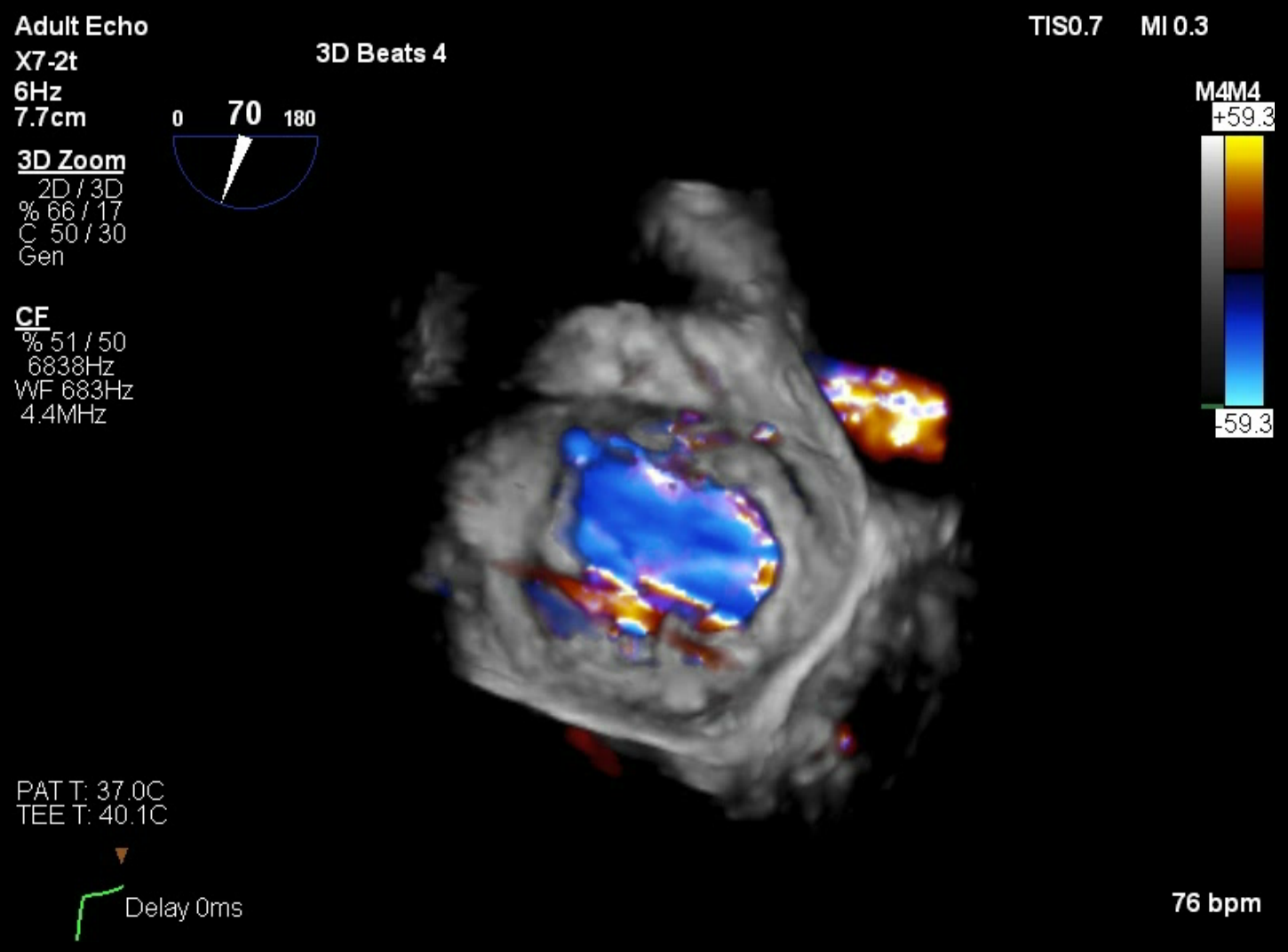

Hani Mahmoud-Elsayed, Echocardiography, 2020 Jun;37(6):954-964

Sizing & shape

Gain

Hani Mahmoud-Elsayed, Echocardiography, 2020 Jun;37(6):954-964

Gain

Hani Mahmoud-Elsayed, Echocardiography, 2020 Jun;37(6):954-964

Sizing & shape

MPR

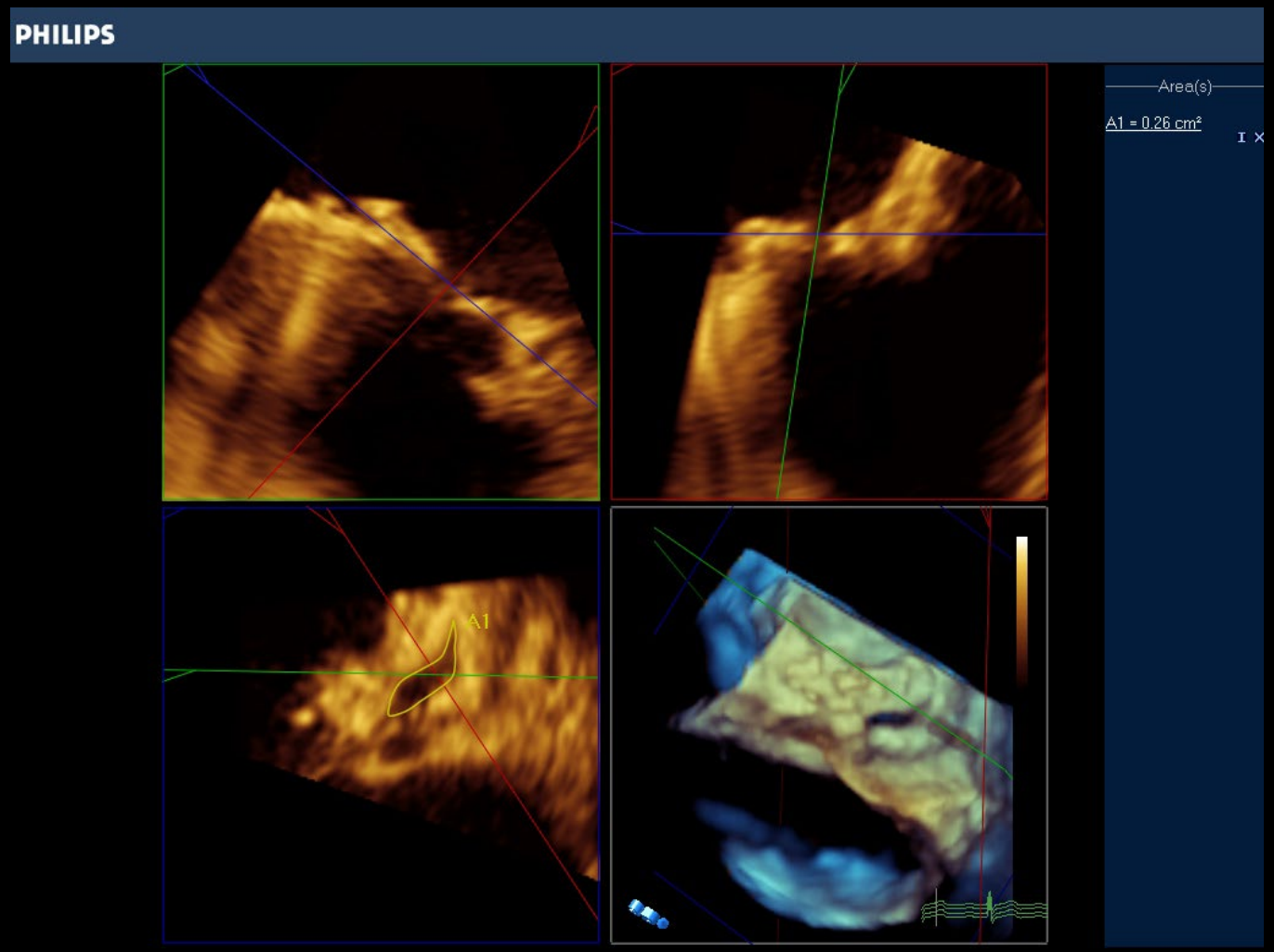

Hani Mahmoud-Elsayed, Echocardiography, 2020 Jun;37(6):954-964

Sizing & shape

MPR

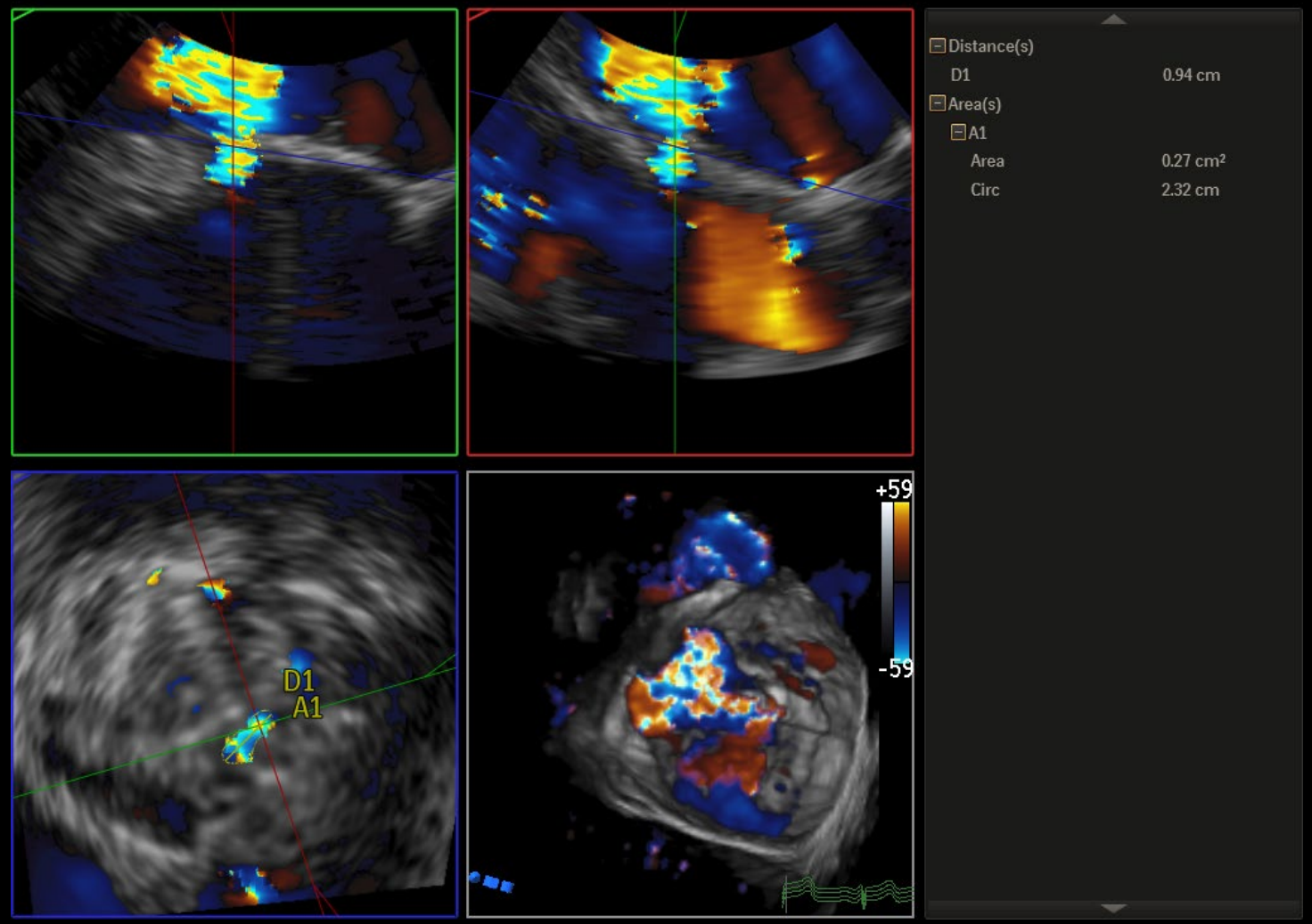

Hani Mahmoud-Elsayed, Echocardiography, 2020 Jun;37(6):954-964

Sizing & shape

Journal of the American Society of Echocardiography
Volume 27 Number 11

Table 5 Best cutoff values to identify degree III and IV paravalvular regurgitation of the PVL dimensions calculated with the 3D color ERO method and with 3D ARO

	Cutoff value	Sensitivity (%)	Specificity (%)	PPV (%)	NPV (%)
3D color ERO approach					
Area	≥0.13 cm^2	90.0	71.4	83.5	81.6
Length (major diameter)	≥0.65 cm	90.0	78.6	87.1	94.0
Width (minor diameter)	≥0.28 cm	75.0	71.4	80.9	63.9
3D planimetry without color images					
Area	≥0.15 cm^2	70.0	57.1	72.6	54.3
Length (major diameter)	≥0.84 cm	70.0	57.1	72.6	54.3
Width (minor diameter)	≥0.34 cm	75.0	50.0	70.7	55.4

NPV, Negative predictive value; *PPV*, positive predictive value.

Franco et al. J Am Soc Echocardiogr.2014.08.019

Sizing & shape

Table 8 Influence of PVL dimensions and location on the technical success of PVL closure procedures

Variable	PVLs with successful closure (n = 23)	PVLs with unsuccessful closure (n = 11)	P
3D color ERO approach			
Area (cm^2)	0.18 ± 0.10	0.20 ± 0.17	.466
Length (major diameter) (cm)	0.67 ± 0.25	0.73 ± 0.42	.854
Width (minor diameter) (cm)	0.32 ± 0.10	0.34 ± 0.19	.288
Eccentricity index	2.18 ± 0.68	2.42 ± 1.36	.454
3D planimetry without color images			
Area (cm^2)	0.20 ± 0.19	0.27 ± 0.27	.696
Length (major diameter) (cm)	1.06 ± 0.69	1.12 ± 0.72	.639
Width (minor diameter) (cm)	0.36 ± 0.14	0.41 ± 0.14	.701
Eccentricity index	3.19 ± 2.10	2.58 ± 1.31	.490
PVL location			
Anterior	5 (62.5%)	3 (37.5%)	.987
Septal	2 (66.7%)	1 (33.3%)	
Posterior	9 (69.2%)	4 (30.8%)	
Lateral	7 (70%)	3 (30%)	

Quantitative data are expressed as mean ± SD. PVL location is shown as number (percentage).

Franco et al. J Am Soc Echocardiogr.2014.08.019

Different shapes of PVLs

GIntroduction

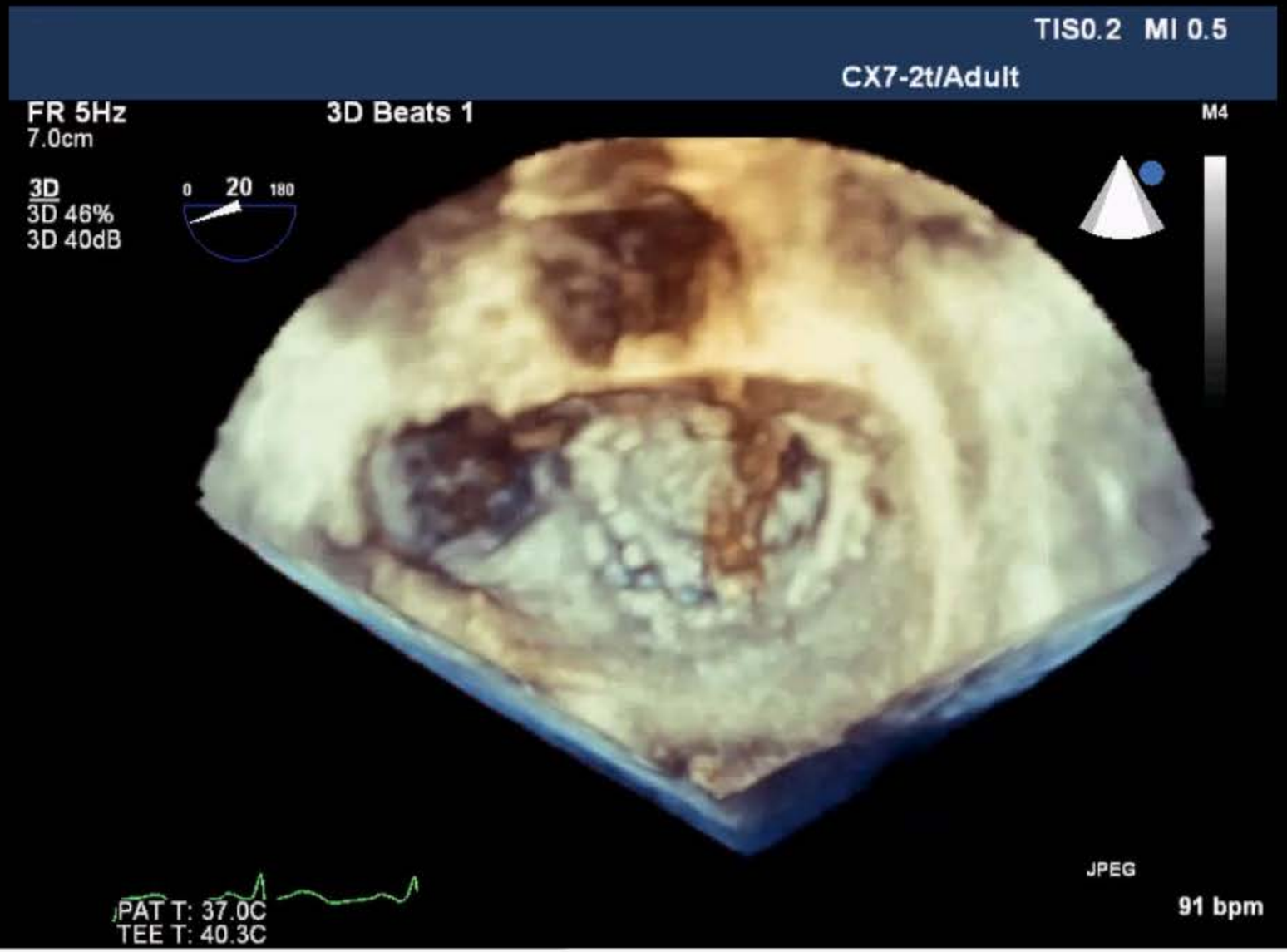

GIntroduction

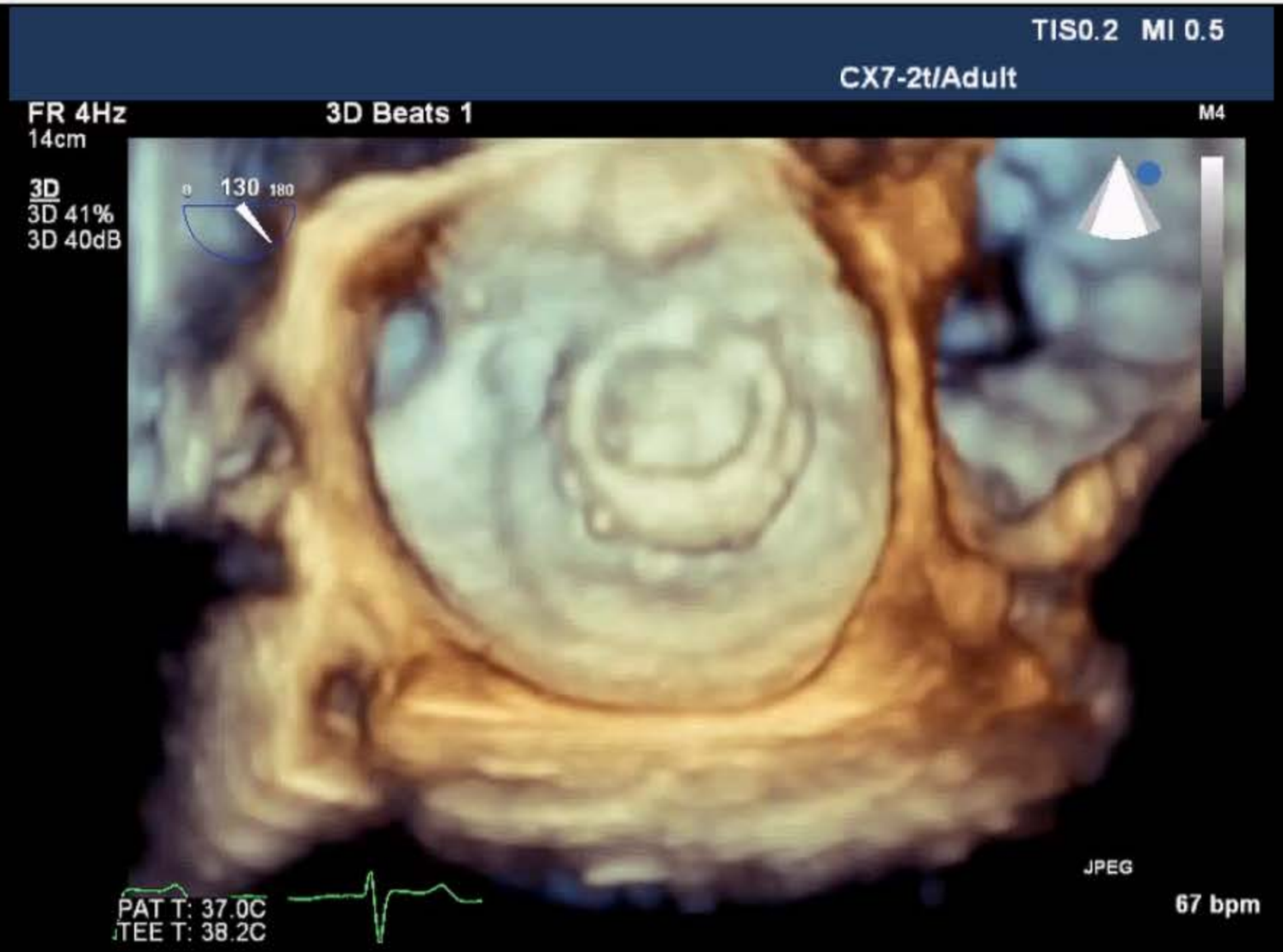

GIntroduction

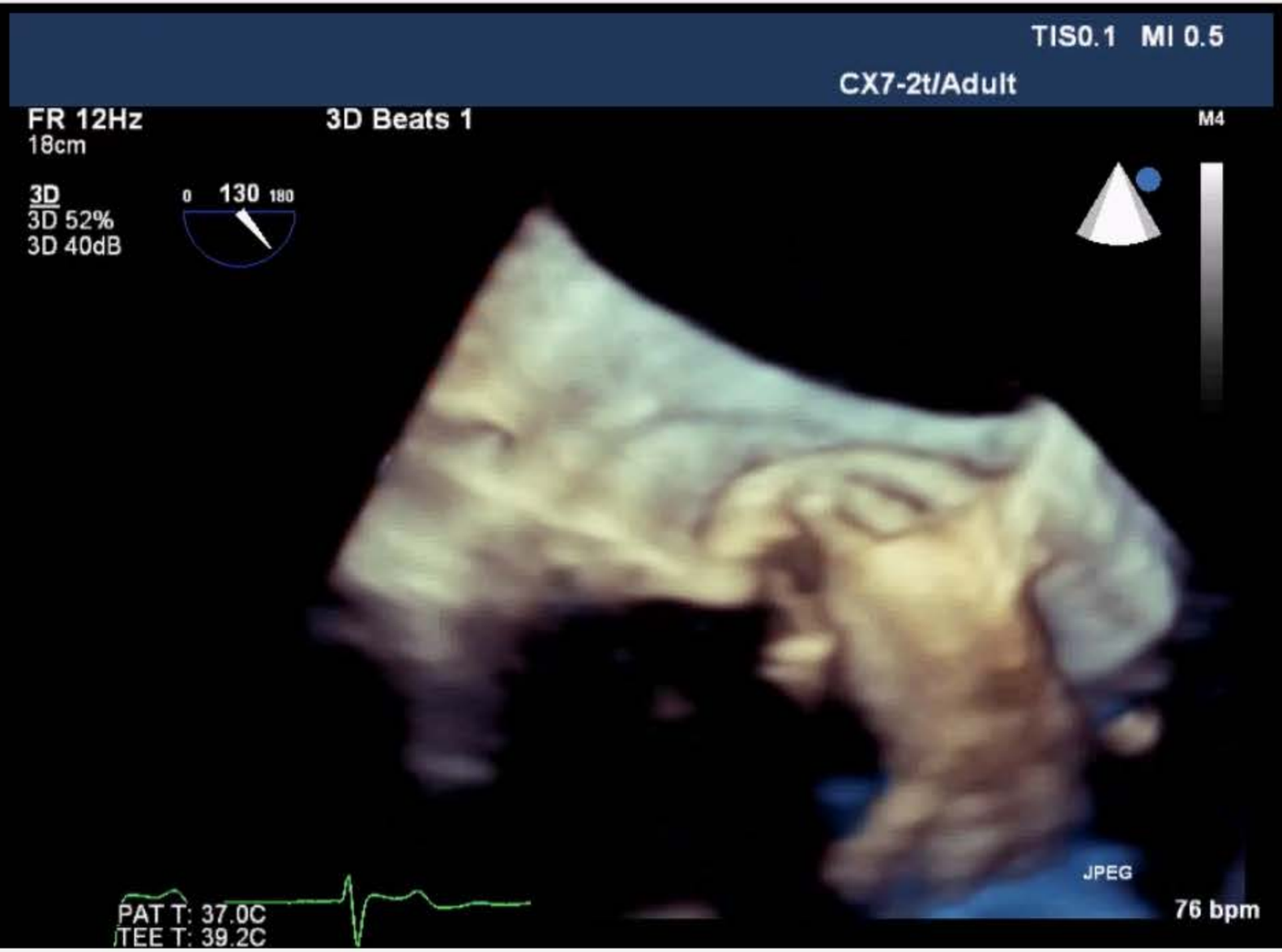

GIntroduction

Guiding percutaneous closure

Guiding percutaneous closure

- *Trans-septal puncture*
- *Wire & catheter positioning*
- *Device positioning*
- *Assessment of residual leak*

Approach selection

Trans-septal Vs Trans-apical:

- *Location of the leak*
- *Other prosthesis*
- *Septal condition*

Heart Team



Hani Mahmoud-Elsayed

Trans-septal puncture

Trans-septal puncture

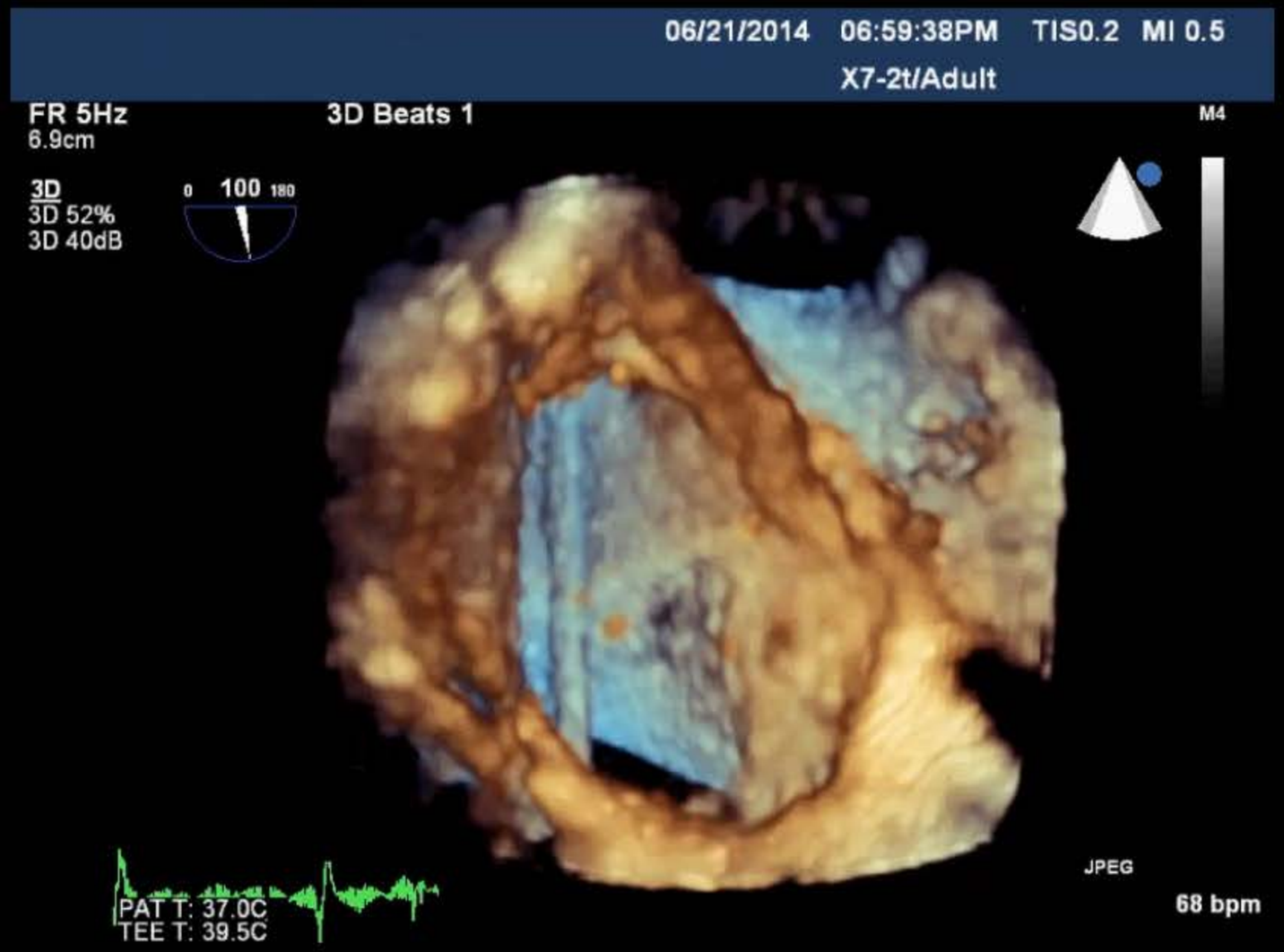

H. Mahmoud et al. Cardiol Res Pract, 2015. doi:10.1155/2015/174051

Trans-septal puncture

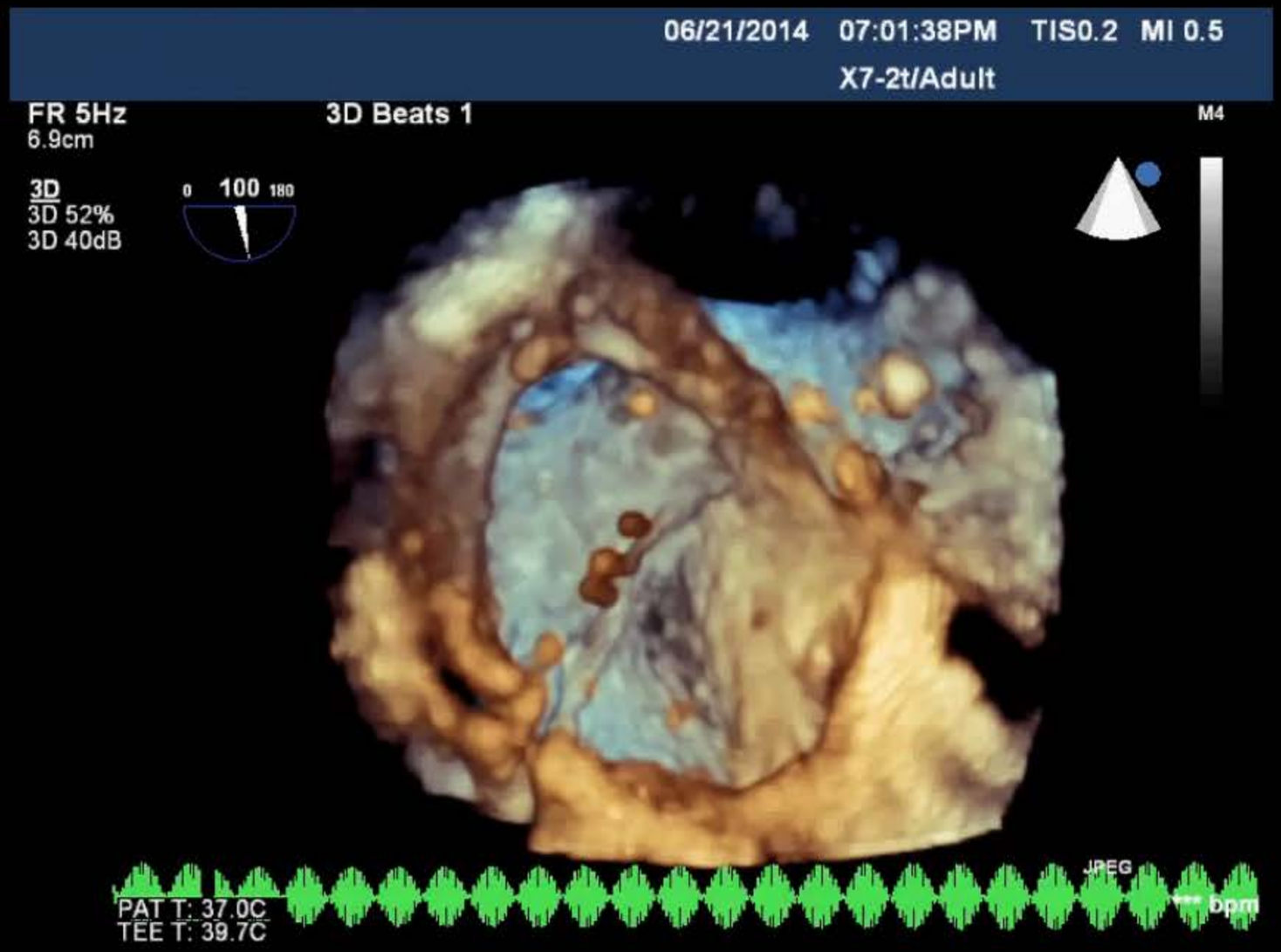

H. Mahmoud et al. Cardiol Res Pract, 2015. doi:10.1155/2015/174051

Trans-septal puncture

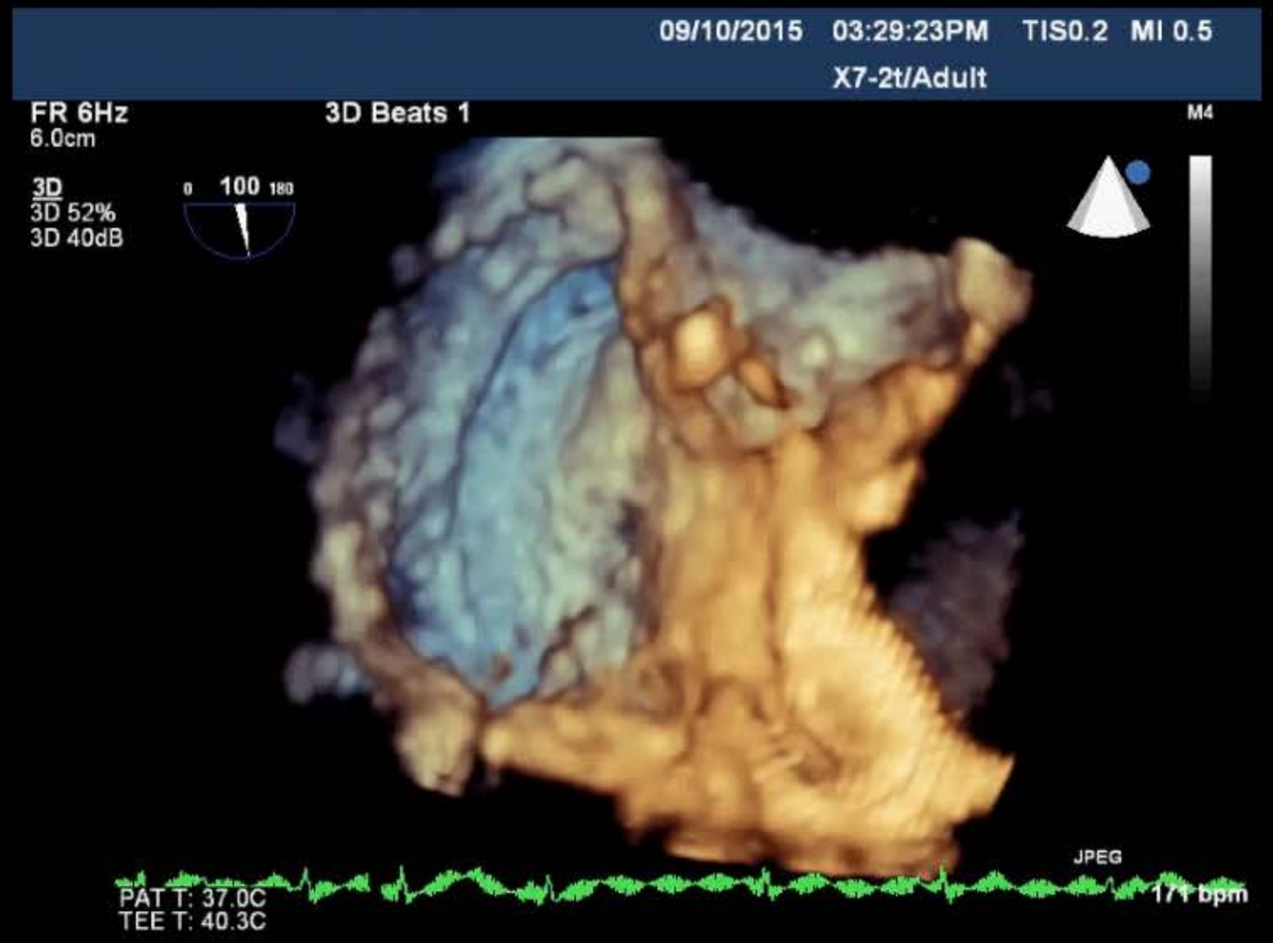

H. Mahmoud et al. Cardiol Res Pract, 2015. doi:10.1155/2015/174051

Trans-septal puncture

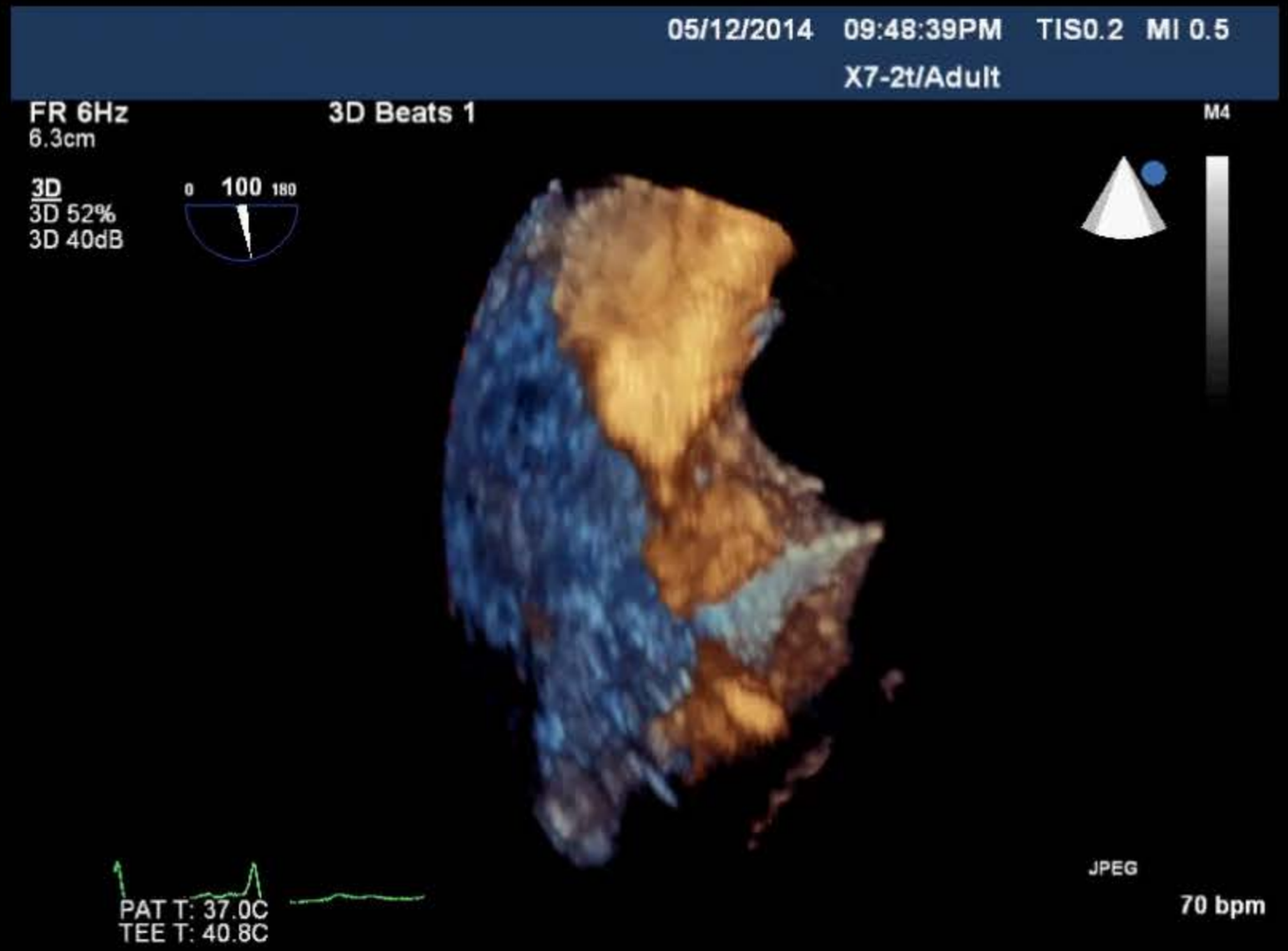

H. Mahmoud et al. Cardiol Res Pract, 2015. doi:10.1155/2015/174051

Trans-apical approach

Trans-apical approach

Hani Mahmoud-Elsayed, Echocardiography, 2020 Jun;37(6):954-964

Wire and catheter positioning

Wire and catheter positioning

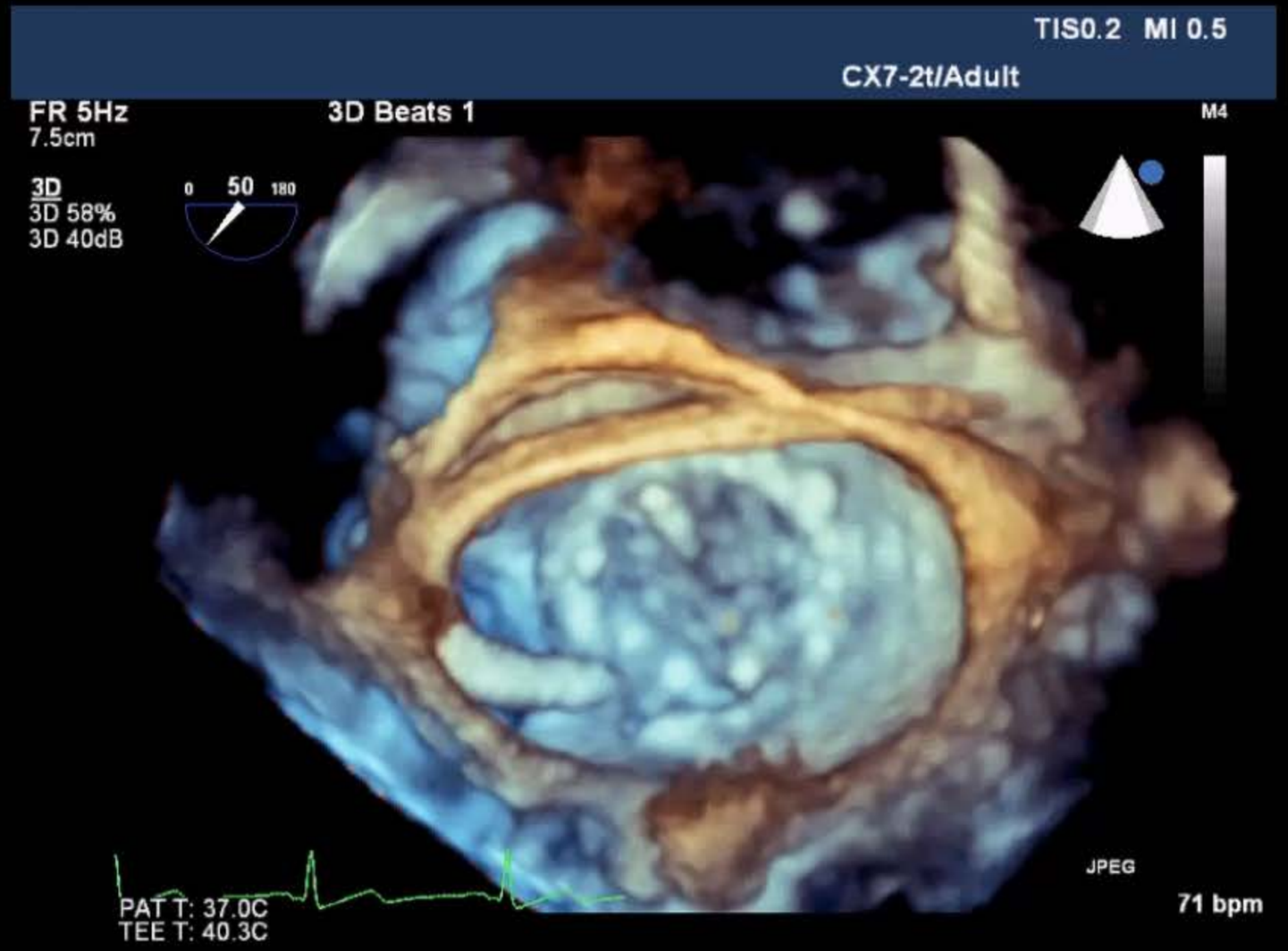

Hani Mahmoud-Elsayed, Echocardiography, 2020 Jun;37(6):954-964

Wire and catheter positioning

Hani Mahmoud-Elsayed, Echocardiography, 2020 Jun;37(6):954-964

Wire and catheter positioning

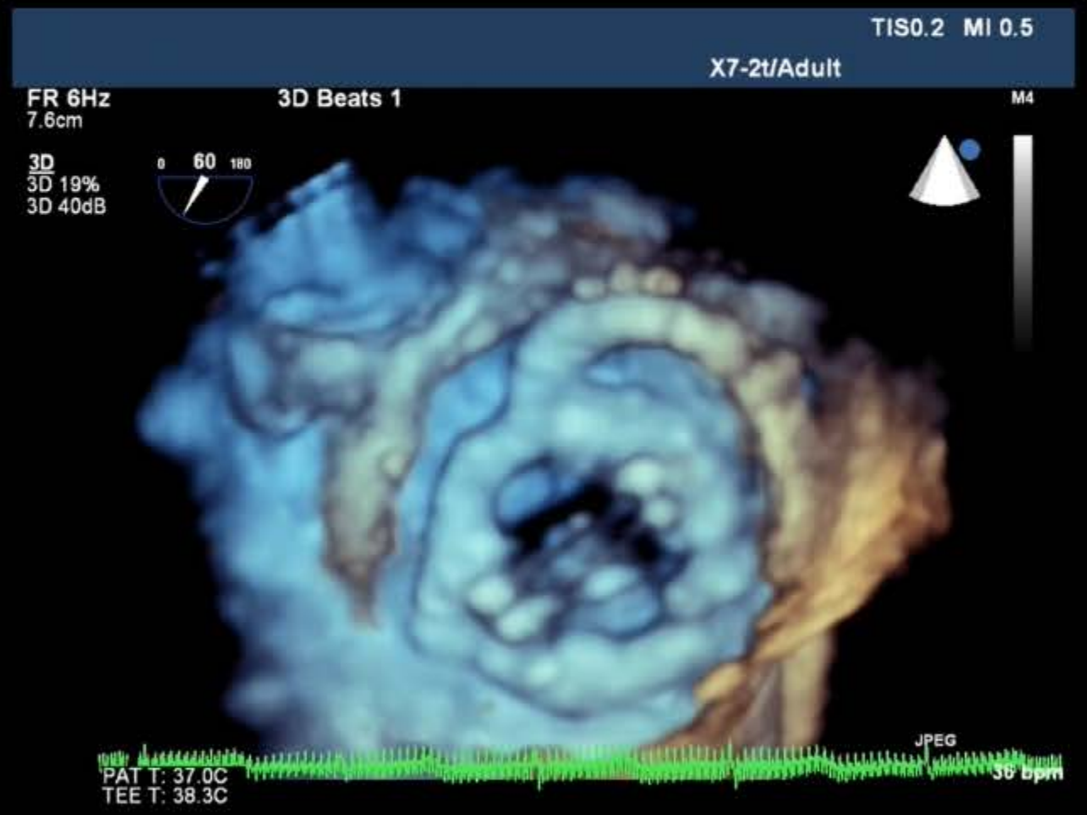

Hani Mahmoud-Elsayed, Echocardiography, 2020 Jun;37(6):954-964

Wire and catheter positioning

Hani Mahmoud-Elsayed, Echocardiography, 2020 Jun;37(6):954-964

Wire and catheter positioning

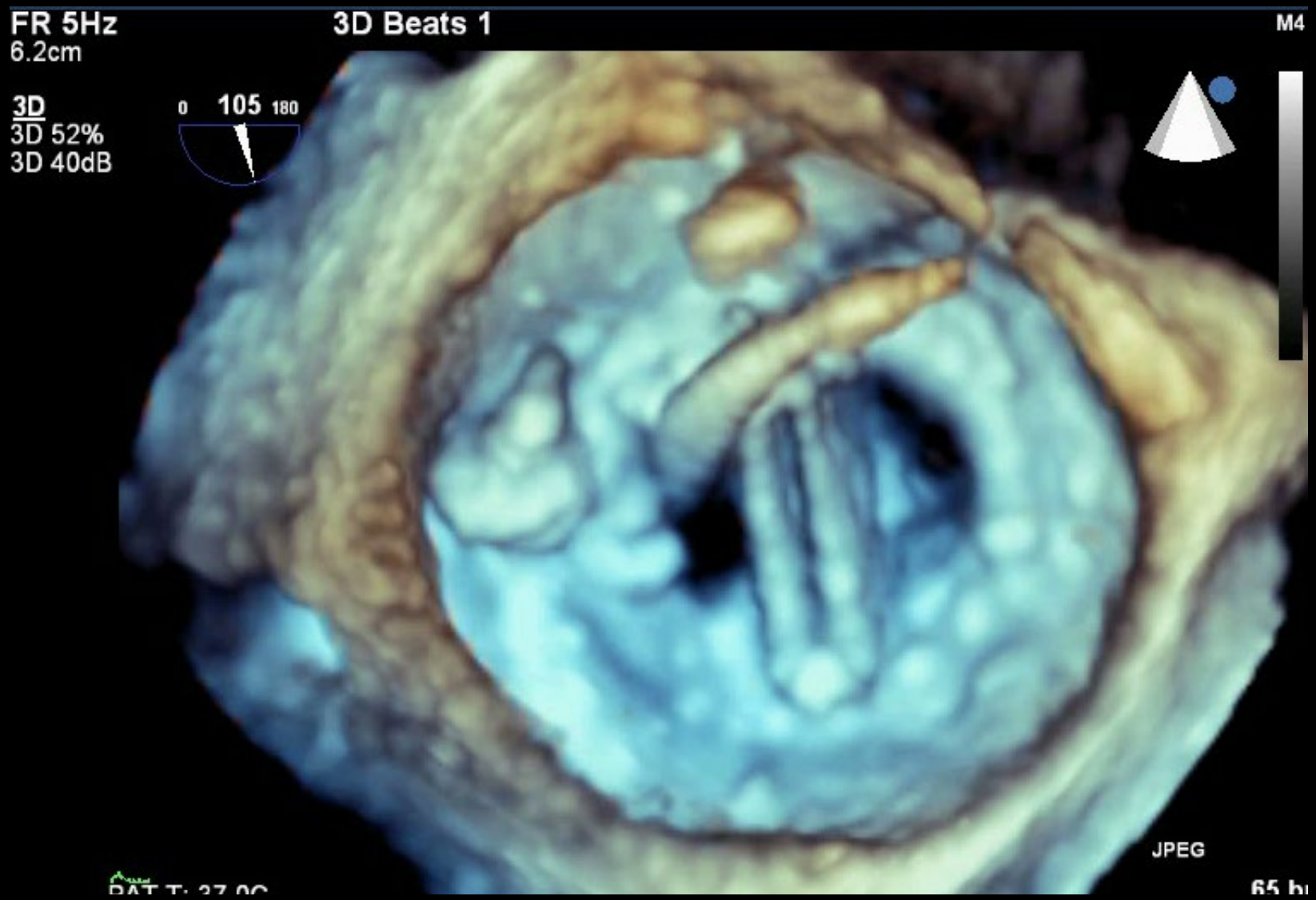

Hani Mahmoud-Elsayed, Echocardiography, 2020 Jun;37(6):954-964

Wire and catheter positioning

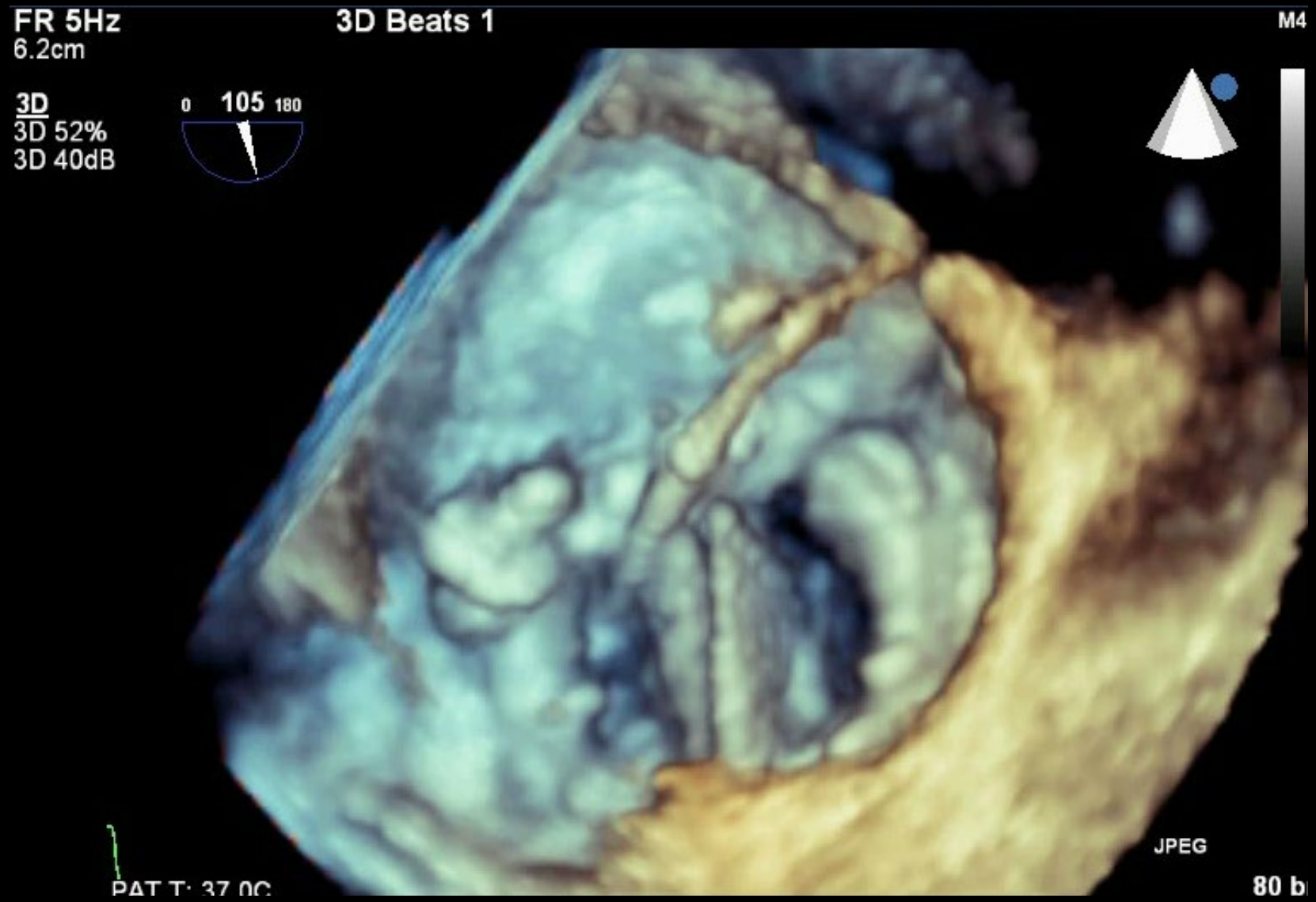

Hani Mahmoud-Elsayed, Echocardiography, 2020 Jun;37(6):954-964

Wire and catheter positioning

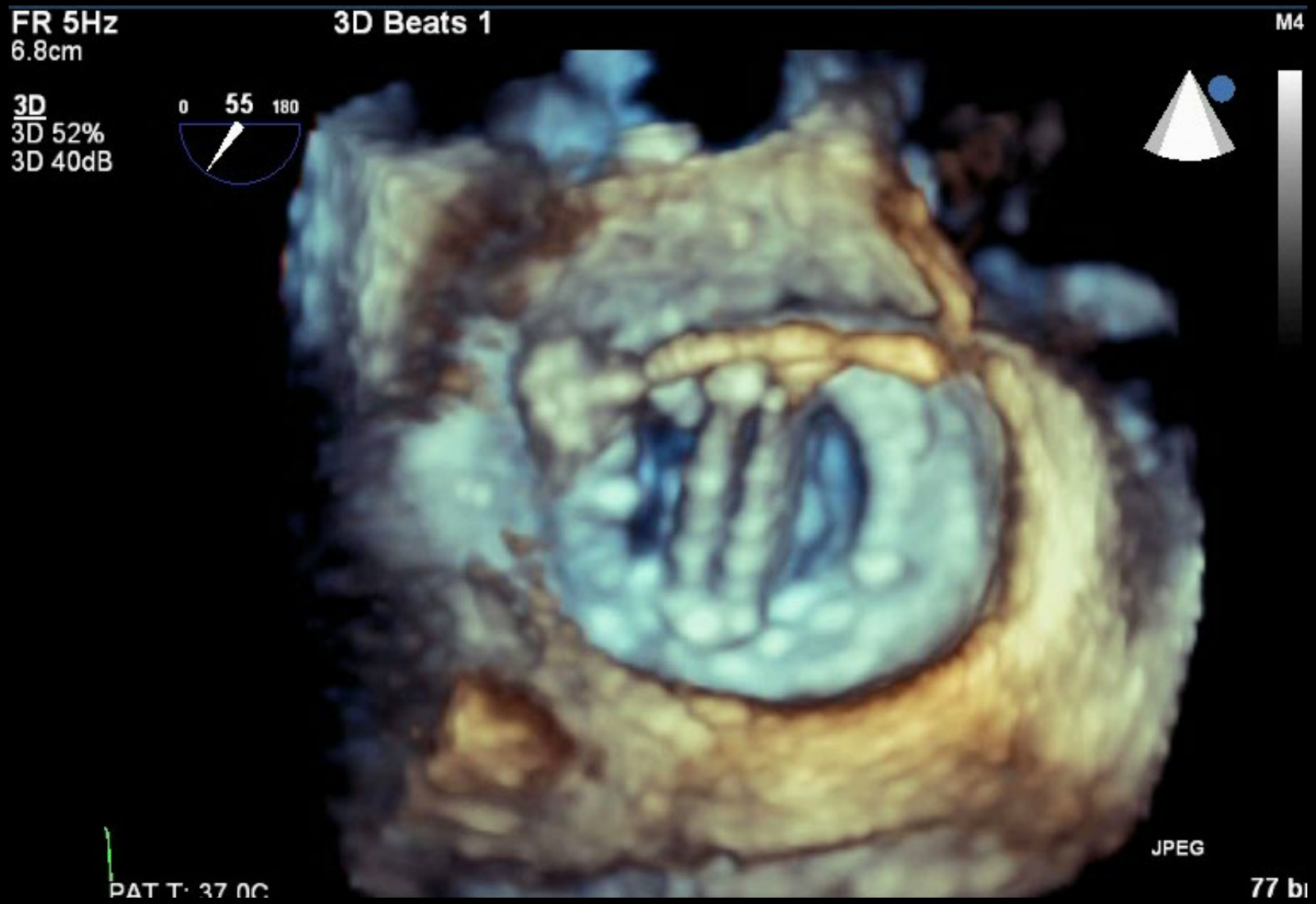

Hani Mahmoud-Elsayed, Echocardiography, 2020 Jun;37(6):954-964

Device positioning

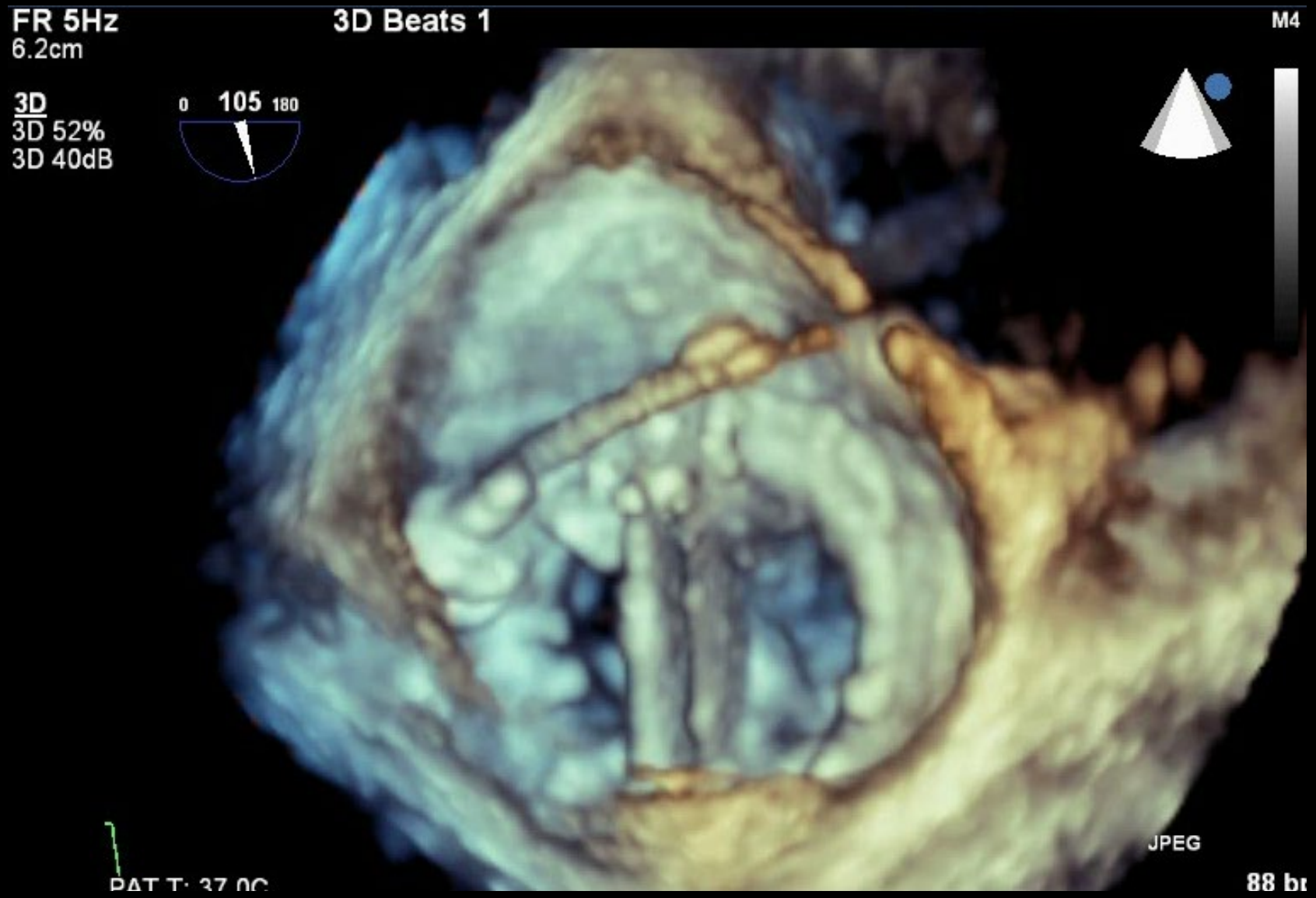

Hani Mahmoud-Elsayed, Echocardiography, 2020 Jun;37(6):954-964

Device positioning

Hani Mahmoud-Elsayed, Echocardiography, 2020 Jun;37(6):954-964

Device positioning

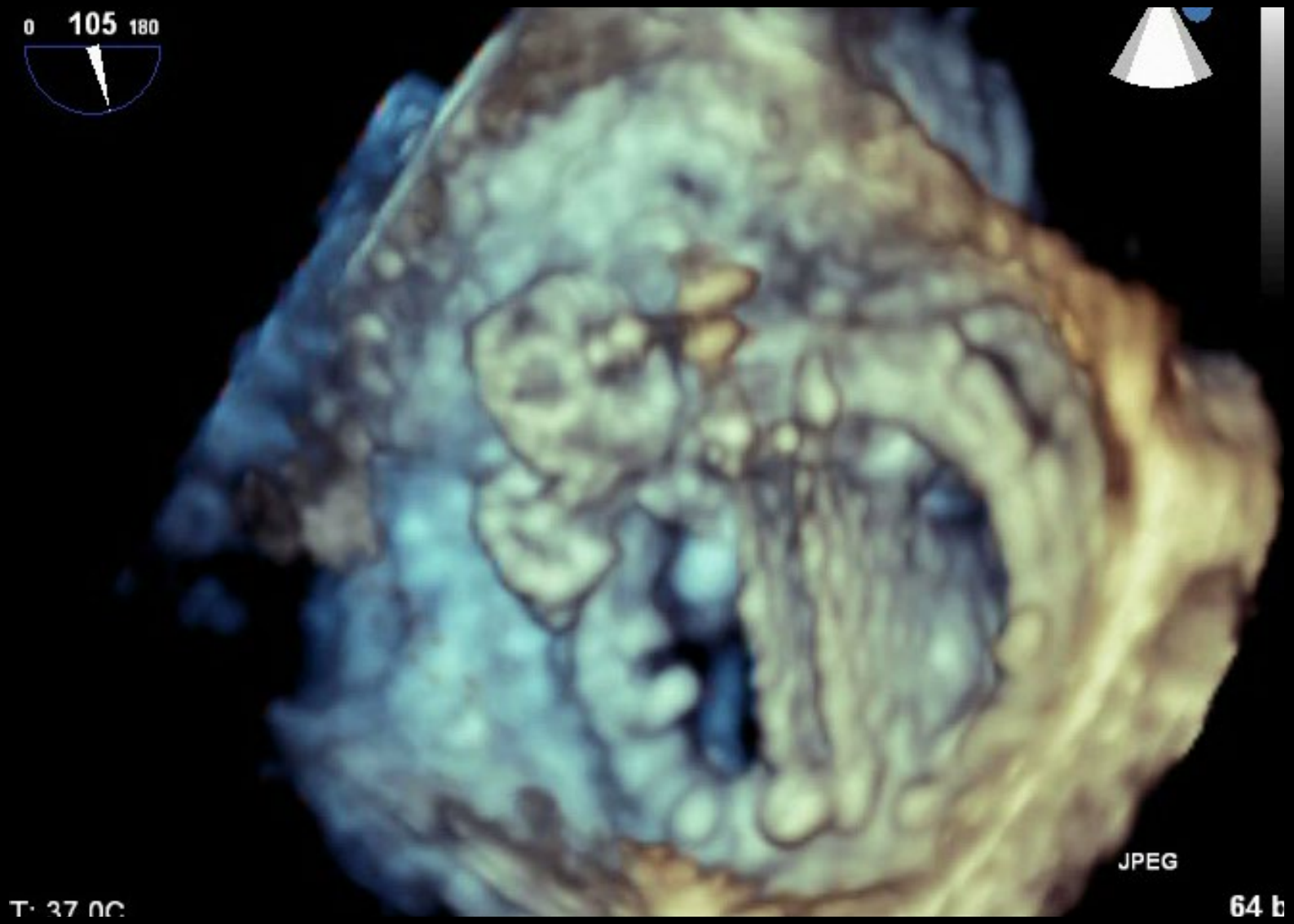

Hani Mahmoud-Elsayed, Echocardiography, 2020 Jun;37(6):954-964

Assessment of the result

Assessment of the result

- *Prosthetic malfunction & leaflet mobility*
- *Residual leak*

Assessment of the result

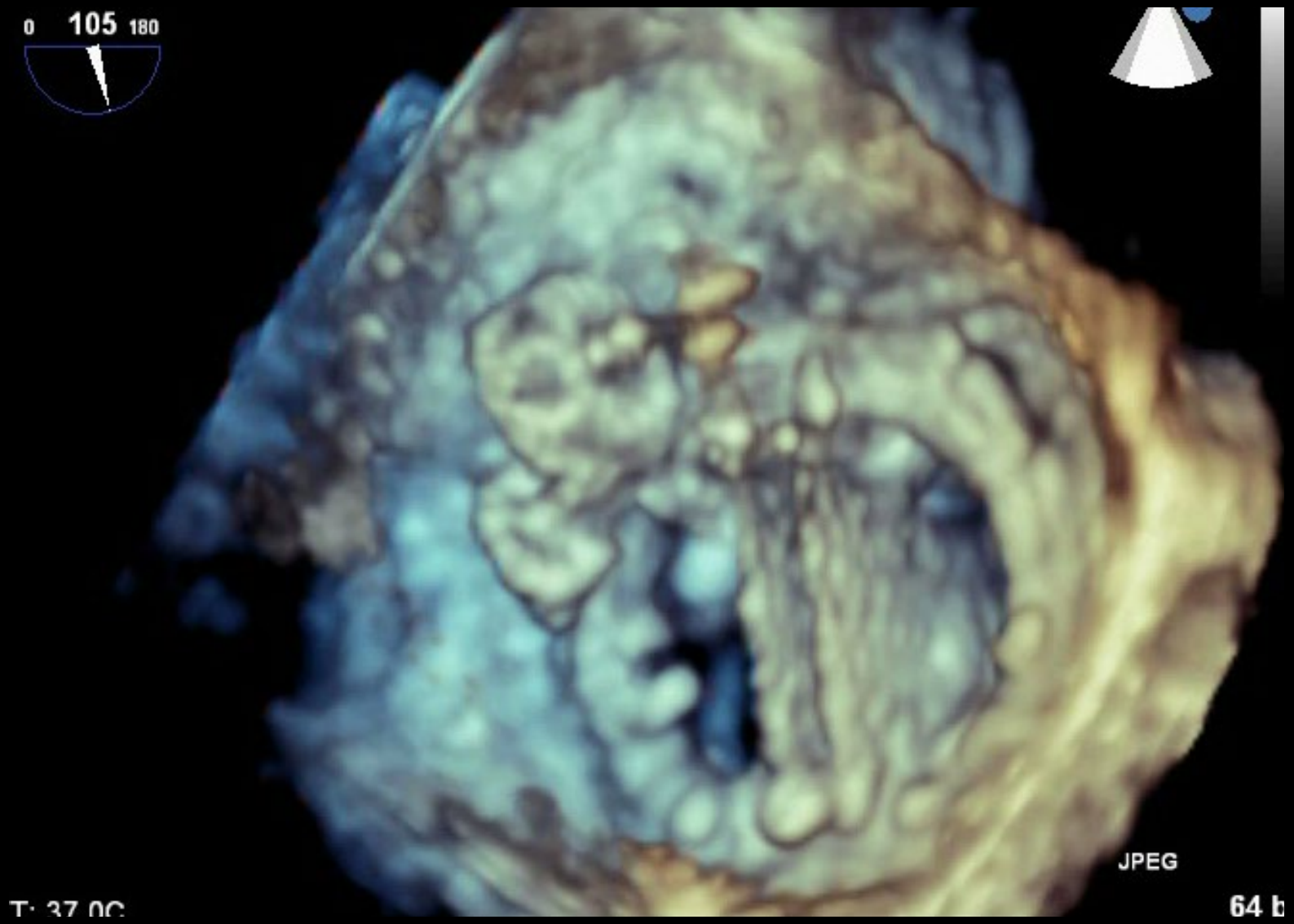

Assessment of the result

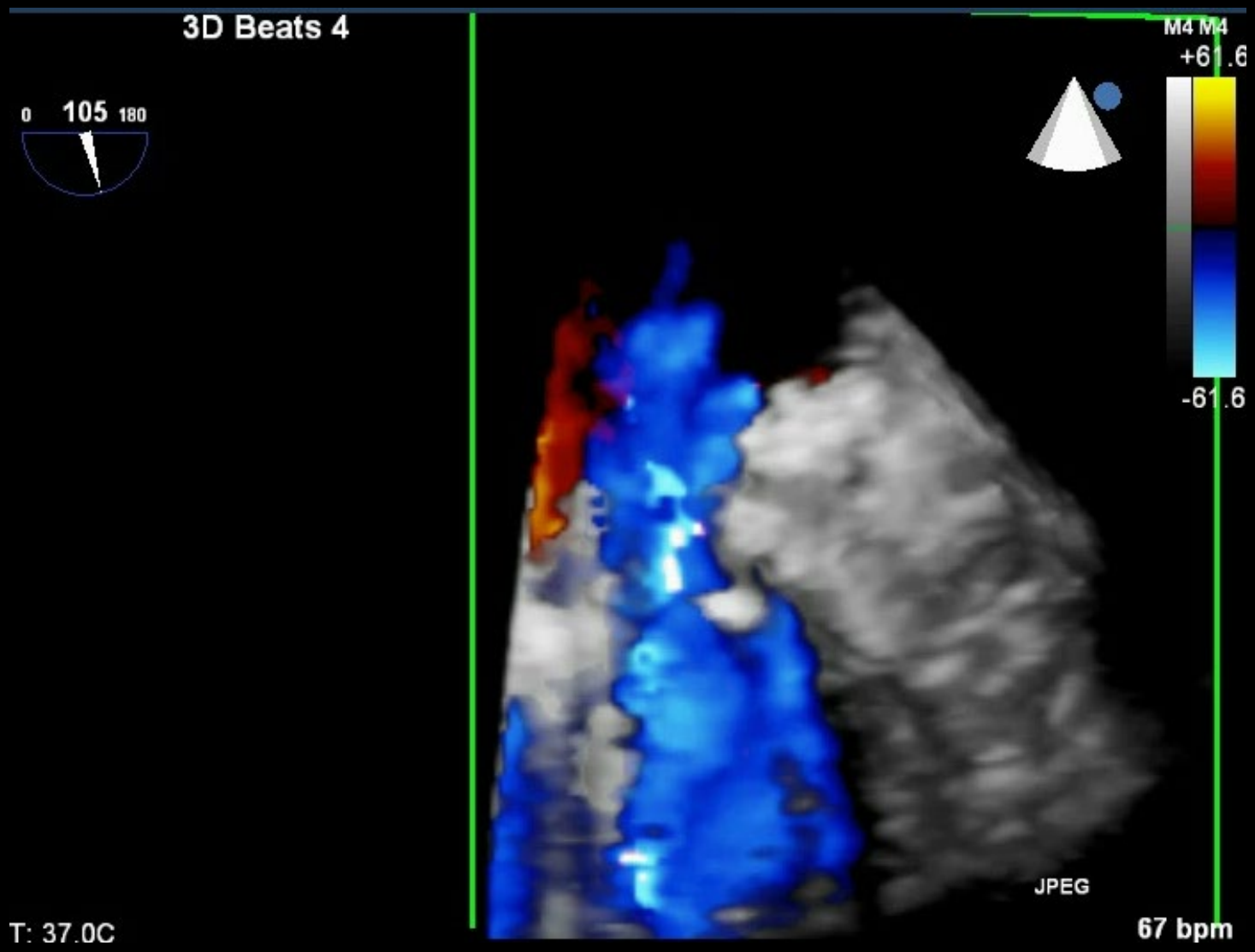

Conclusion

Conclusion

Percutaneous closure of PVLs is a very 2D/3D-TEE dependent procedure

Added values of 3DTEE:

- *Better localization of the leak*
- *Better definition of the size and shape*

Guiding percutaneous closure:

- *Trans-septal puncture*
- *Wire & catheter positioning*
- *Device positioning*
- *Assessment of residual leak*

Echocardiography
A Journal of Cardiovascular Ultrasound and Allied Techniques

REVIEWS

Added value of three-dimensional transesophageal echocardiography in management of mitral paravalvular leaks

Hani Mahmoud-Elsayed MBBCh, MSc, MD, FESC, FASE

Version of Record online: 25 May 2020

https://doi.org/10.1111/echo.14708

Abstract | Full text | PDF | References | Request permissions

CIC

مركز فحوصات القلب

CARDIAC INVESTIGATION CENTER

www.ciceg.net