2D/3D-TOE role during MitraClip procedure

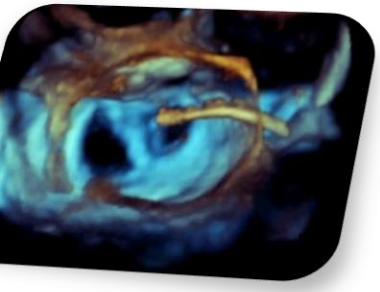

Dr. Hani Mahmoud-Elsayed

MBBCh, MSc, MD, FESC, FASE, FEACVI

Consultant cardiologist, Director of Echocardiography Lab
Aswan Heart Centre, Magdi Yacoub Foundation, Egypt

مركز فحوصات القلب
CARDIAC INVESTIGATION CENTER

Disclosure

- ***All members of the Faculty have provided a declaration of potential or actual conflict of interest''***

- **Percutaneous valvular interventions have become important alternative therapies for patients with high surgical risk.**

- **MitraClip percutaneous edge-to-edge repair had been proven to be feasible and effective in patients with severe/moderately severe symptomatic mitral regurgitation who have high surgical risk.**

Degenerative MR

DMR Flail Gap

This should be taken in the view (LAX, 4C, 5C) where the flail gap is largest.

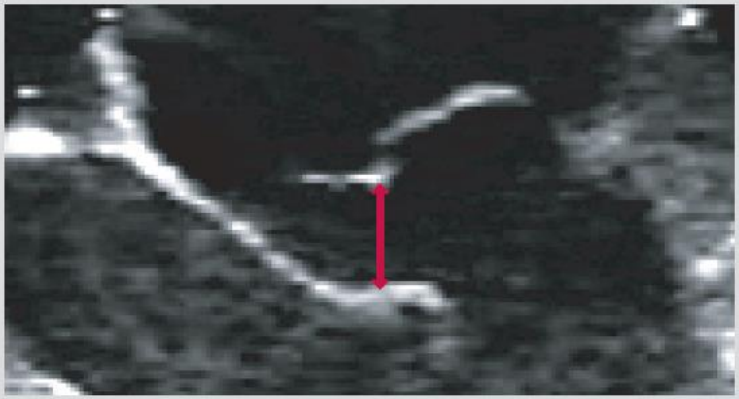

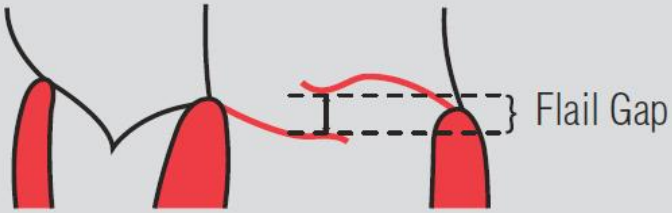

DMR Flail Width

This measurement should be taken in the transgastric short axis view where the flail width is largest.

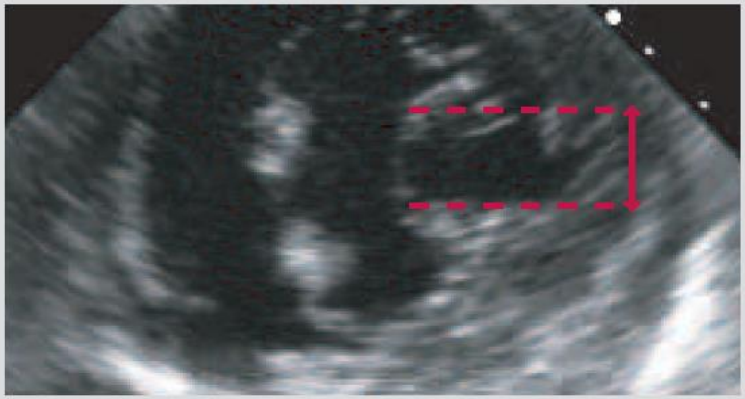

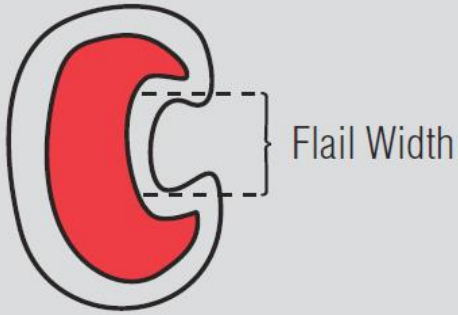

Feldman T.et al J Am Coll Cardiol. 2009 Aug 18;54(8):686-94

Functional MR

FMR Coaptation Depth

The measurement should be taken in the 4C view where the coaptation depth is greatest.

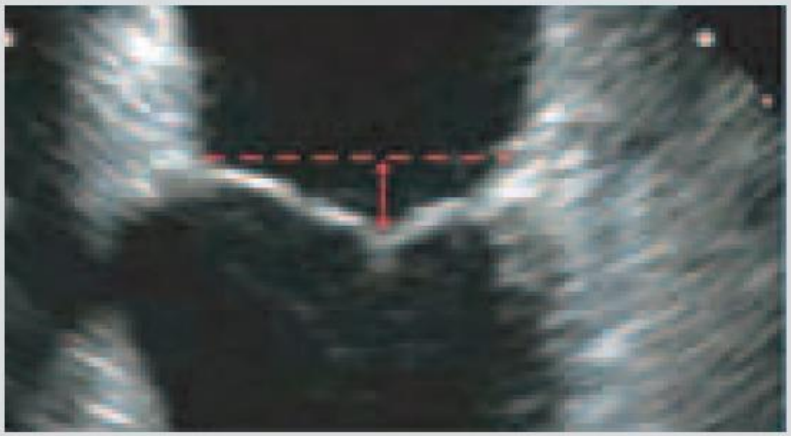

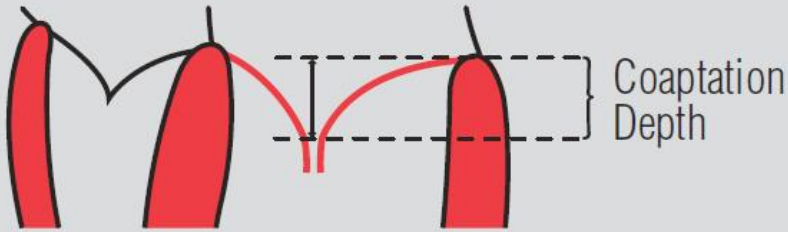

FMR Coaptation Length

The measurement should be taken in the 4C view where the coaptation length is shortest.

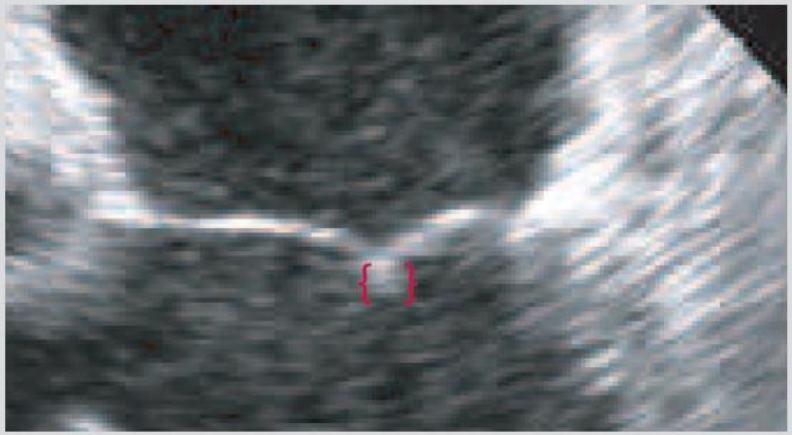

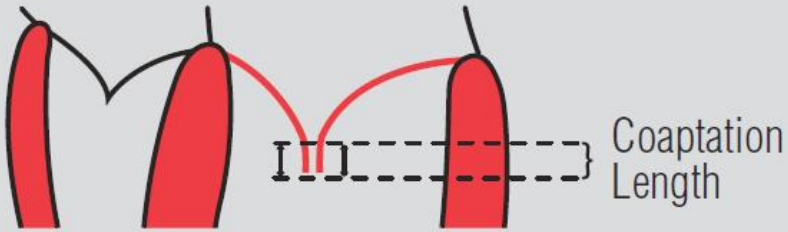

Feldman T.et al J Am Coll Cardiol. 2009 Aug 18;54(8):686-94

Morphology for a Mitraclip therapy

Clin Res Cardiol (2014) 103:85–96

Optimal valve morphology	Conditionally suitable valve morphology	Unsuitable valve morphology
Central pathology in Segment 2	Pathology in Segment 1 oder 3	Perforated mitral valve leaflet or cleft
No leaflet calcification	Mild calcification outside of the grip-zone of the clip system; ring calcification, post annuloplasty	Severe calcification in the grip-zone
Mitral valve opening area >4 cm^2	Mitral valve opening area >3 cm^2 with good residual mobility	Haemodynamically significant mitral stenosis (valve opening area <3 cm^2, MPG $\geq$ 5 mmHg)
Mobile length of the posterior leaflet $\geq$10 mm	Mobile length of the posterior leaflet 7–<10 mm	Mobile length of the posterior leaflet <7 mm
Coaption depth <11 mm	Coaption depth $\geq$11 mm	
Normal leaflet strength and mobility	Leaflet restriction in systole (Carpentier IIIB)	Rheumatic leaflet thickening and restriction in systole and diastole(Carpentier IIIA)
Flail-width <15 mmFlail-Gap <10 mm	Flail-width >15 mm only with a large ring width and the option for multiple clips	Barlow's syndrome with multisegment flail leaflets

Boekstegers P. et al Clin Res Cardiol. 2014 Feb;103(2):85-96.

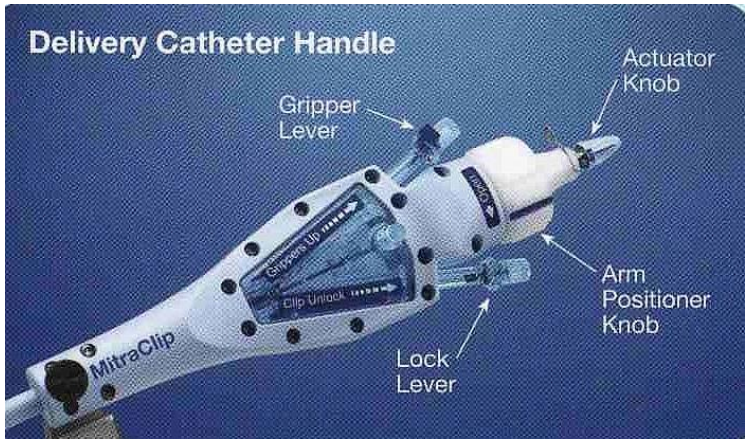
Delivery Catheter Handle
Actuator Knob
Gripper Lever
Arm Positioner Knob
Lock Lever
MitraClip

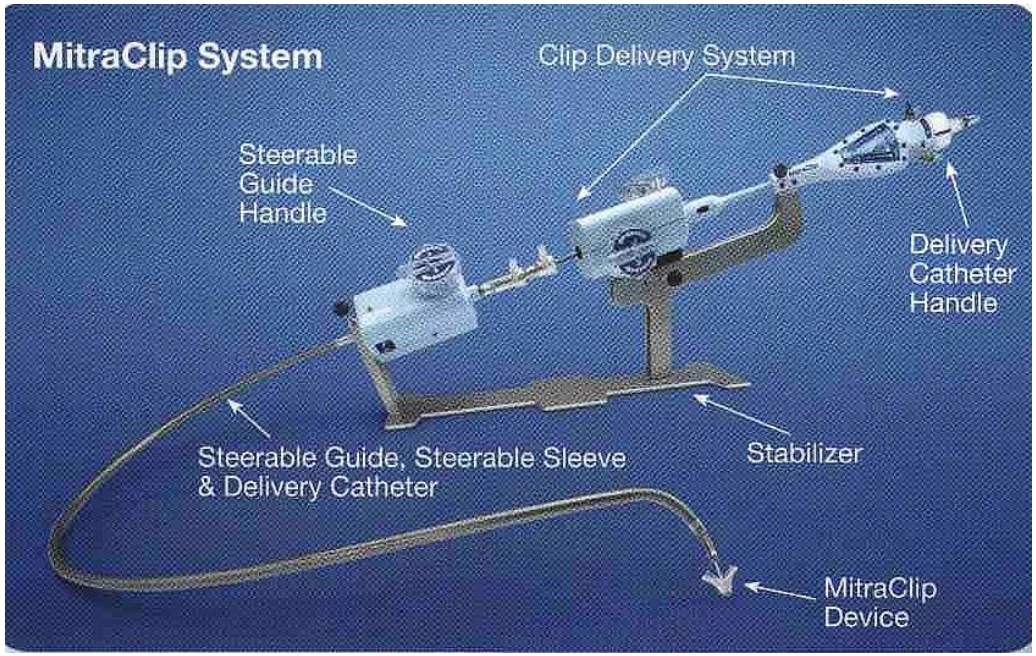
MitraClip System
Clip Delivery System
Steerable Guide Handle
Delivery Catheter Handle
Steerable Guide, Steerable Sleeve & Delivery Catheter
Stabilizer
MitraClip Device

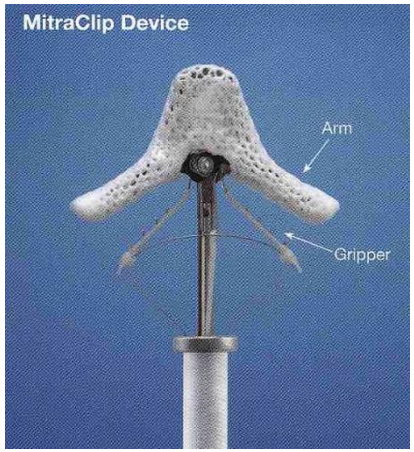
MitraClip Device
Arm
Gripper

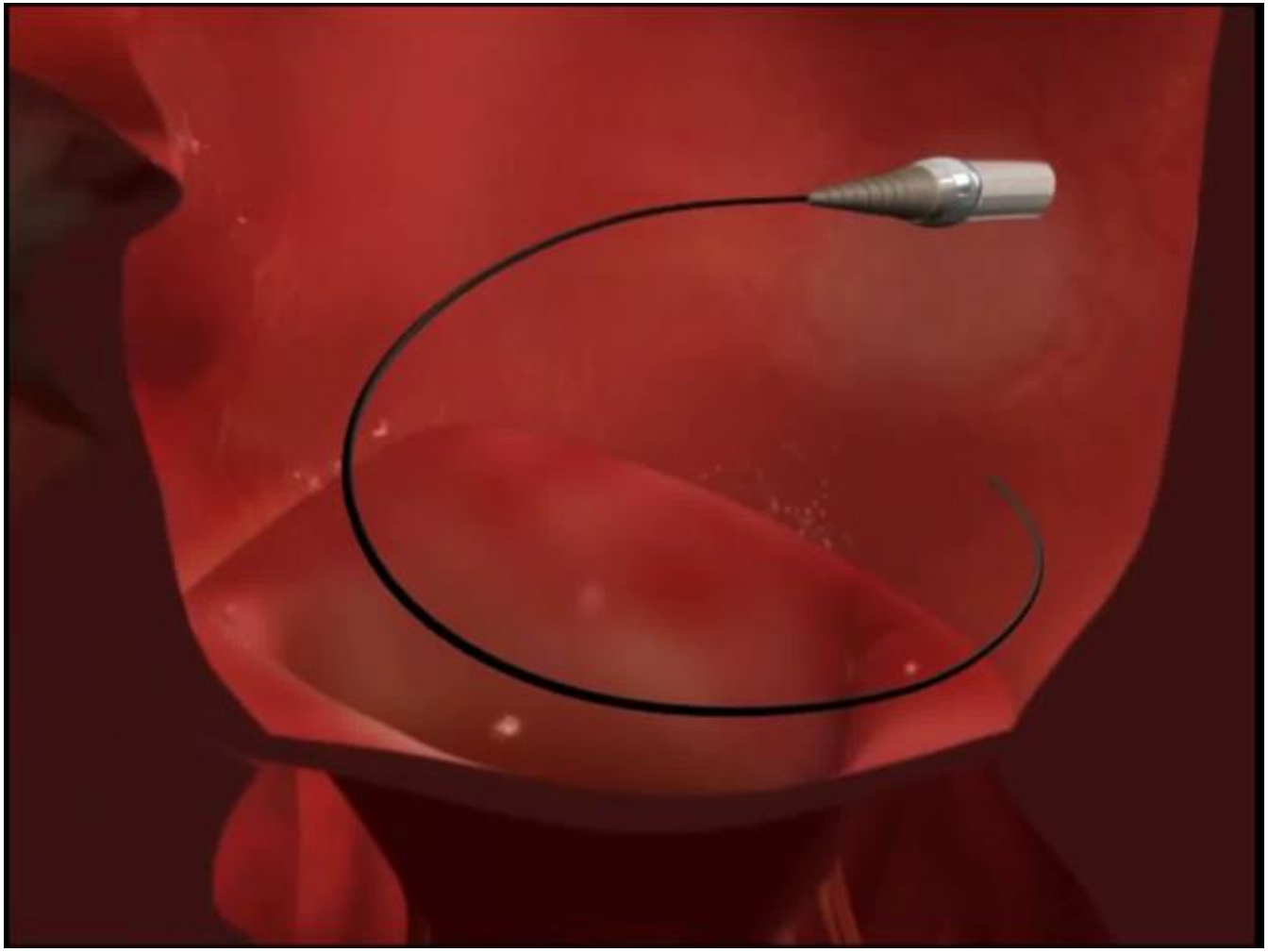

Before TSP

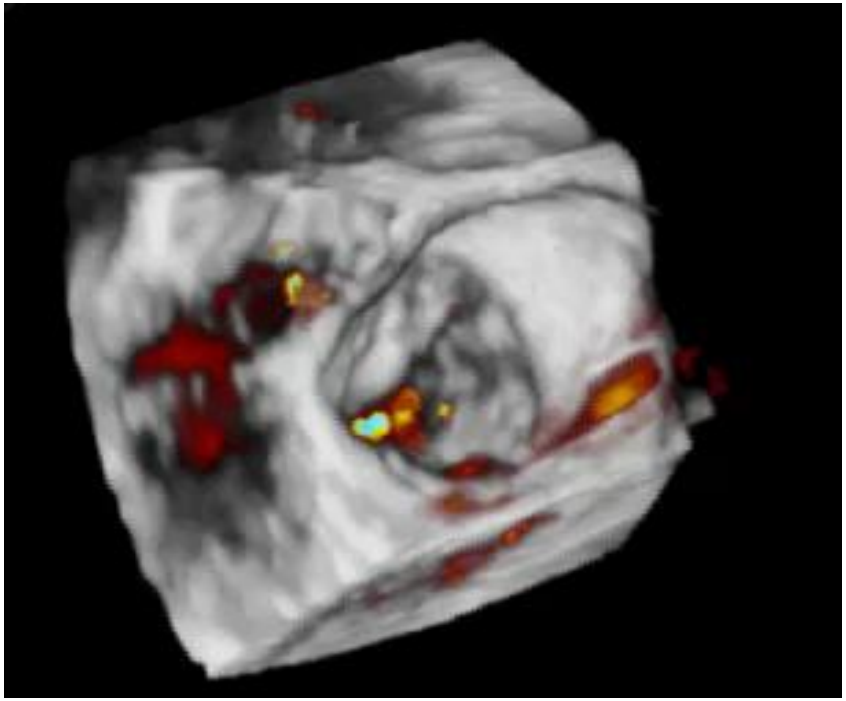

- **Assessment of mitral valve anatomy & mechanism of the mitral regurgitation.**

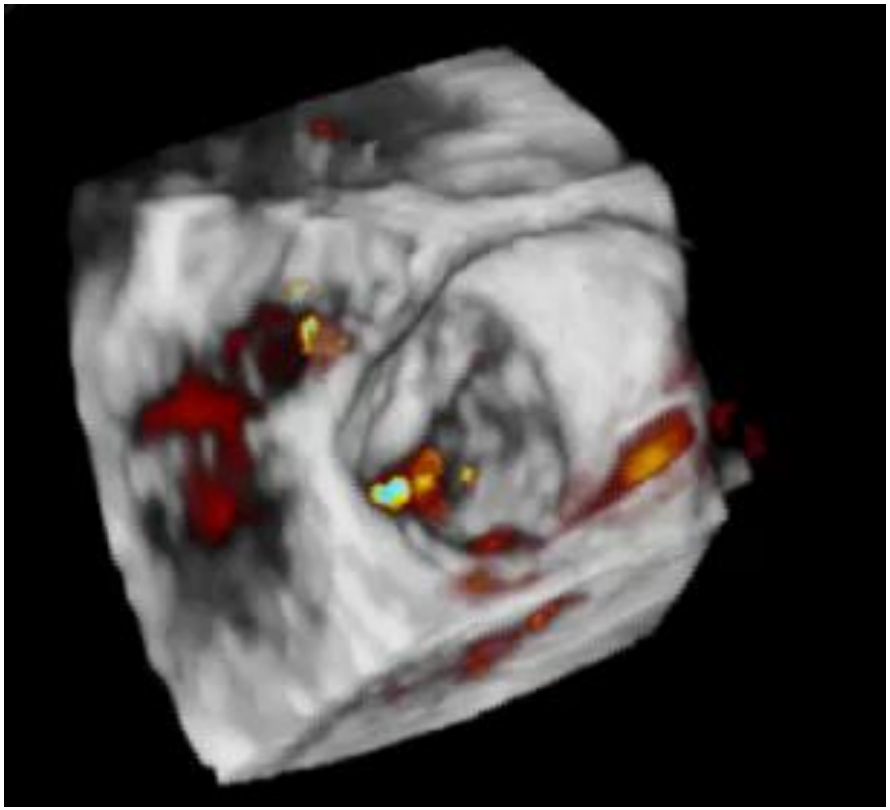

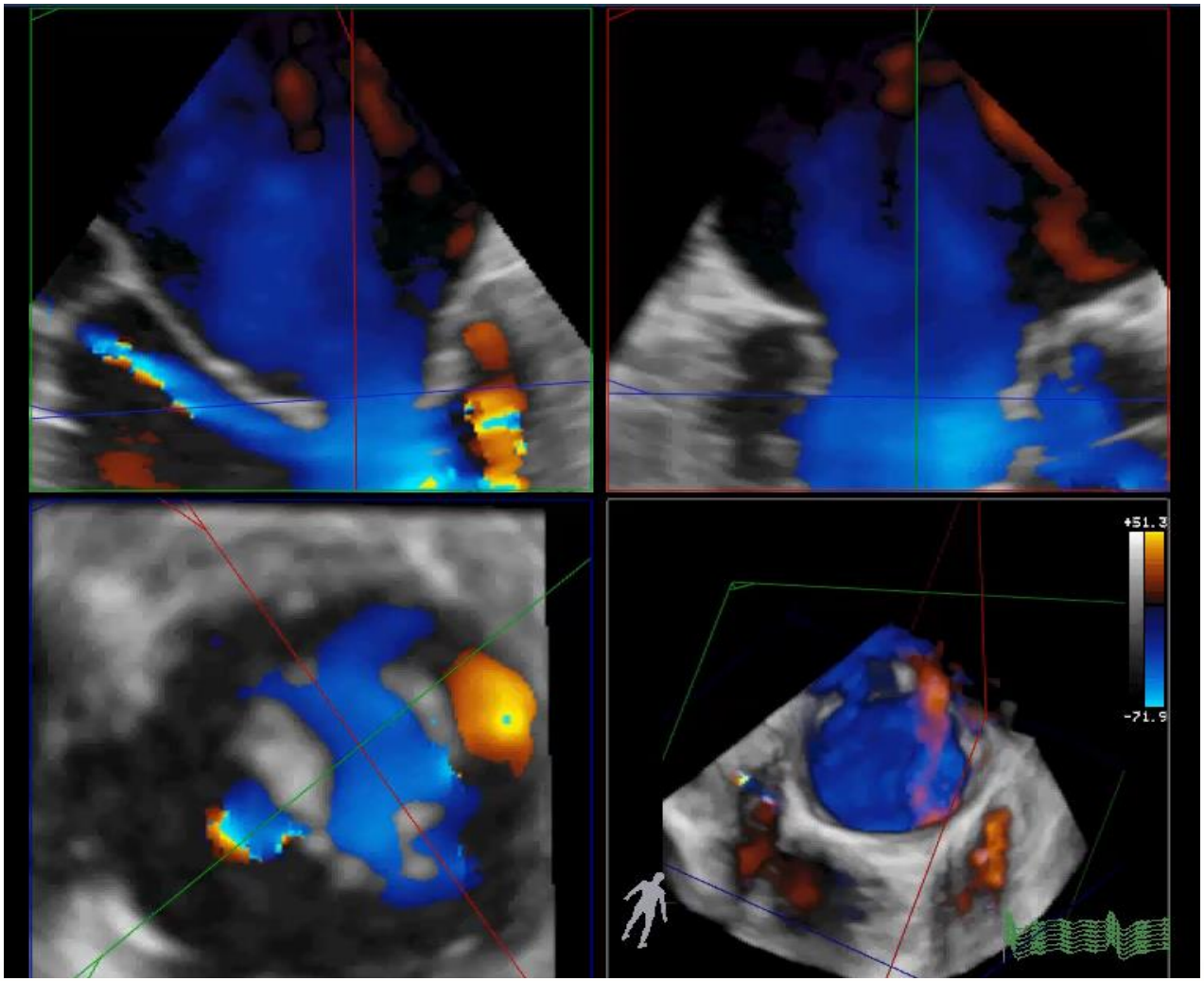
+51.3
-71.9

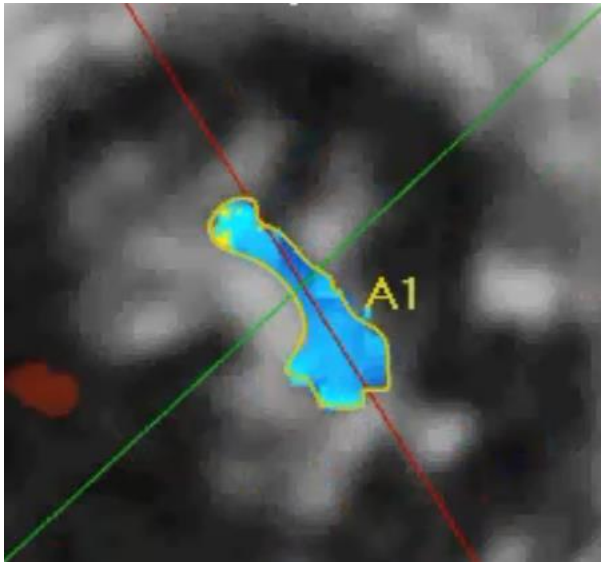
A1

The Egyptian Heart Journal (2017) 69, 247–251

HOSTED BY

ELSEVIER

Egyptian Society of Cardiology

The Egyptian Heart Journal

www.elsevier.com/locate/ehj
www.sciencedirect.com

CrossMark

ORIGINAL ARTICLE

The value of three-dimensional color Doppler trans-esophageal echocardiography in predicting the number of MitraClip devices needed during the procedure

Hani M. Mahmoud [a,*], Ali M. Al-Ameen [b], Mohamed H. Hassan [b], Tarek Badr [c], Hesham Nieem [d], Ahmed A. Shaheen [e], Abdullah E. Ghabashi [f]

Assessment of the regurgitant orifice area (ROA) using color 3D-TEE driven 3D-VCA and 3D-VCL is feasible. It can help predicting the number of MitraClip devices to be required during the procedure.

A cutoff values of 0.20 cm2 and 1 cm for the VCA and VCL respectively, are suggestive that the patient will most likely require more than one MitraClip device to treat his mitral regurgitation.

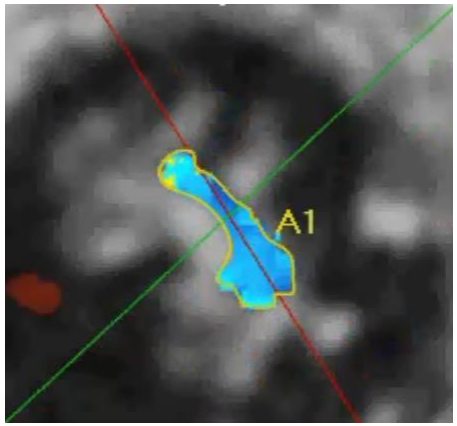

HM. Mahmoud et al. doi.org/10.1016/j.ehj.2017.03.004

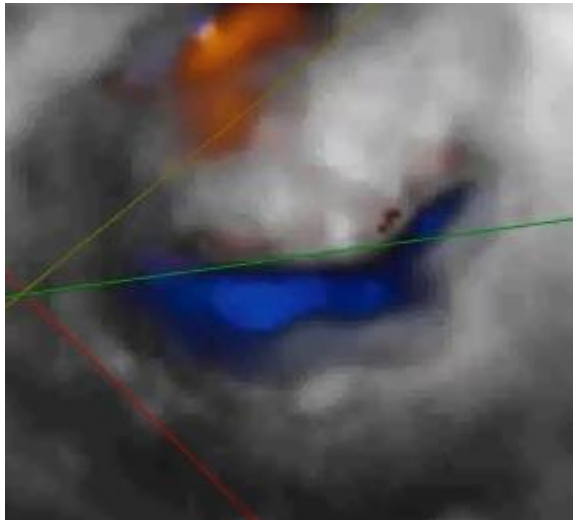

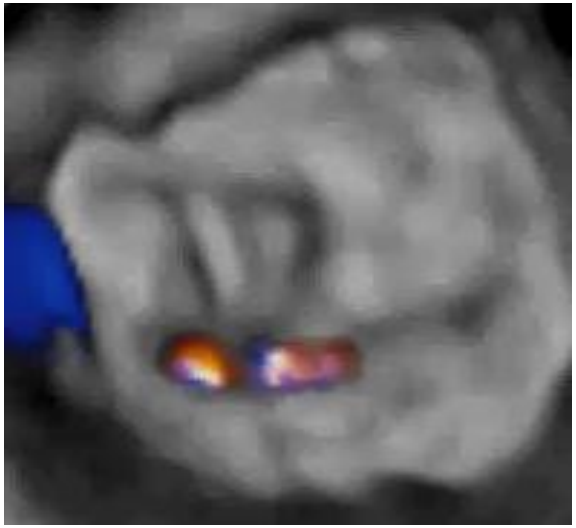

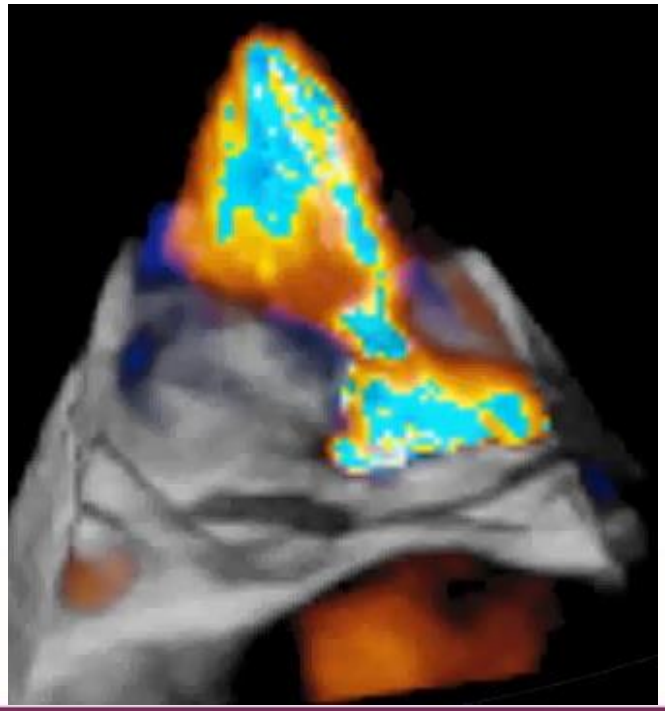

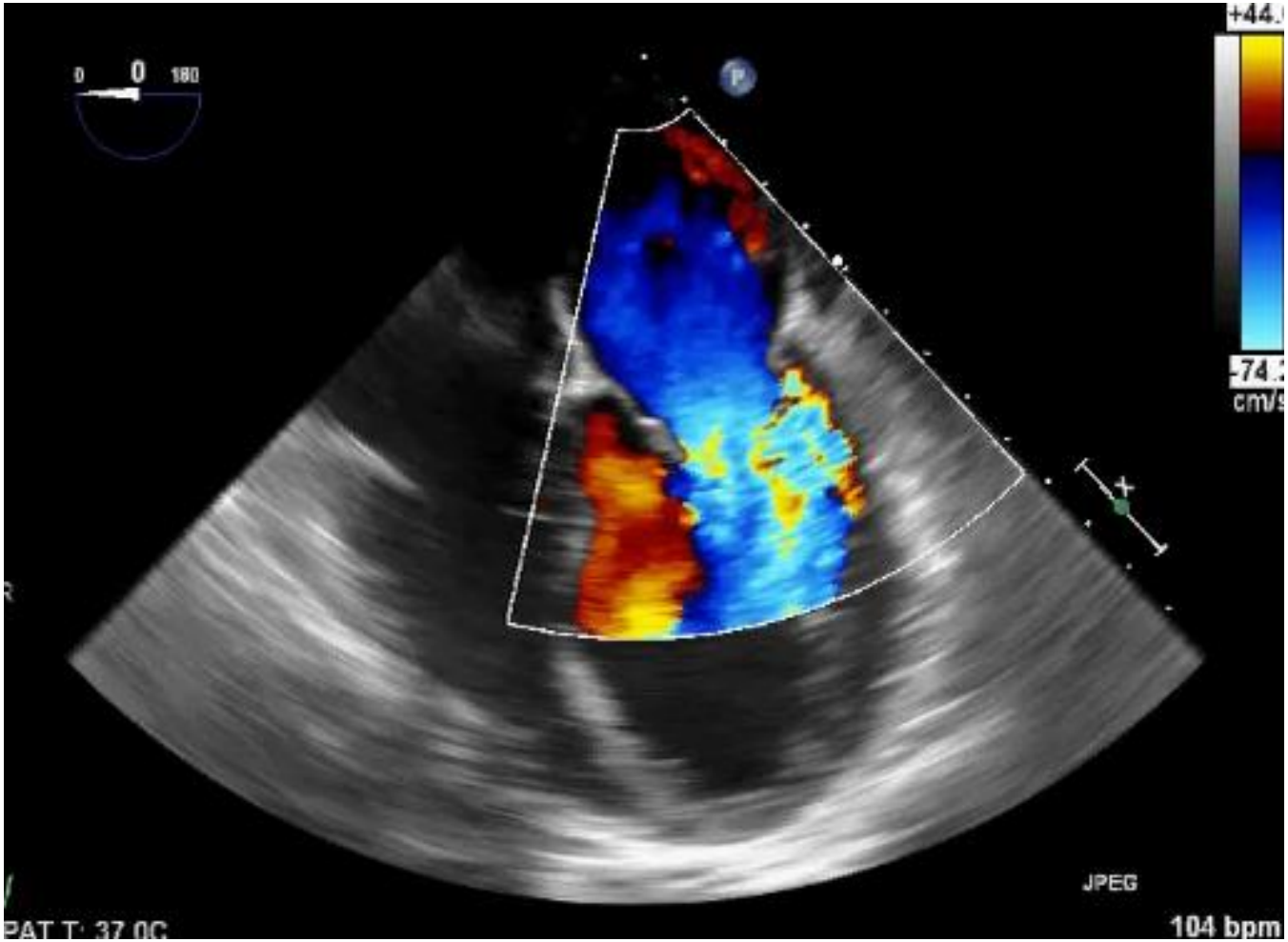
0
0
180
+44.
-74.
cm/s
JPEG
104 bpm

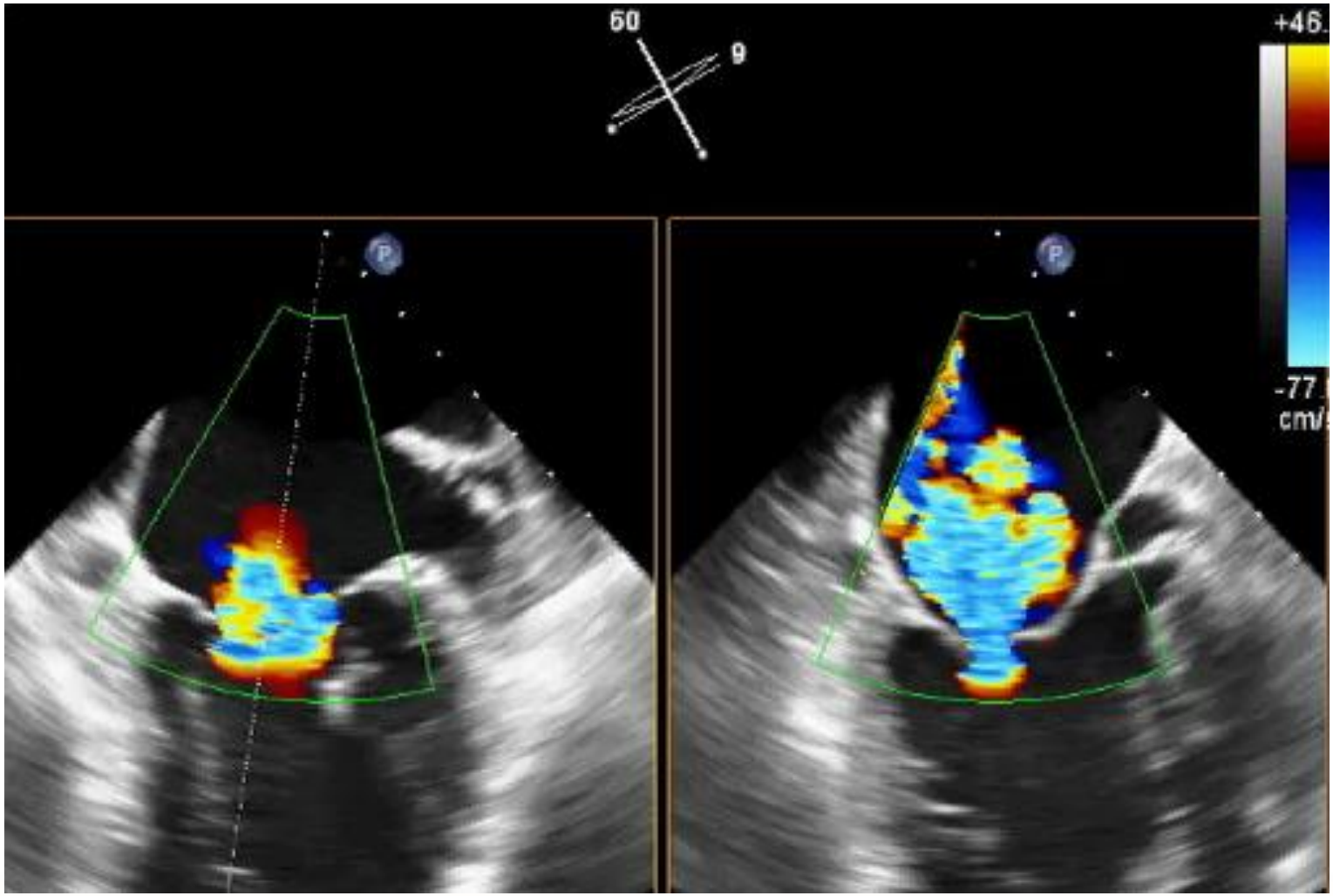
60
9
+46
-77
cm/

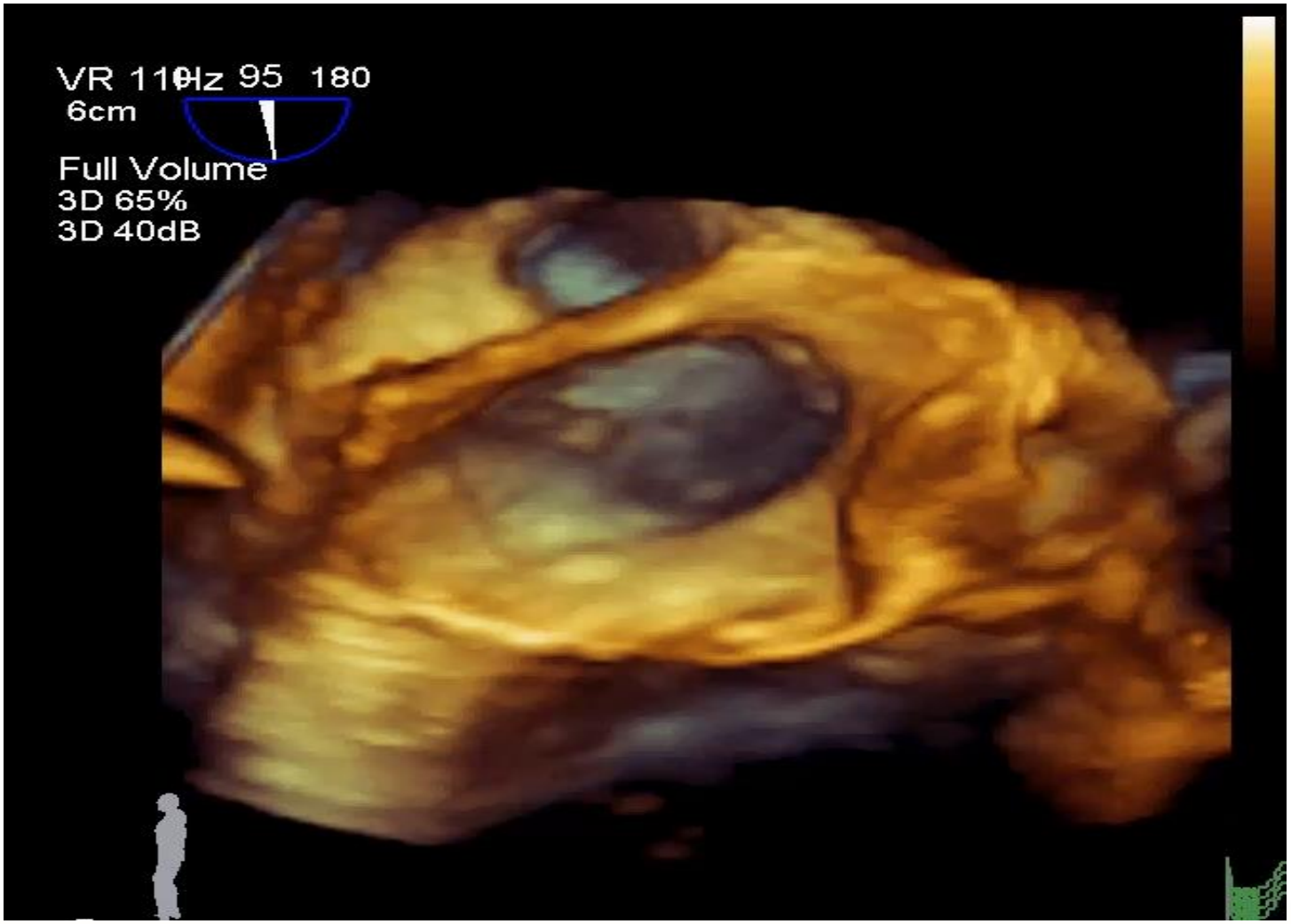
VR 110Hz 95 180
6cm
Full Volume
3D 65%
3D 40dB

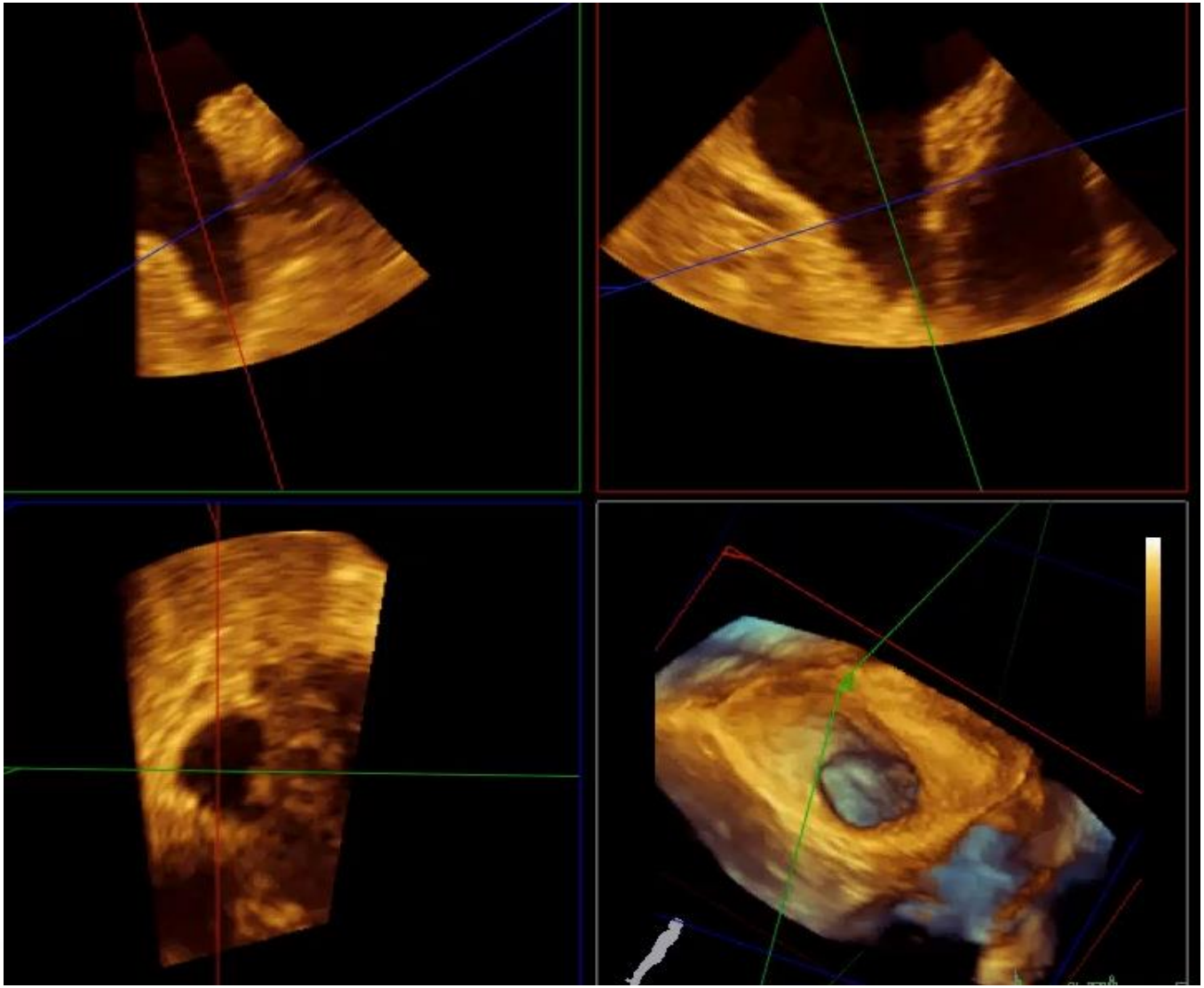

During the procedure

TSP

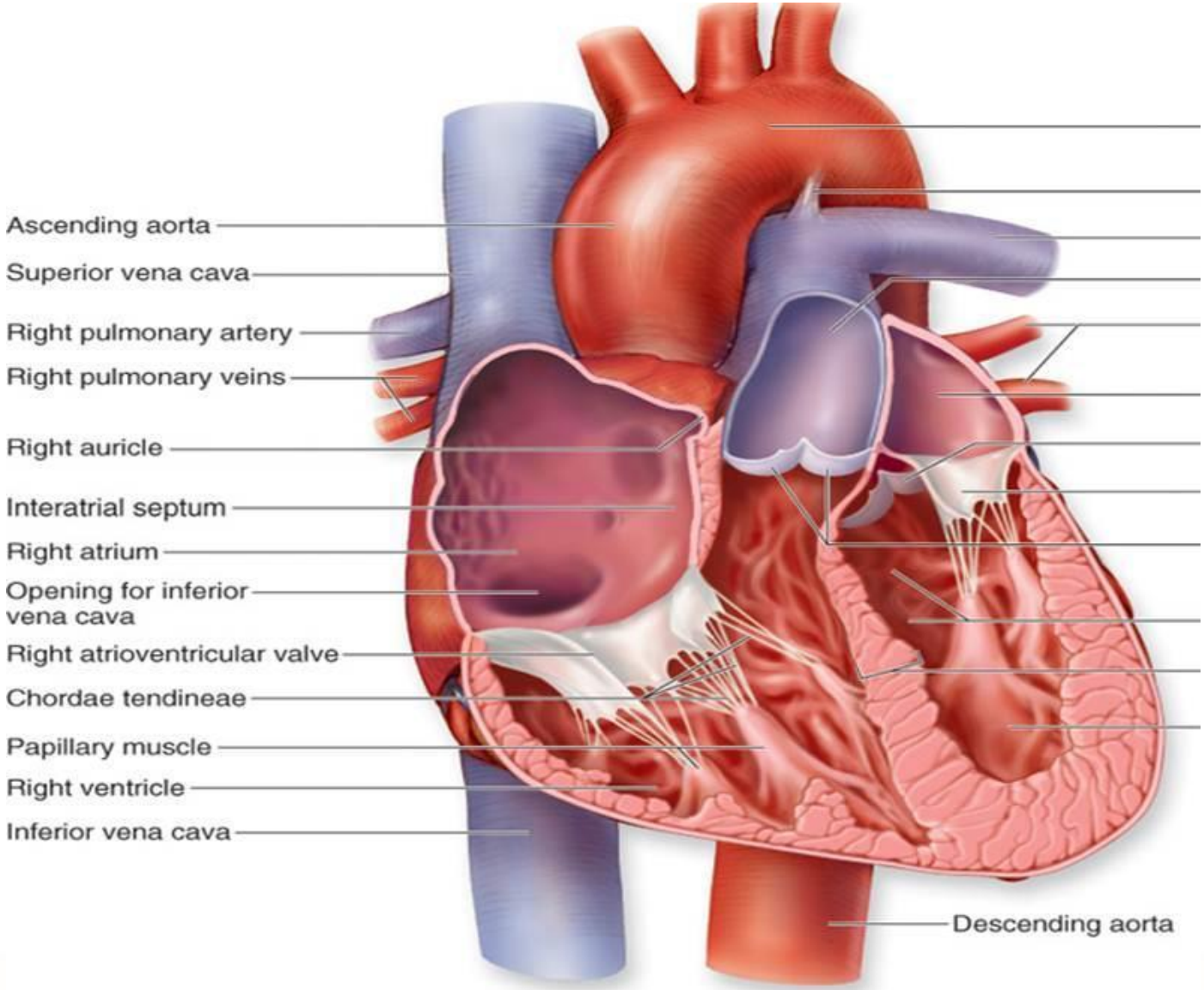
Ascending aorta
Superior vena cava
Right pulmonary artery
Right pulmonary veins
Right auricle
Interatrial septum
Right atrium
Opening for inferior vena cava
Right atrioventricular valve
Chordae tendineae
Papillary muscle
Right ventricle
Inferior vena cava
Descending aorta

2D-TEE

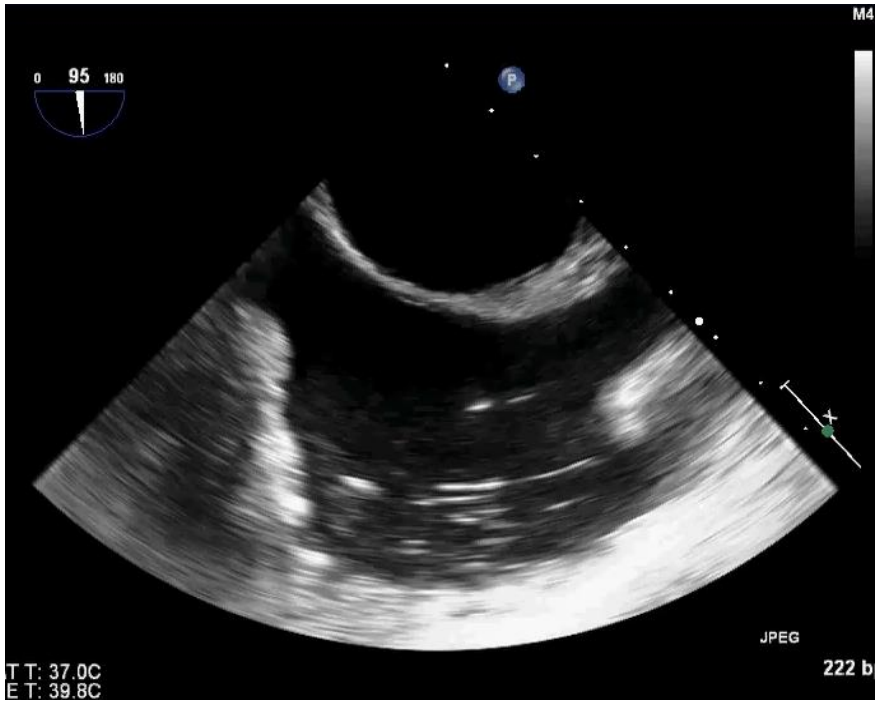

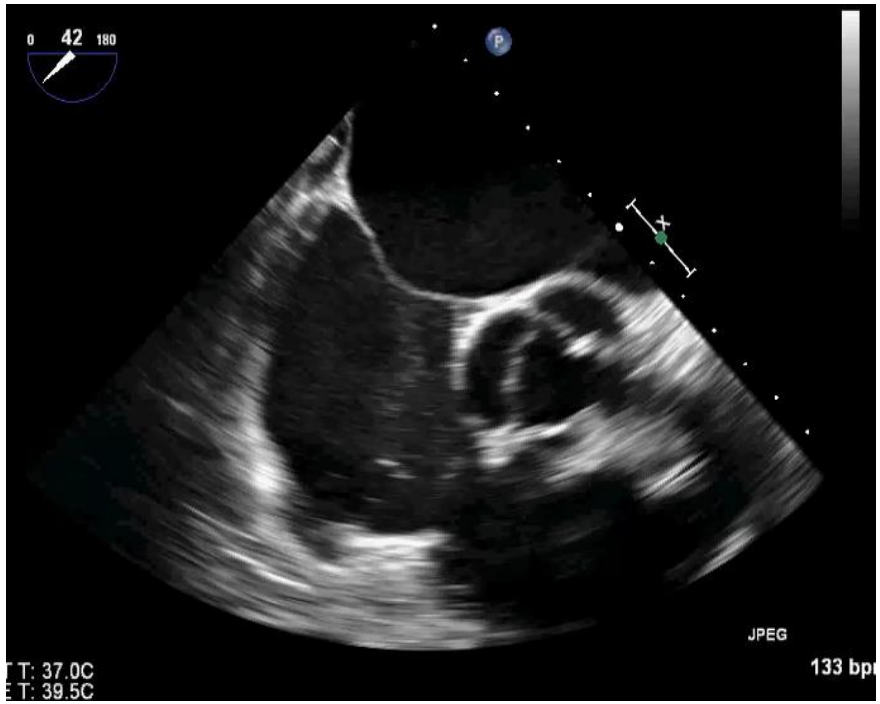

RATLe-90 maneuver

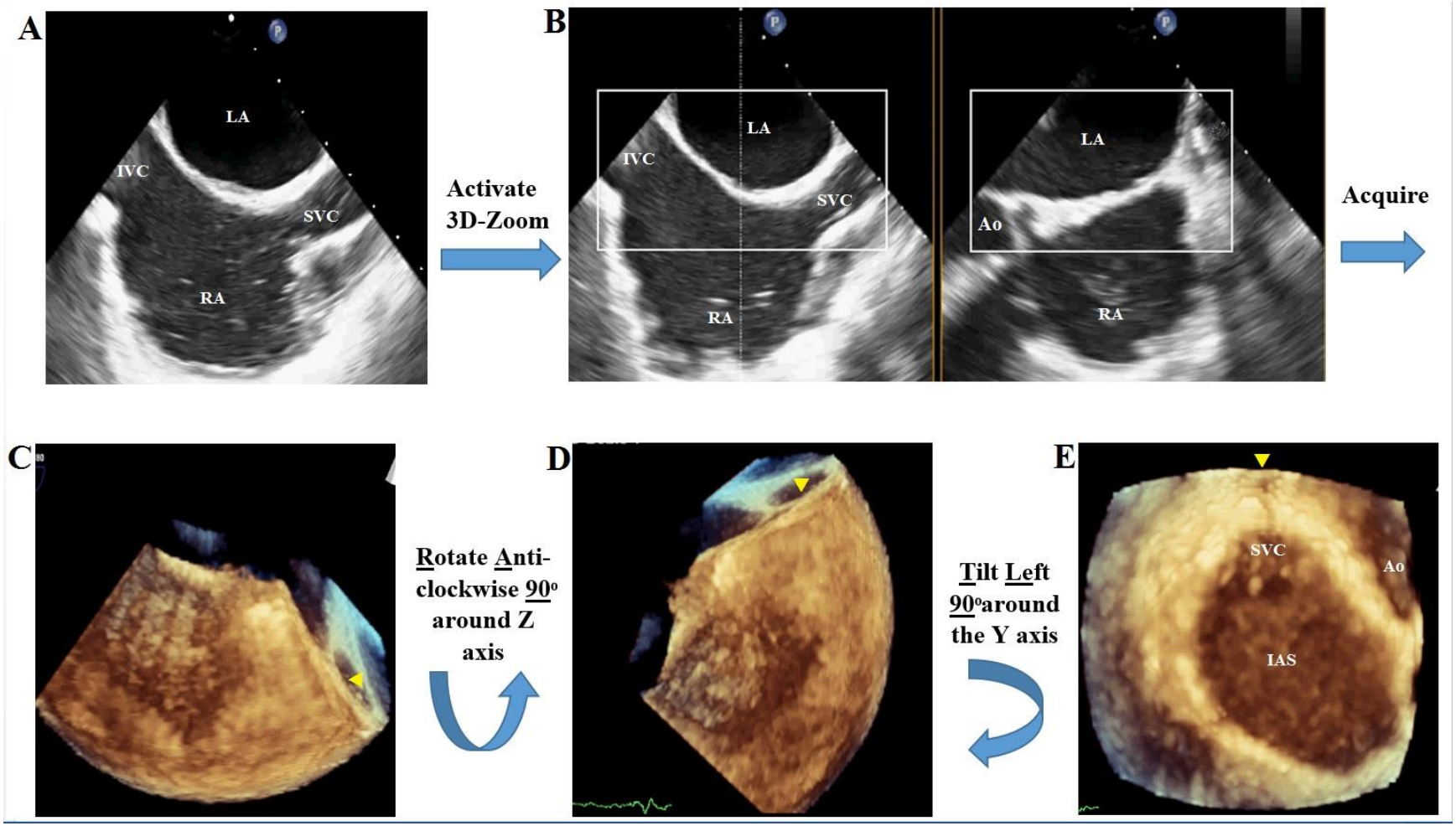

HM. Mahmoud et al. Cardiol Res Pract, 2015. doi:10.1155/2015/174051

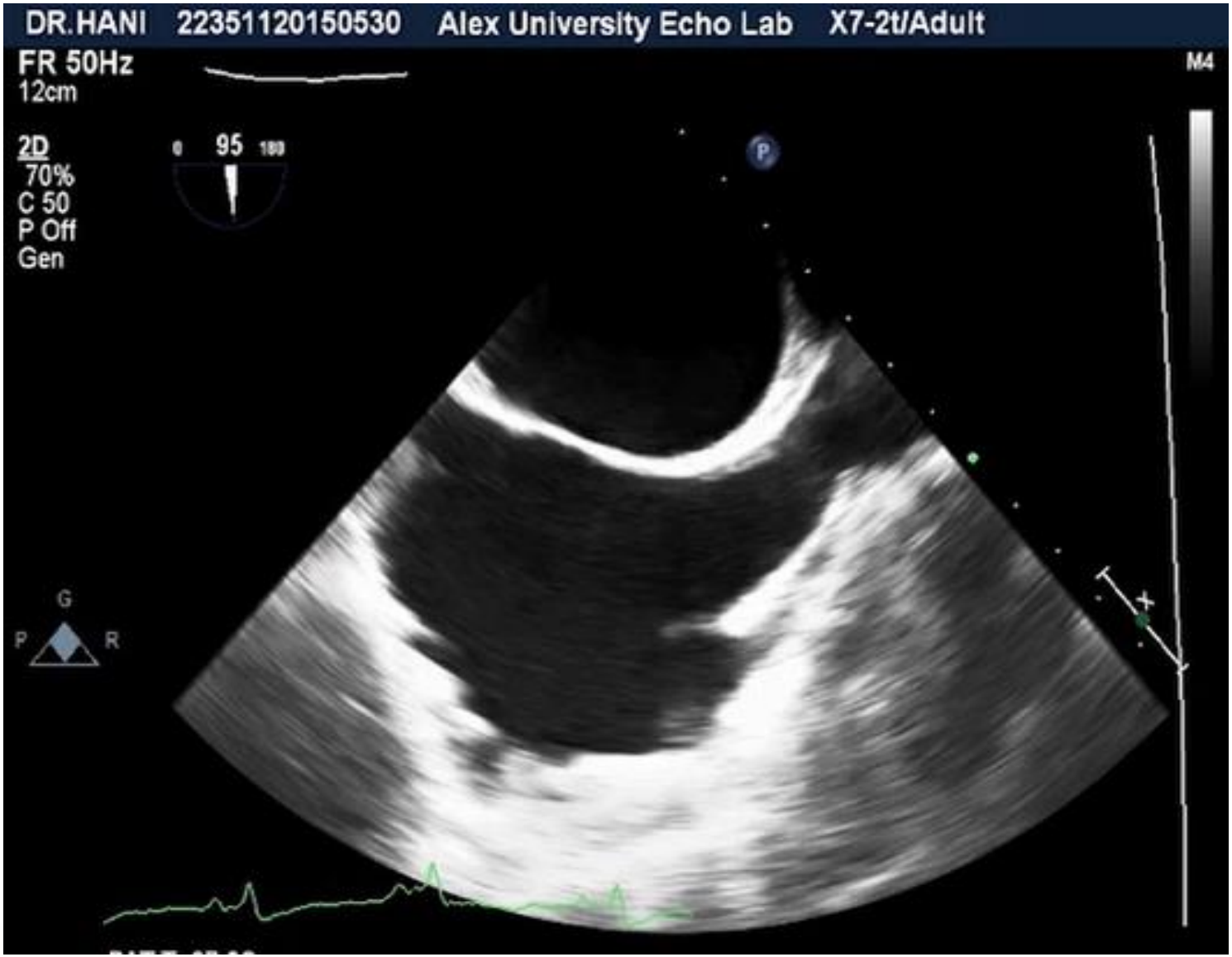

HM. Mahmoud et al. Cardiol Res Pract, 2015. doi:10.1155/2015/174051

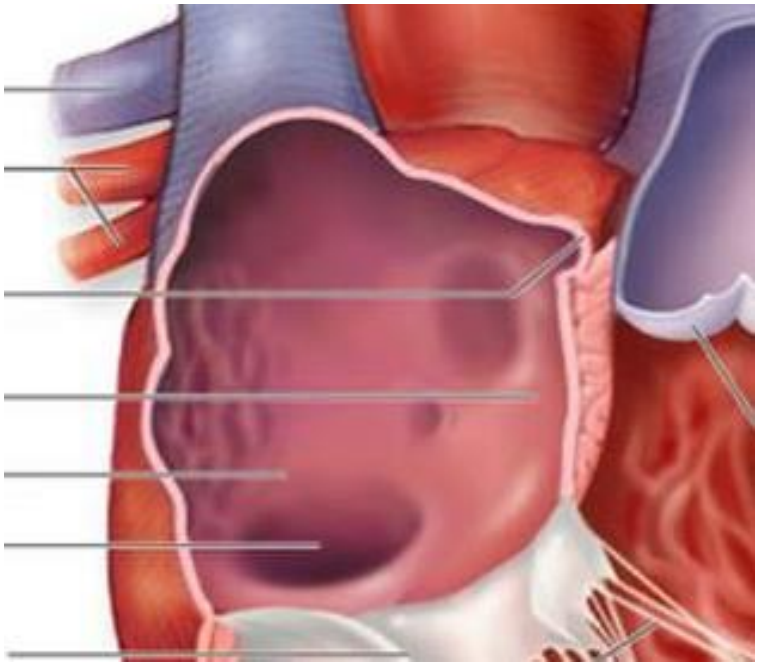

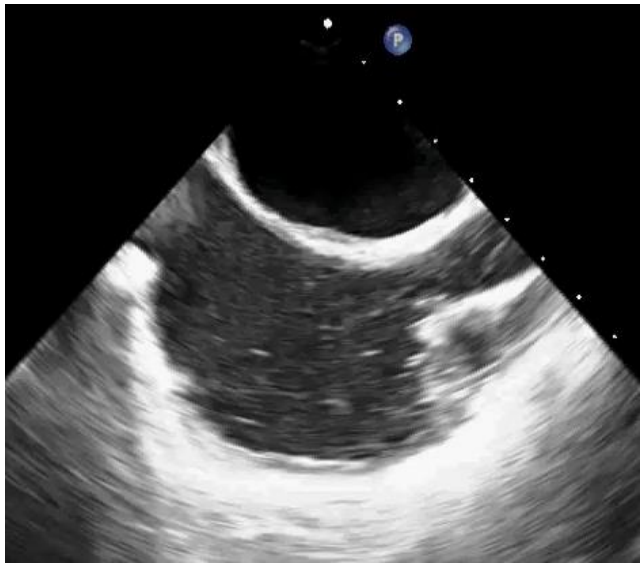

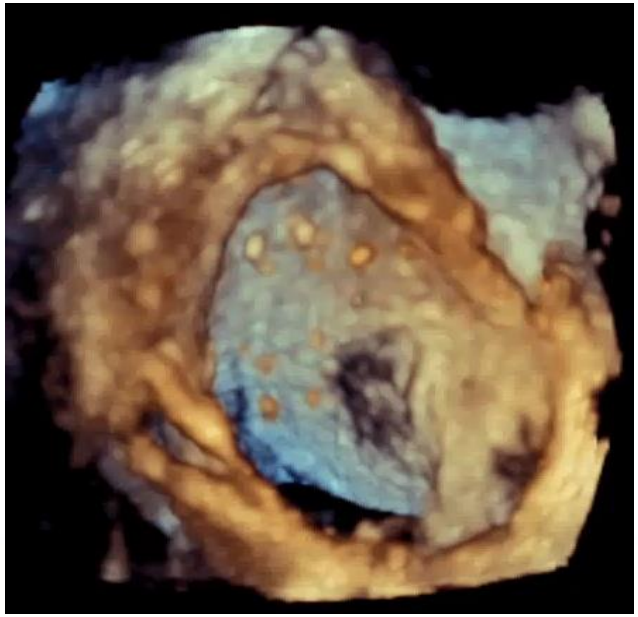

HM. Mahmoud et al. Cardiol Res Pract, 2015. doi:10.1155/2015/174051

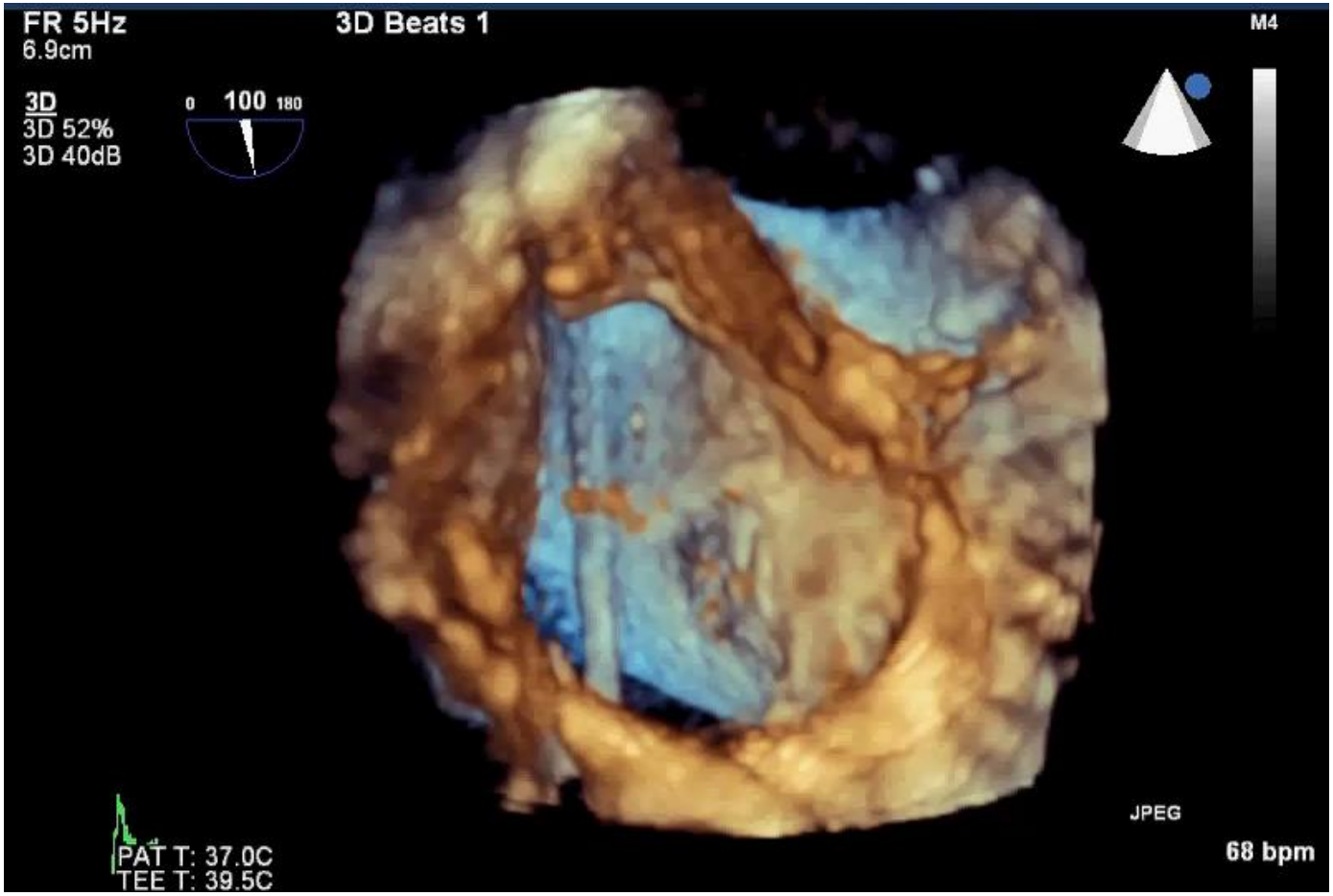

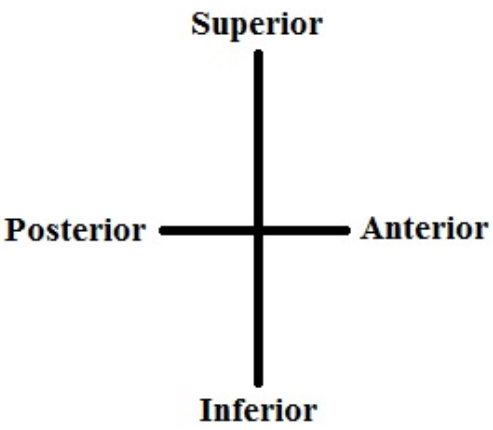

HM. Mahmoud et al. Cardiol Res Pract, 2015. doi:10.1155/2015/174051

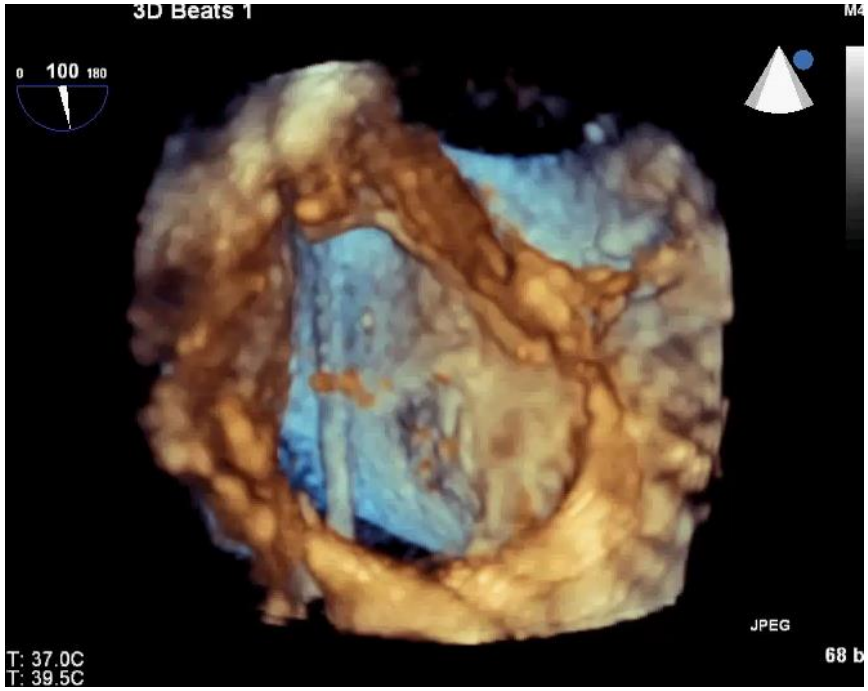

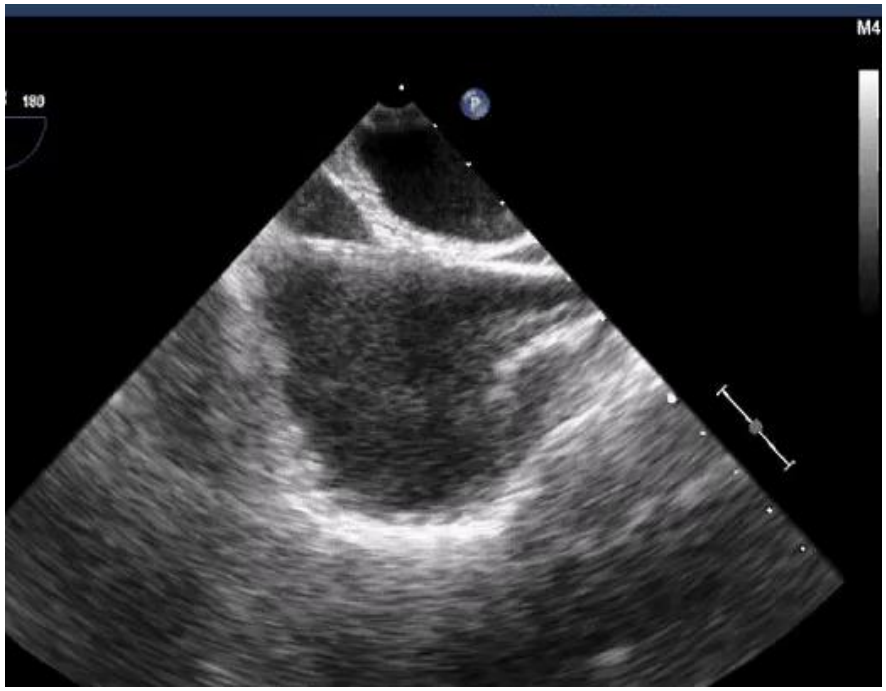

HM. Mahmoud et al. Cardiol Res Pract, 2015. doi:10.1155/2015/174051

3D-TOE guided Septal Puncture

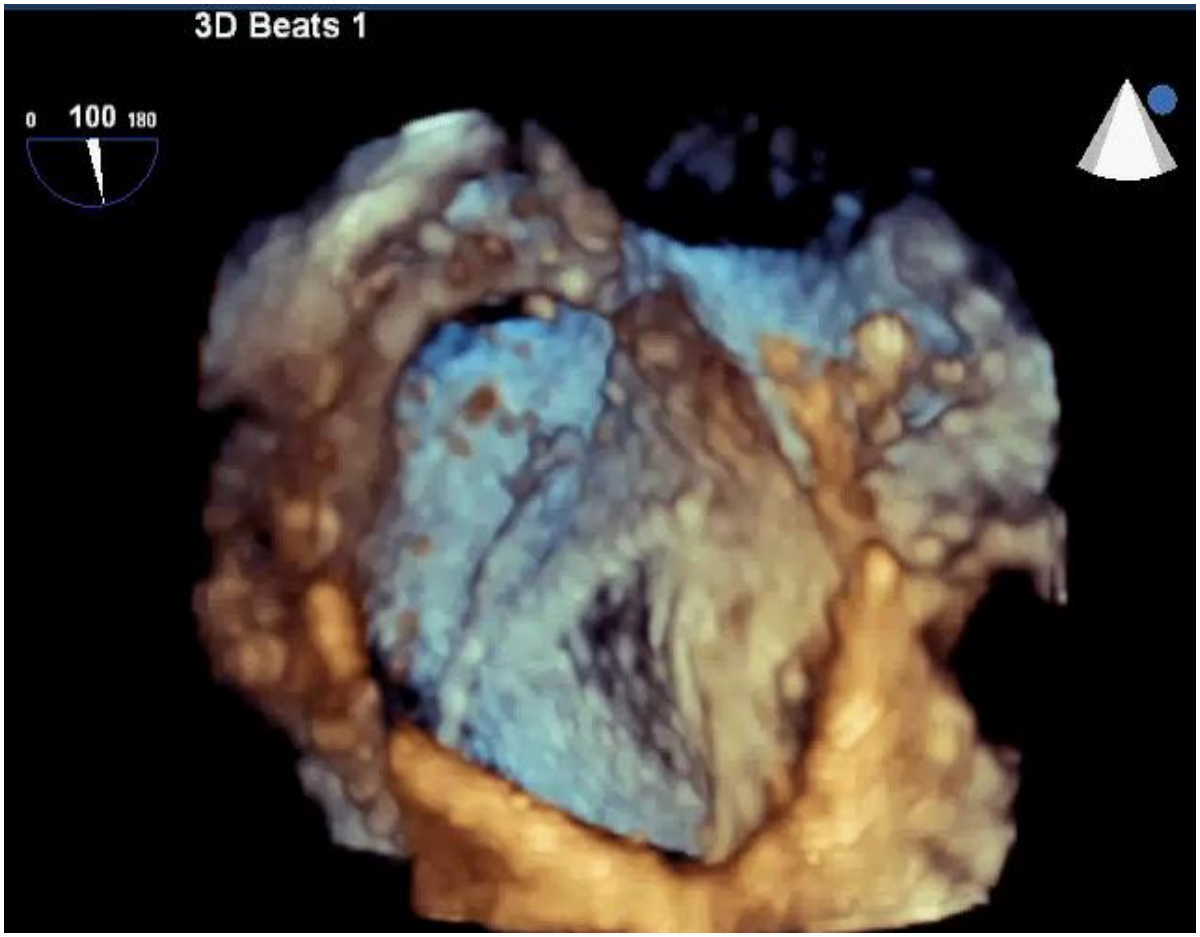

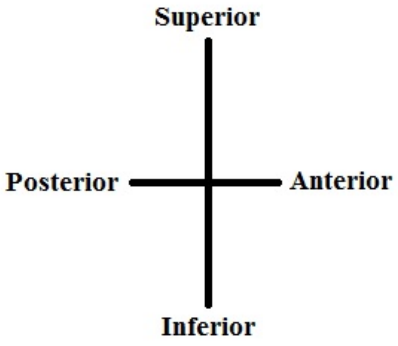

HM. Mahmoud et al. Cardiol Res Pract, 2015. doi:10.1155/2015/174051

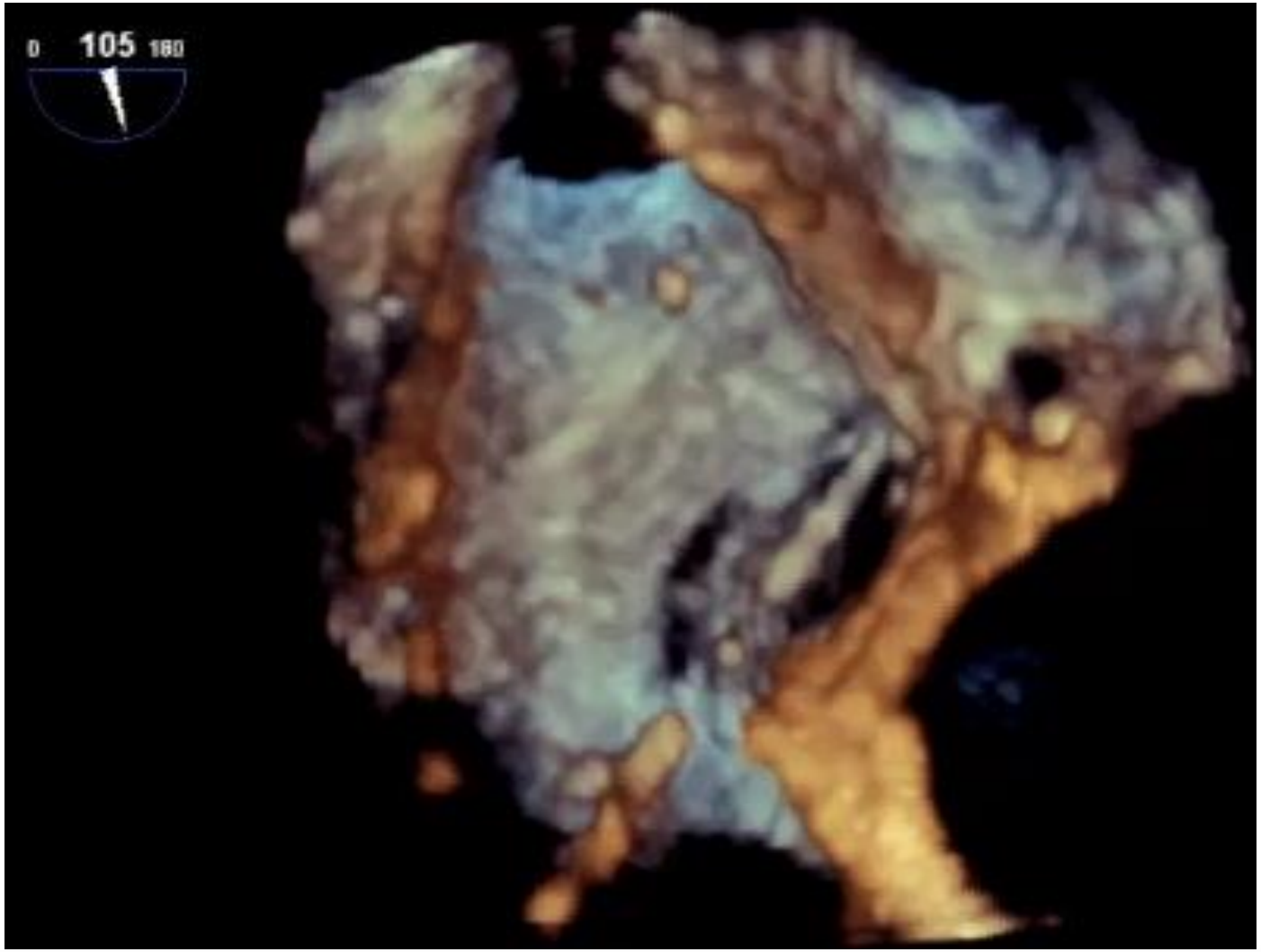

HM. Mahmoud et al. Cardiol Res Pract, 2015. doi:10.1155/2015/174051

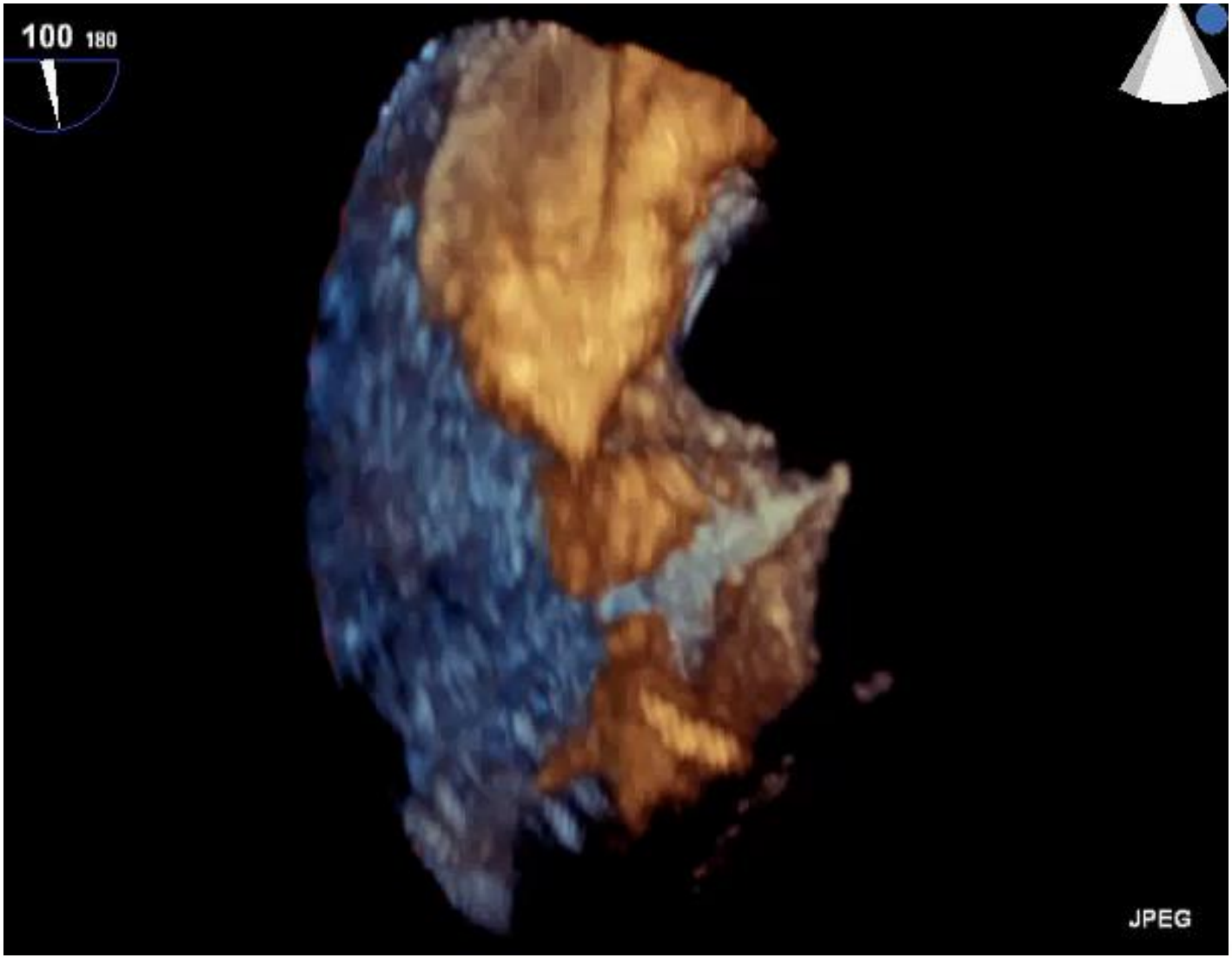

HM. Mahmoud et al. Cardiol Res Pract, 2015. doi:10.1155/2015/174051

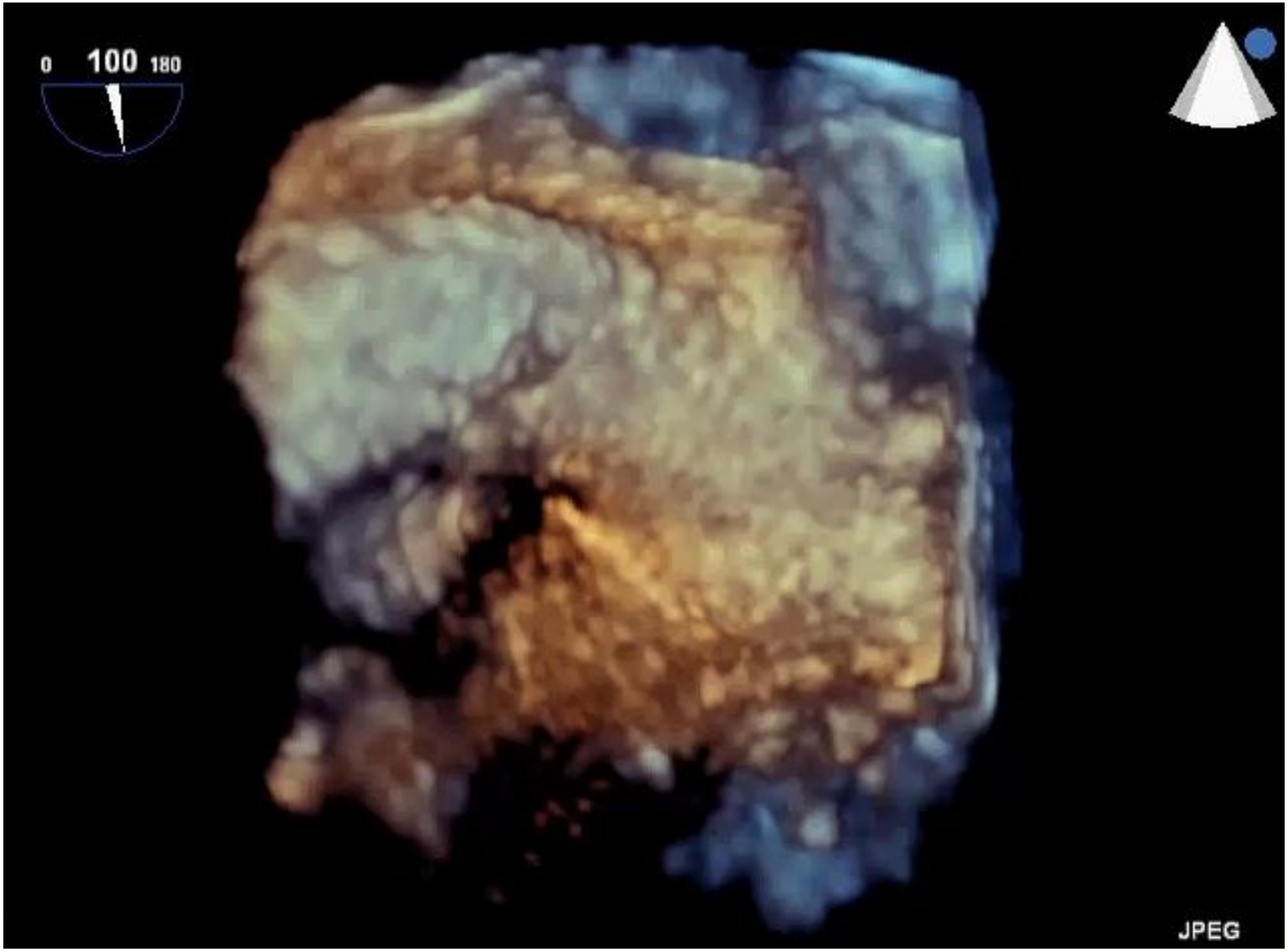

HM. Mahmoud et al. Cardiol Res Pract, 2015. doi:10.1155/2015/174051

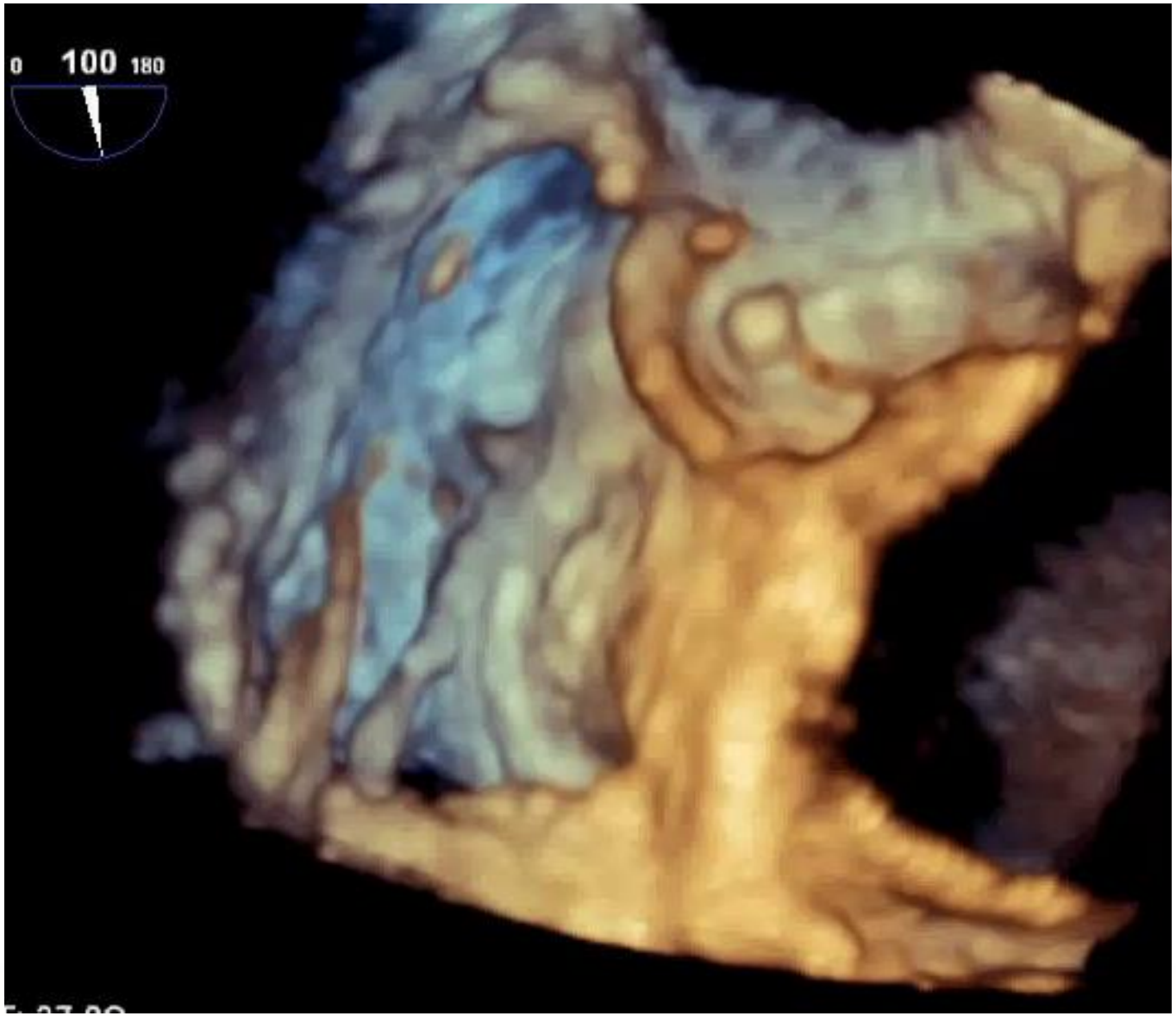

HM. Mahmoud et al. Cardiol Res Pract, 2015. doi:10.1155/2015/174051

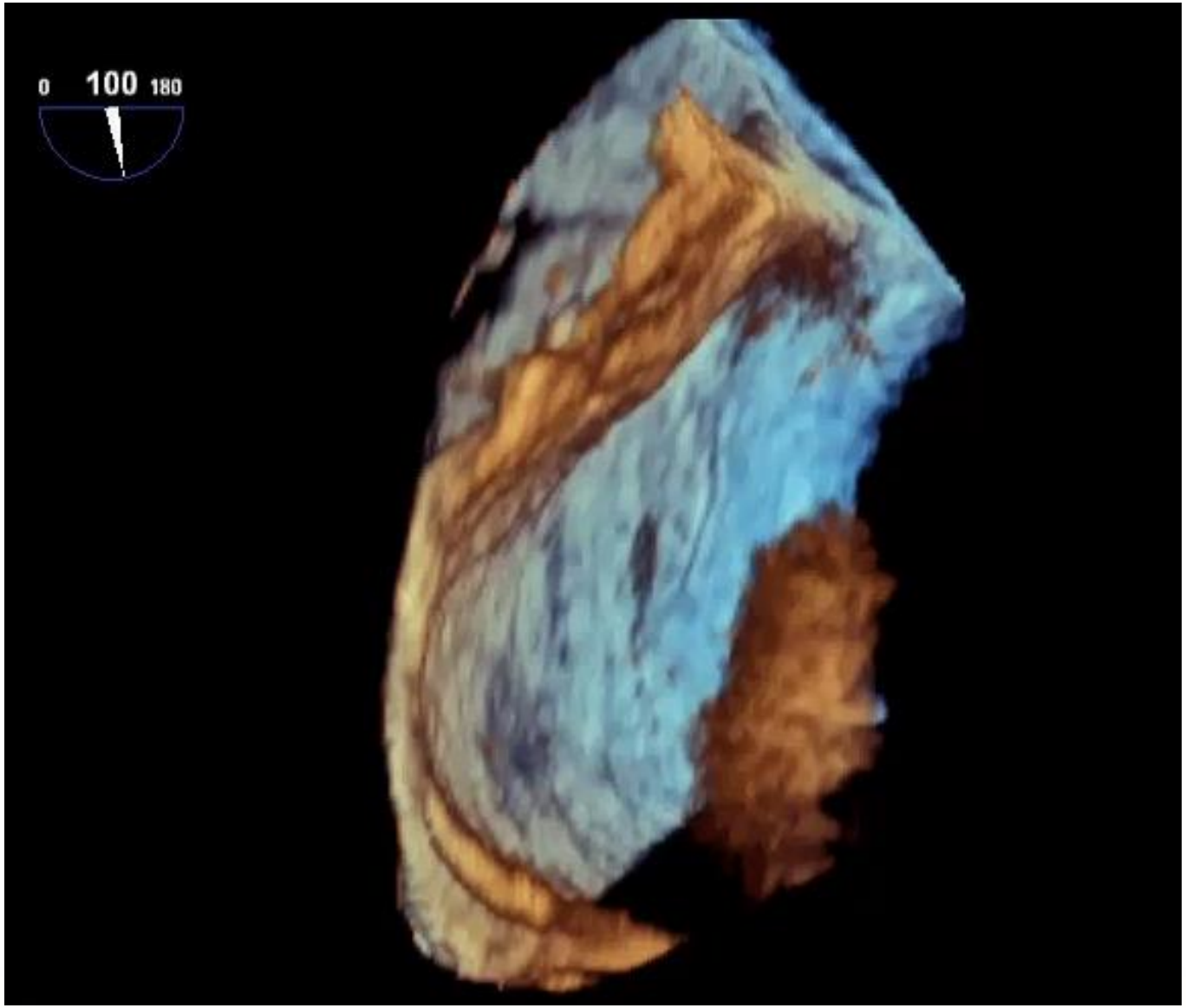

HM. Mahmoud et al. Cardiol Res Pract, 2015. doi:10.1155/2015/174051

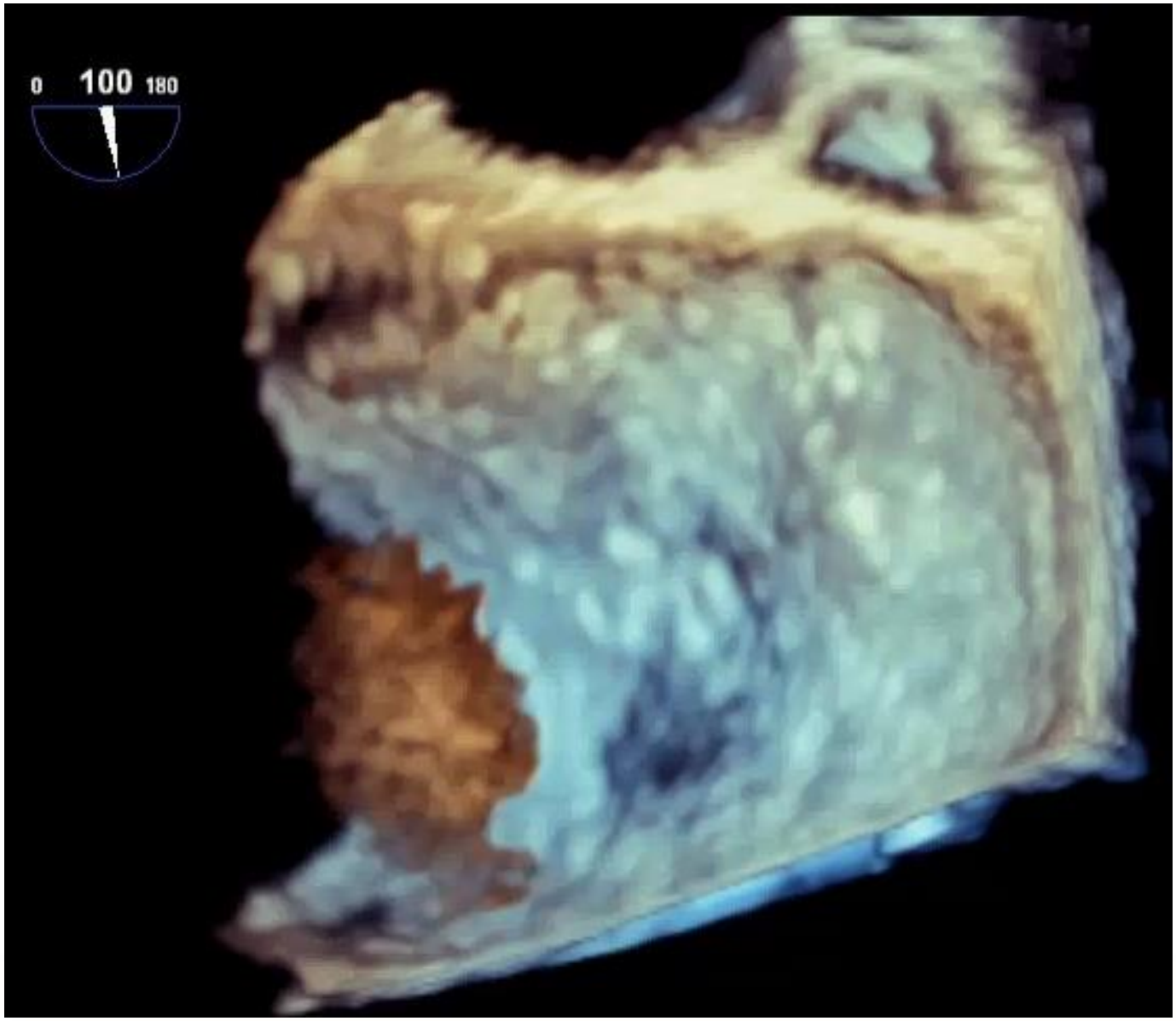

HM. Mahmoud et al. Cardiol Res Pract, 2015. doi:10.1155/2015/174051

Cardiology Research and Practice

Cardiology Research and Practice
Volume 2015 (2015), Article ID 174051, 4 pages
http://dx.doi.org/10.1155/2015/174051

Research Article

A Proposed Maneuver to Guide Transseptal Puncture Using Real-Time Three-Dimensional Transesophageal Echocardiography: Pilot Study

Hani M. Mahmoud,[1] Mohammed A. Al-Ghamdi,[1] Abdullah E. Ghabashi,[1] and Ashraf M. Anwar[2]

Received 20 April 2015; Revised 17 May 2015; Accepted 19 May 2015

Academic Editor: Terrence D. Ruddy

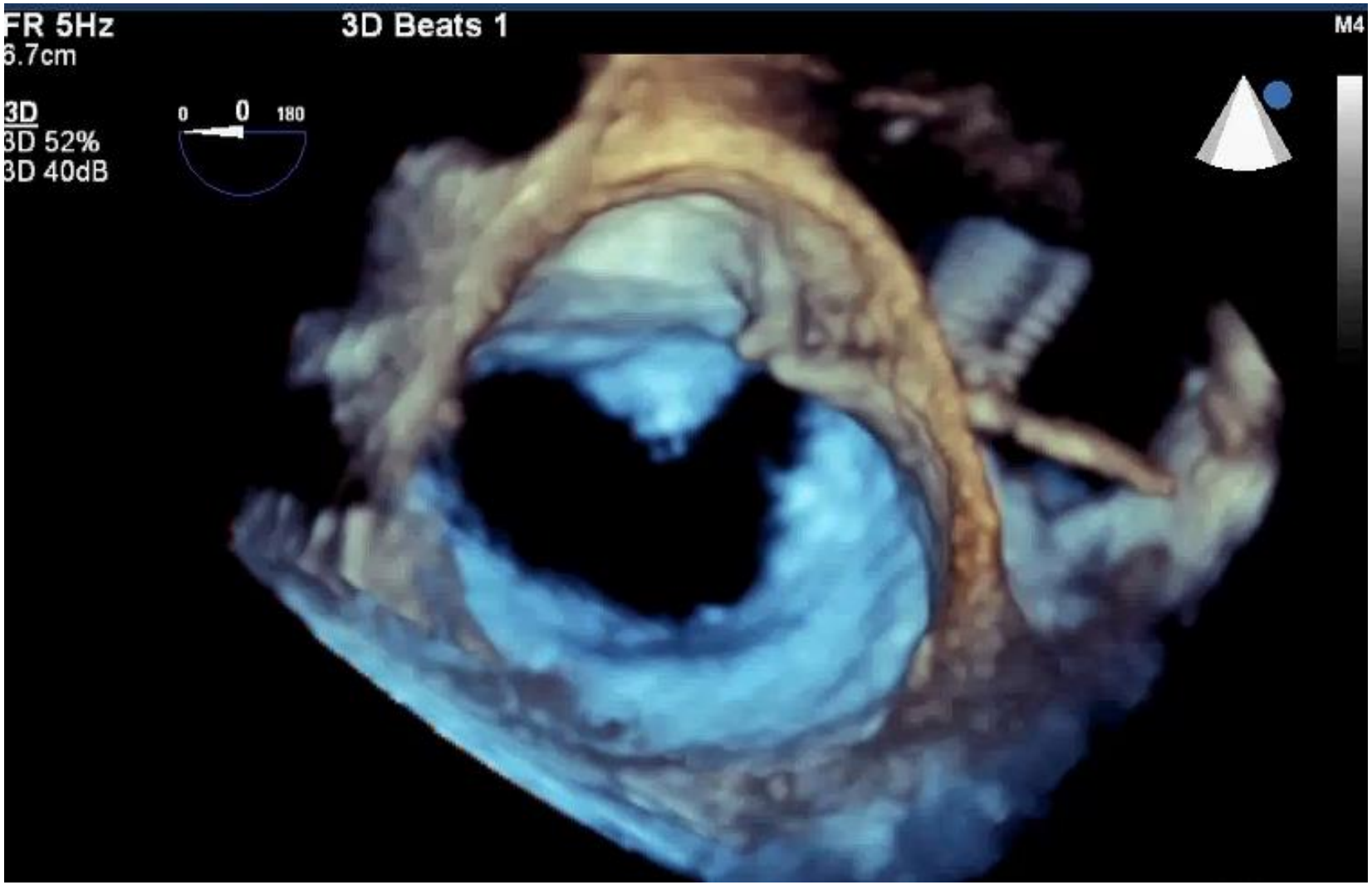
FR 5Hz
6.7cm
3D Beats 1
M4
3D
3D 52%
3D 40dB
0
0
180

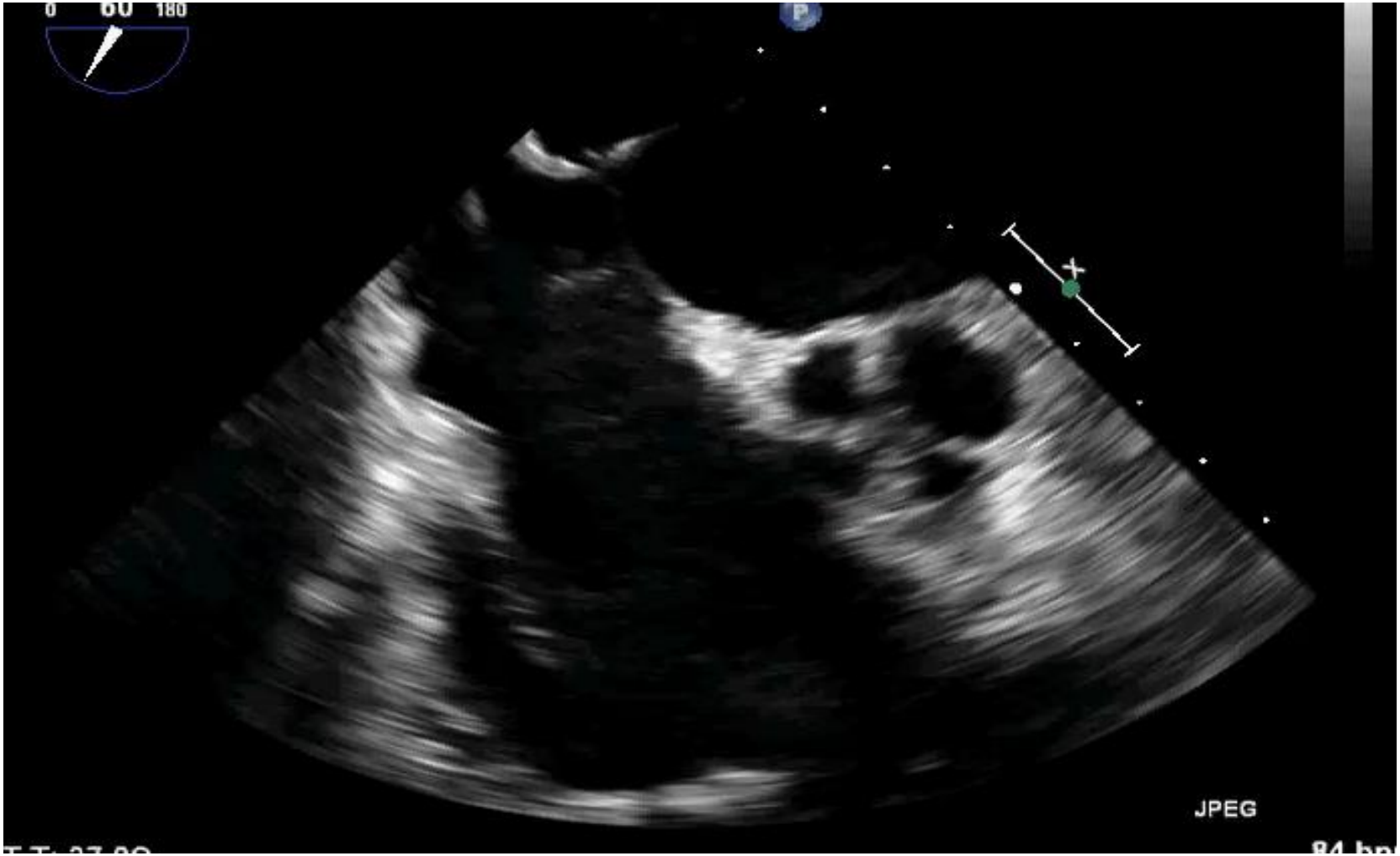
0
60
180
P
JPEG

Tenting height

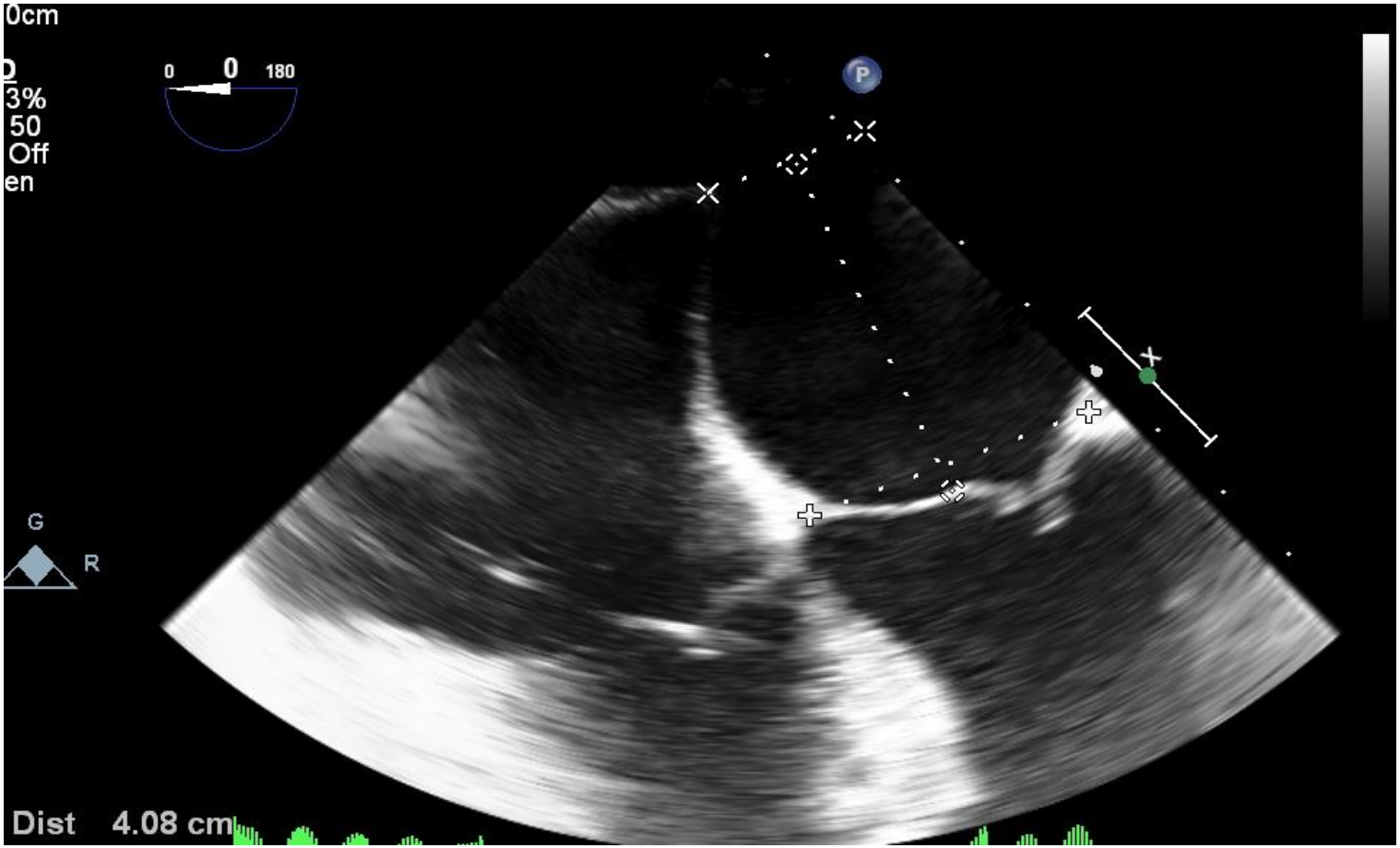

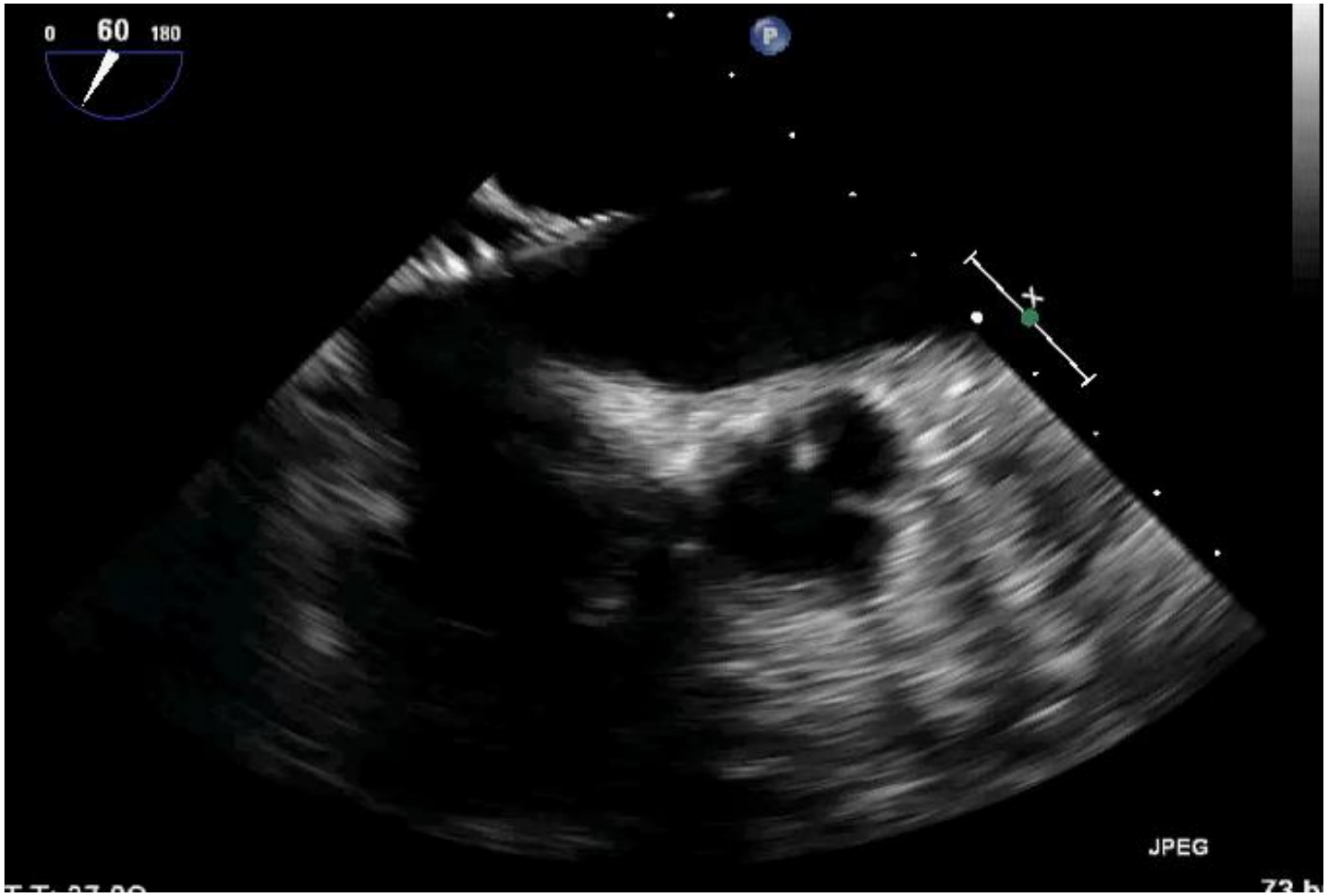
0
60
180
P
JPEG


0
70
180
P
JPEG


0
66
180
P
JPEG

Guiding the sheath insertion through the septum

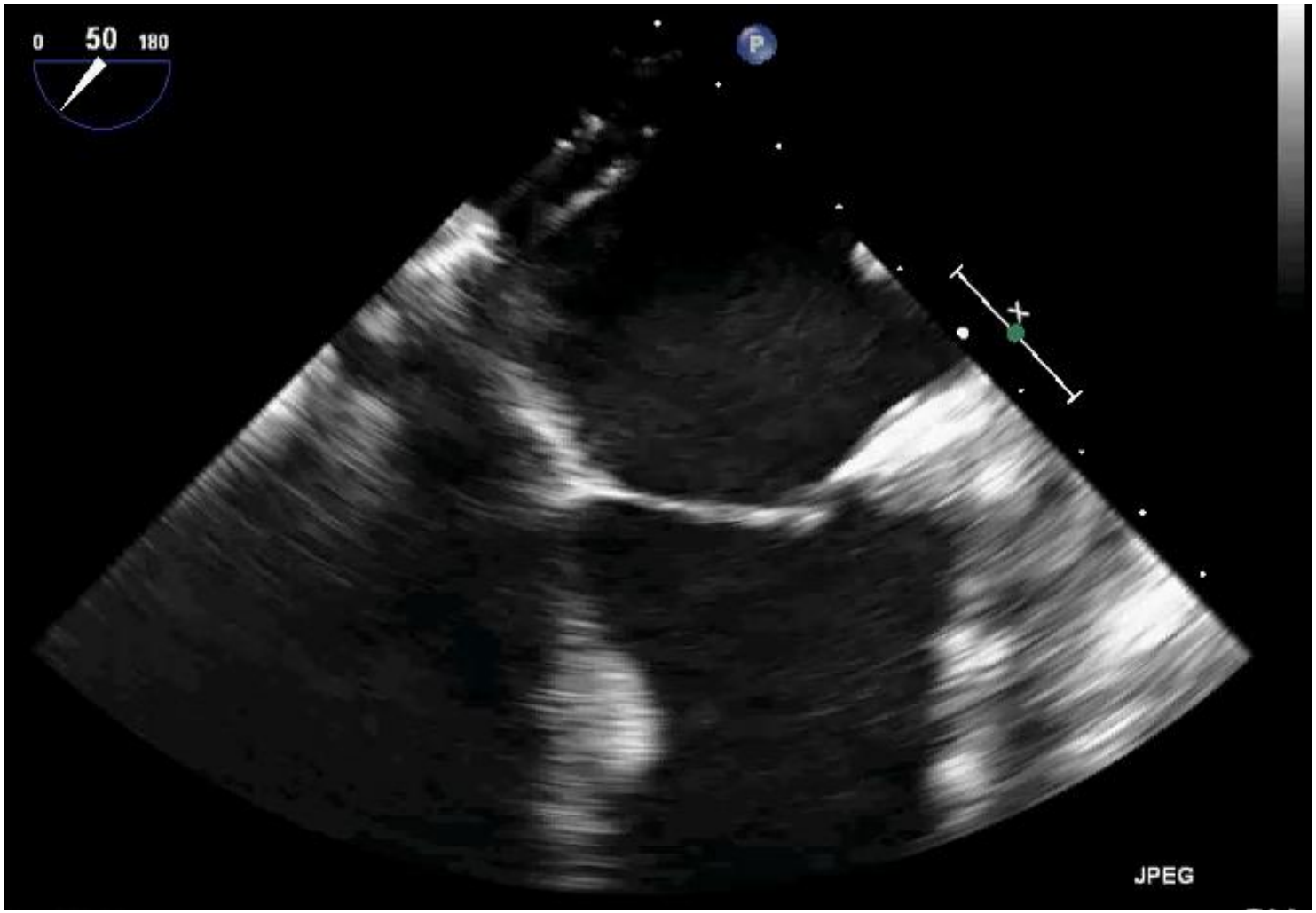

Guide catheter through the septum

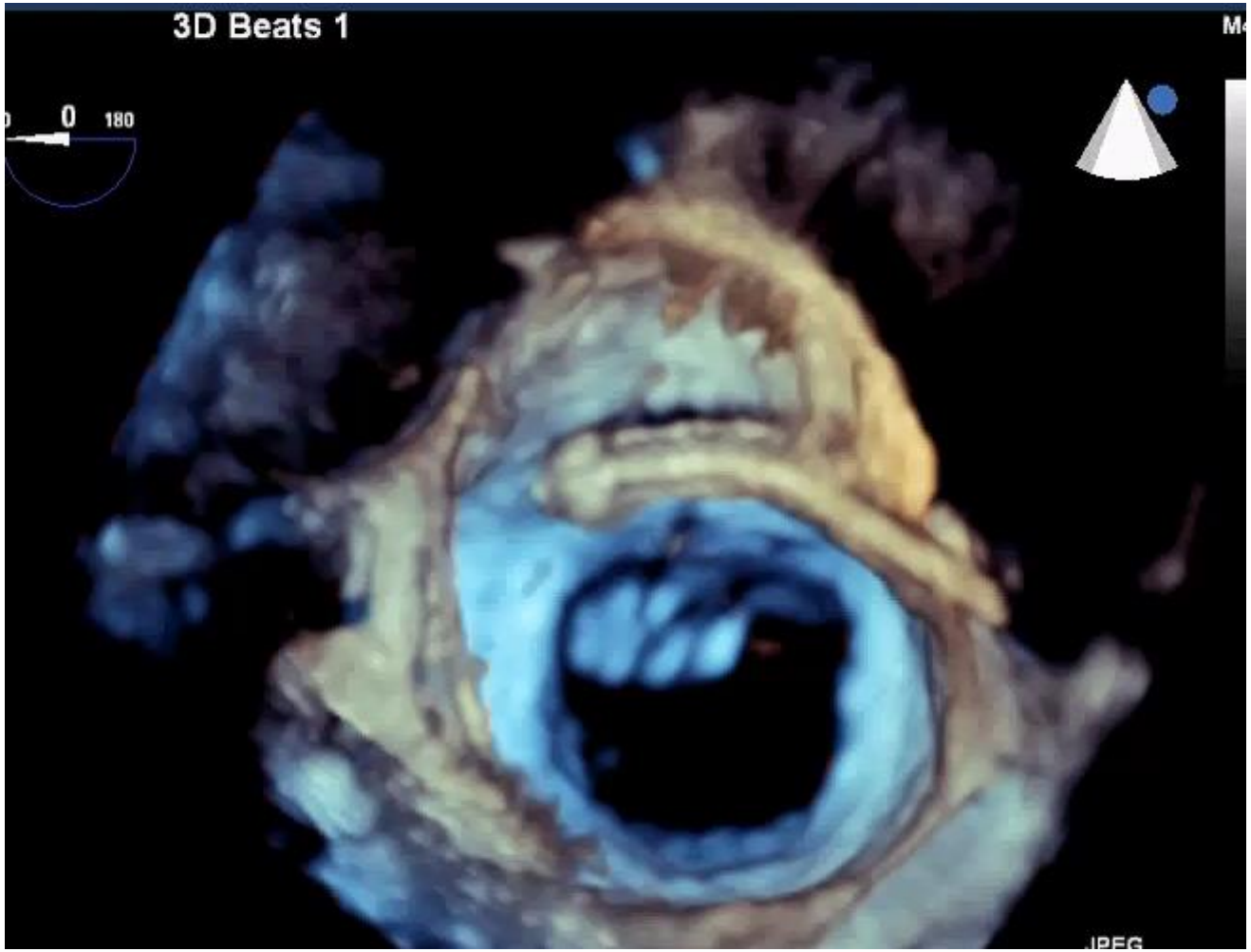

Wiring the pulmonary vein

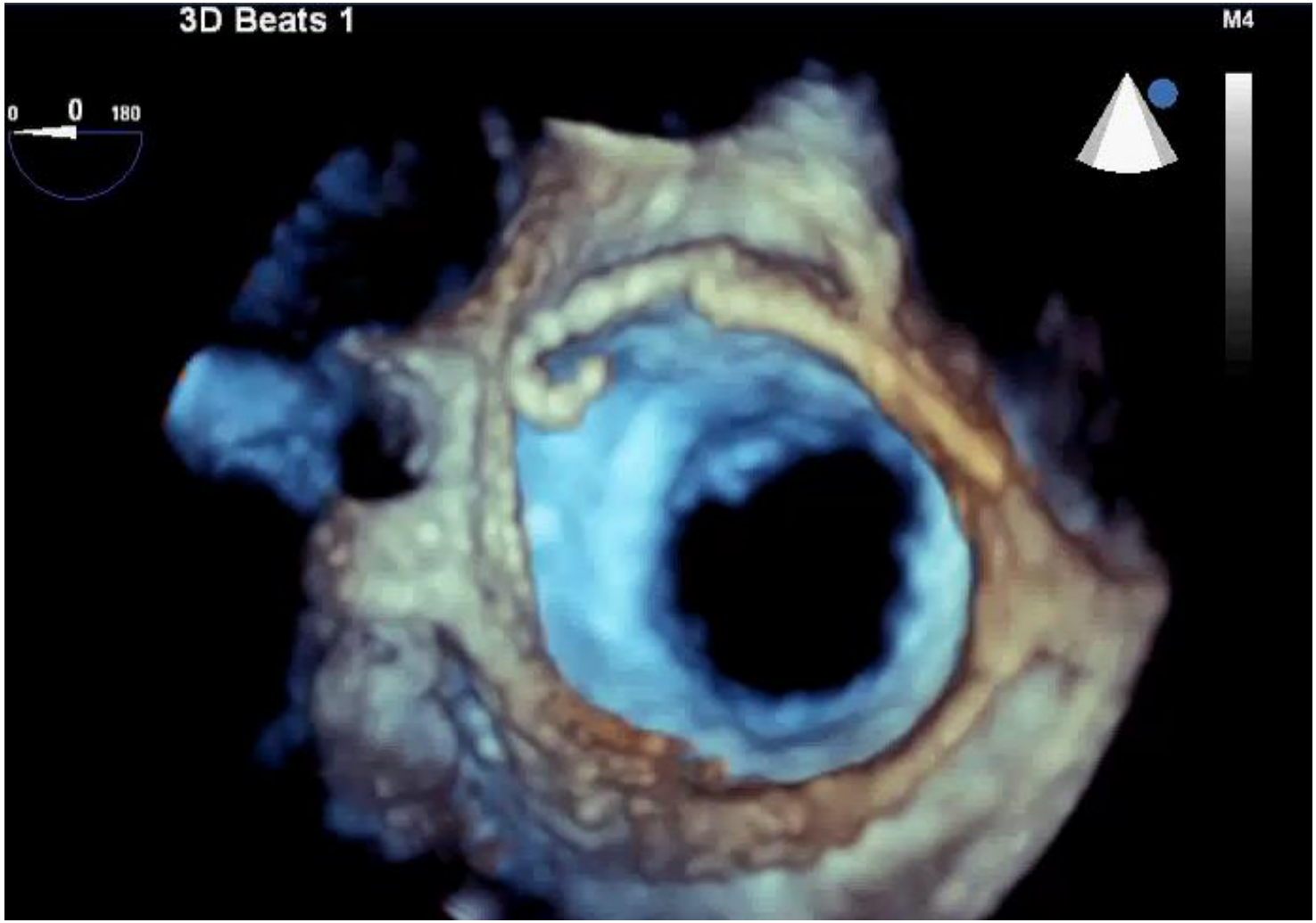

Wiring the pulmonary vein

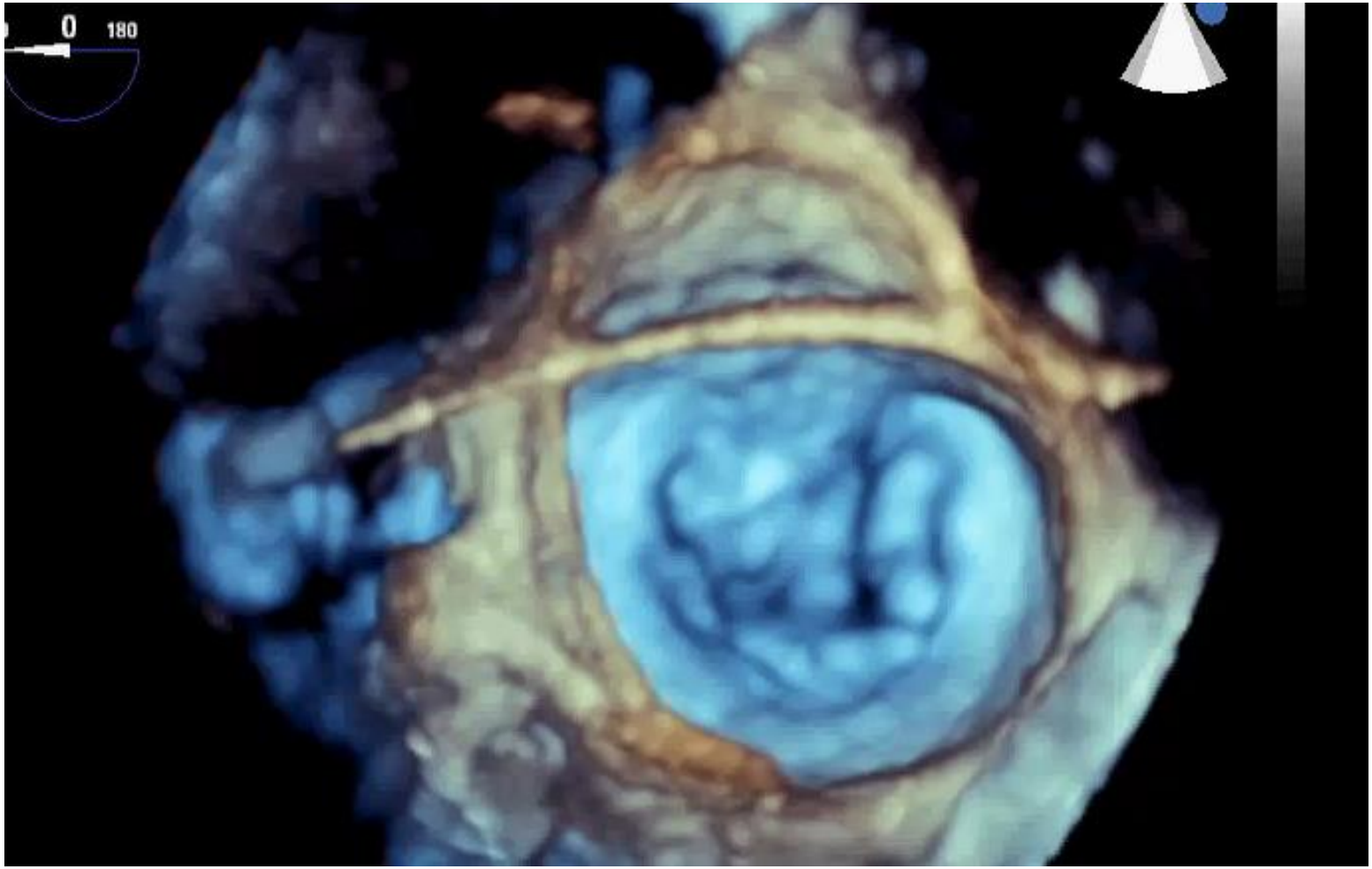

Introduction of the MitraClip device

Introduction of the MitraClip device

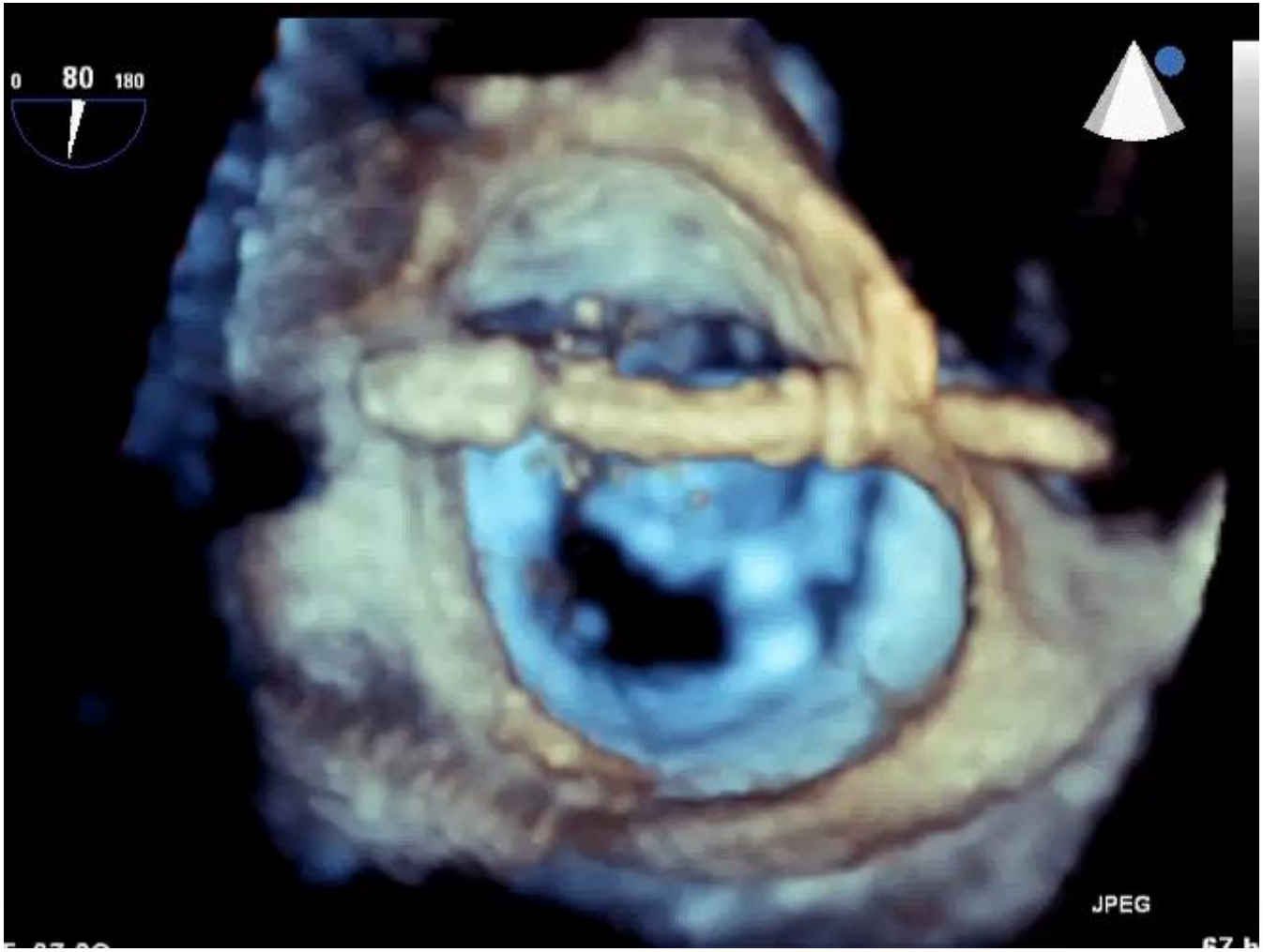

Introduction of the MitraClip device

Introduction of the MitraClip device

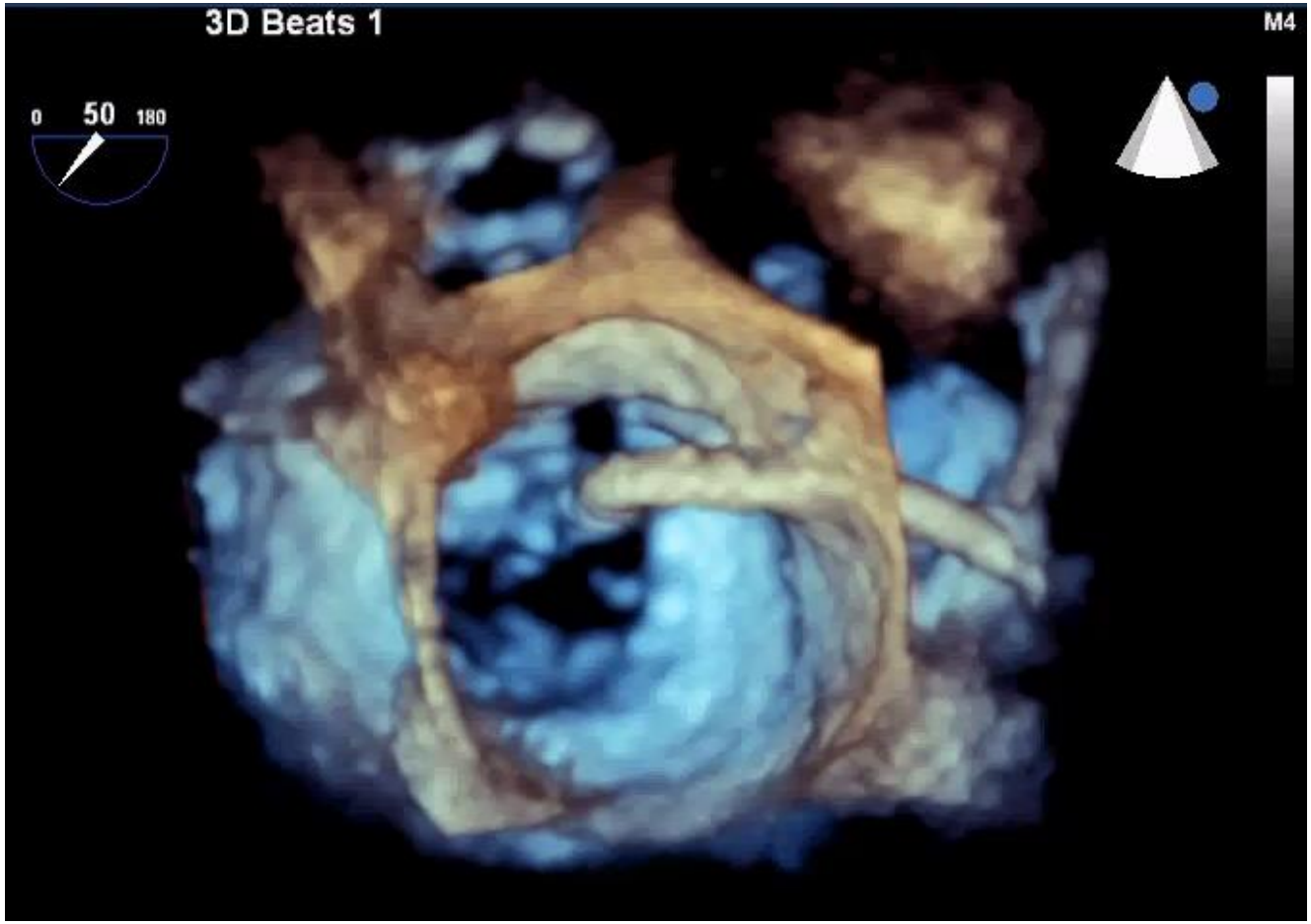

Optimizing the Clip position in relation to the mitral valve leaflets

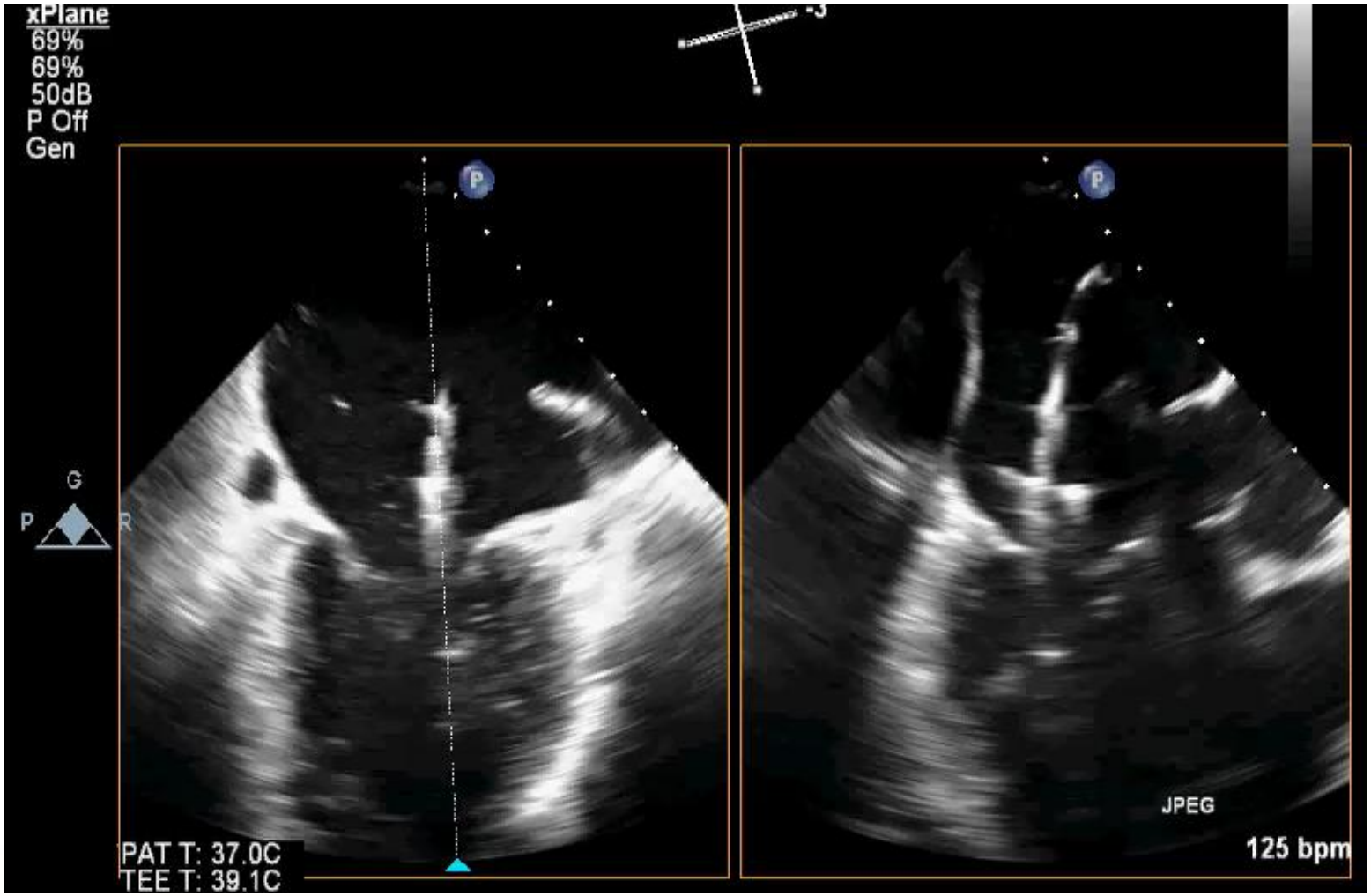

Optimizing the Clip position in relation to the mitral valve leaflets

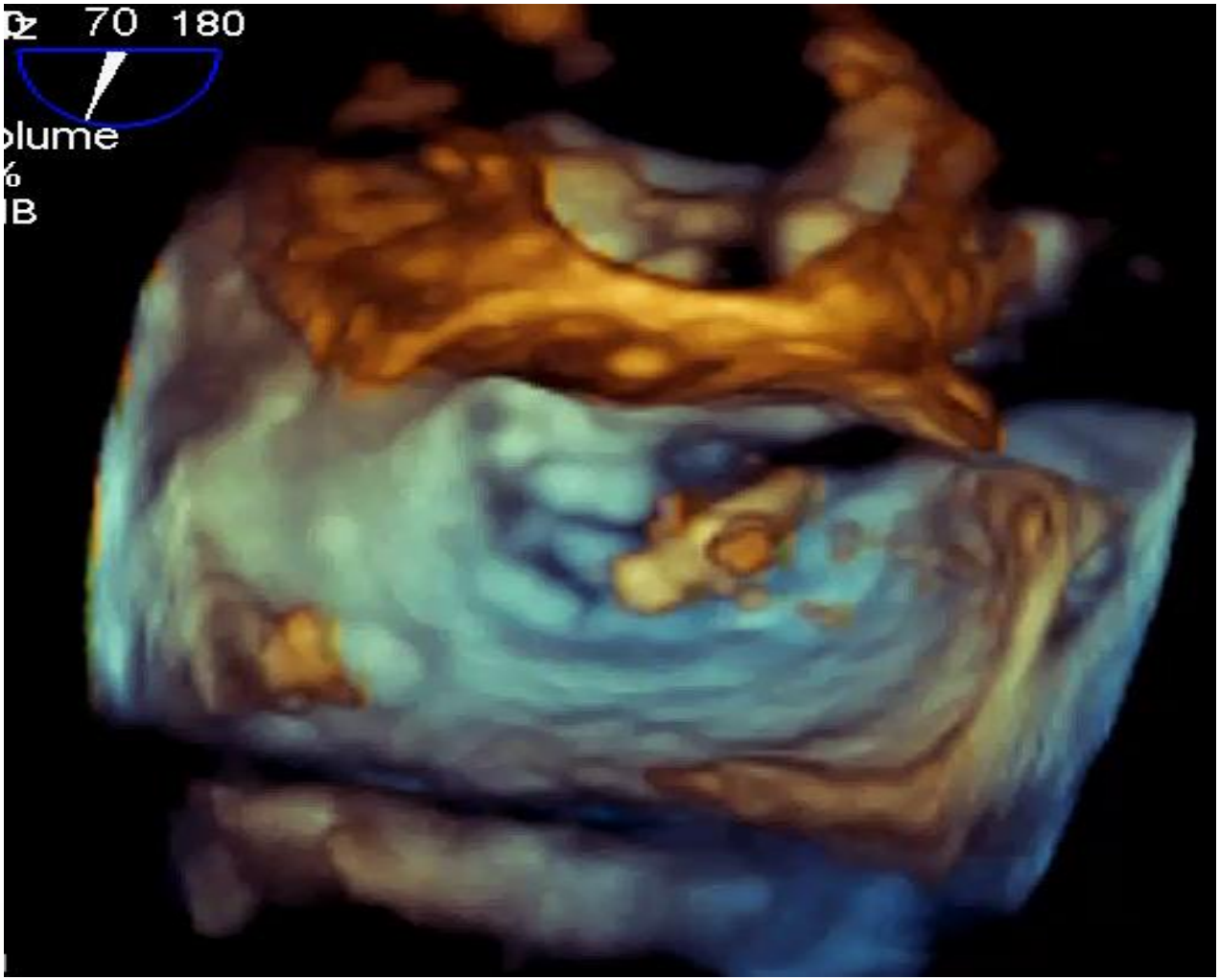

Optimizing the Clip position in relation to the mitral valve leaflets

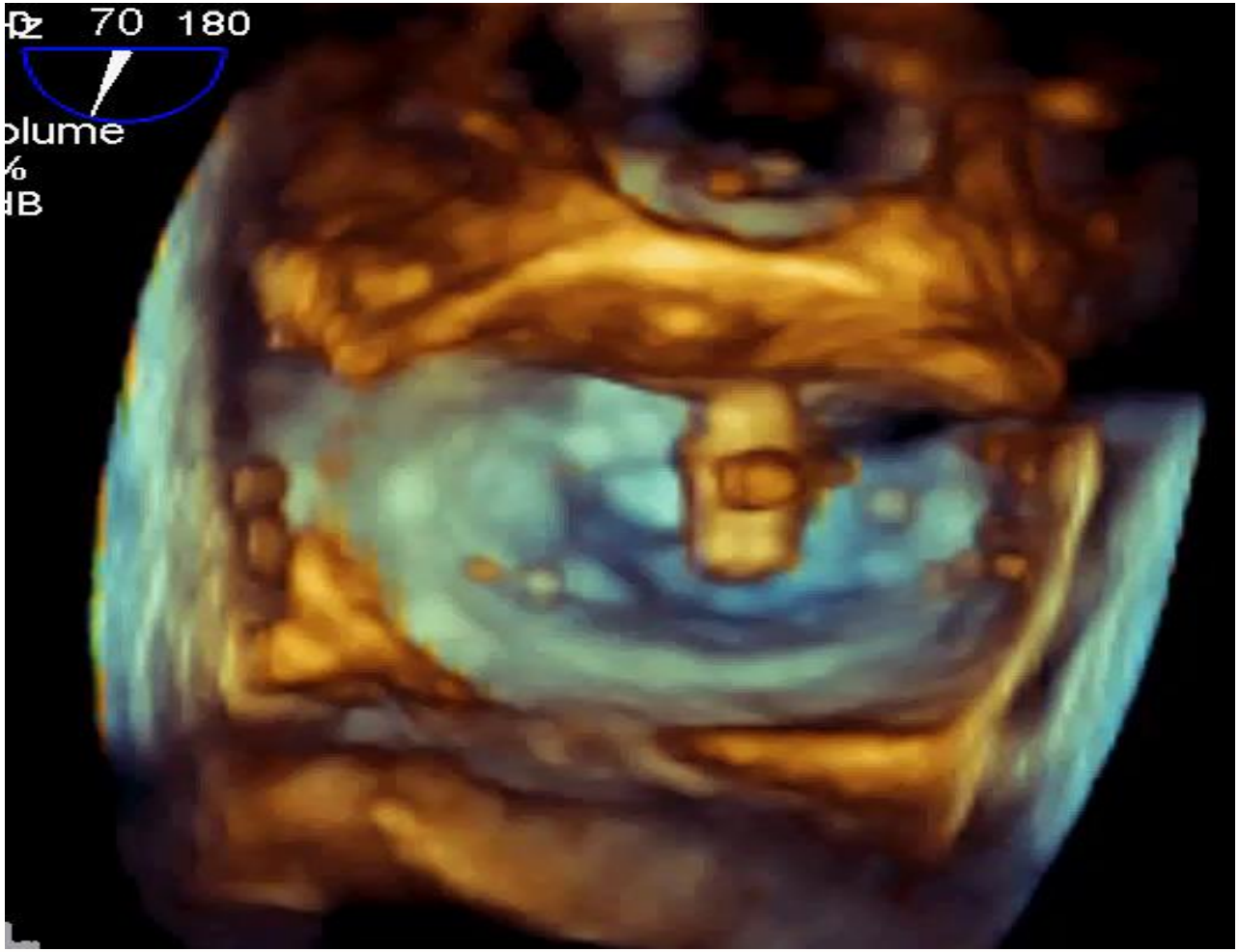

Optimizing the Clip position in relation to the mitral valve leaflets

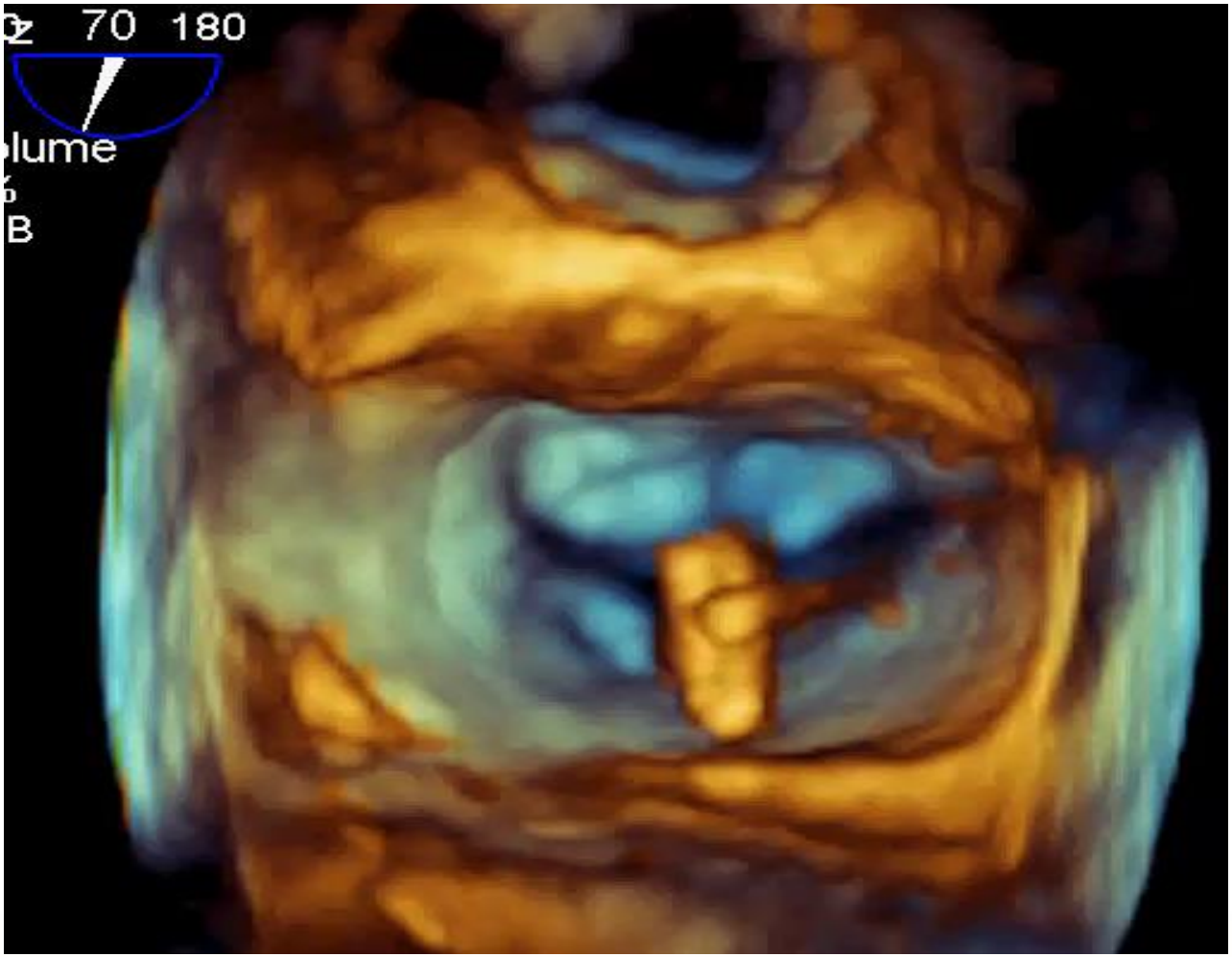

Optimizing the Clip position in relation to the mitral valve leaflets

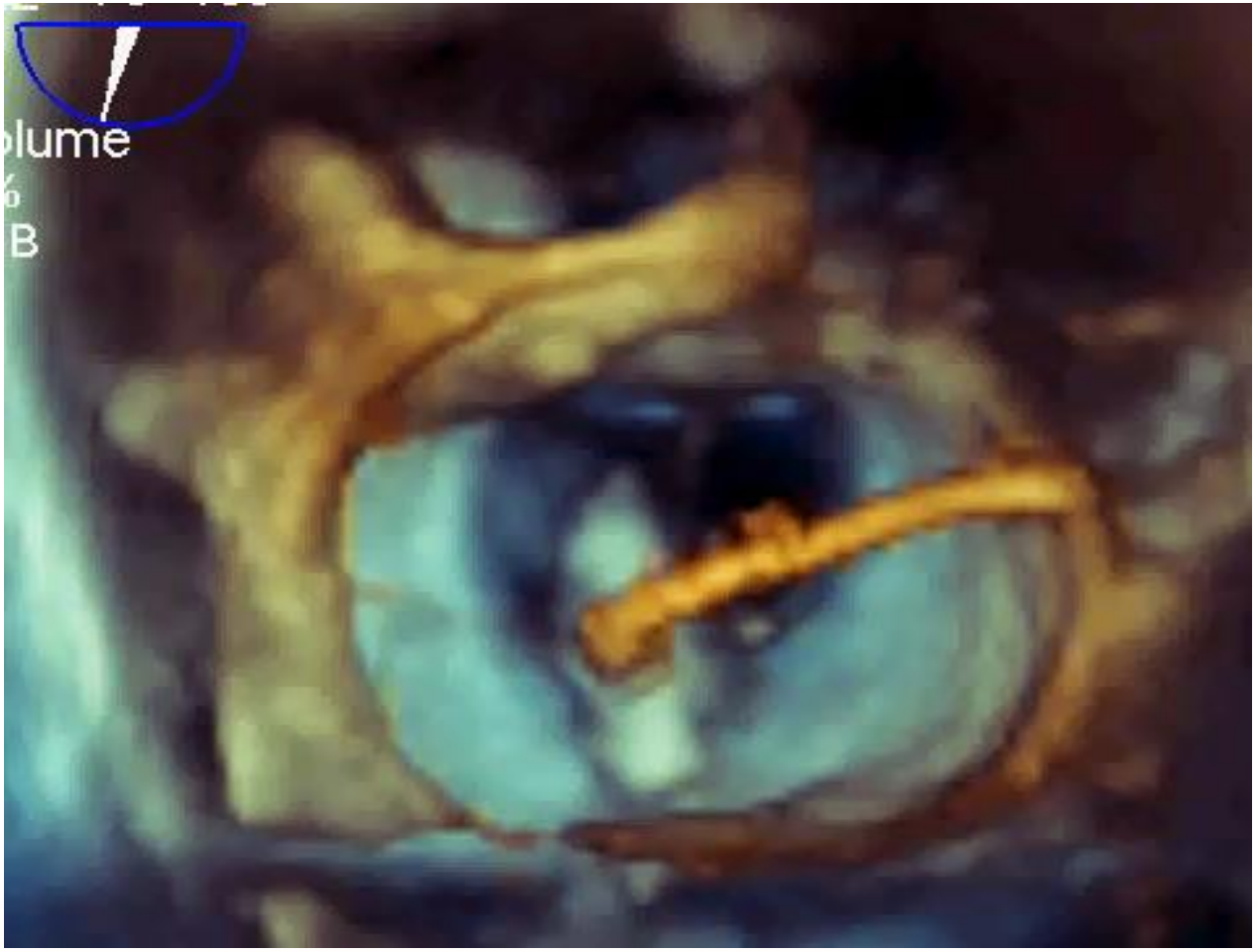

Optimizing the Clip position in relation to the mitral valve leaflets

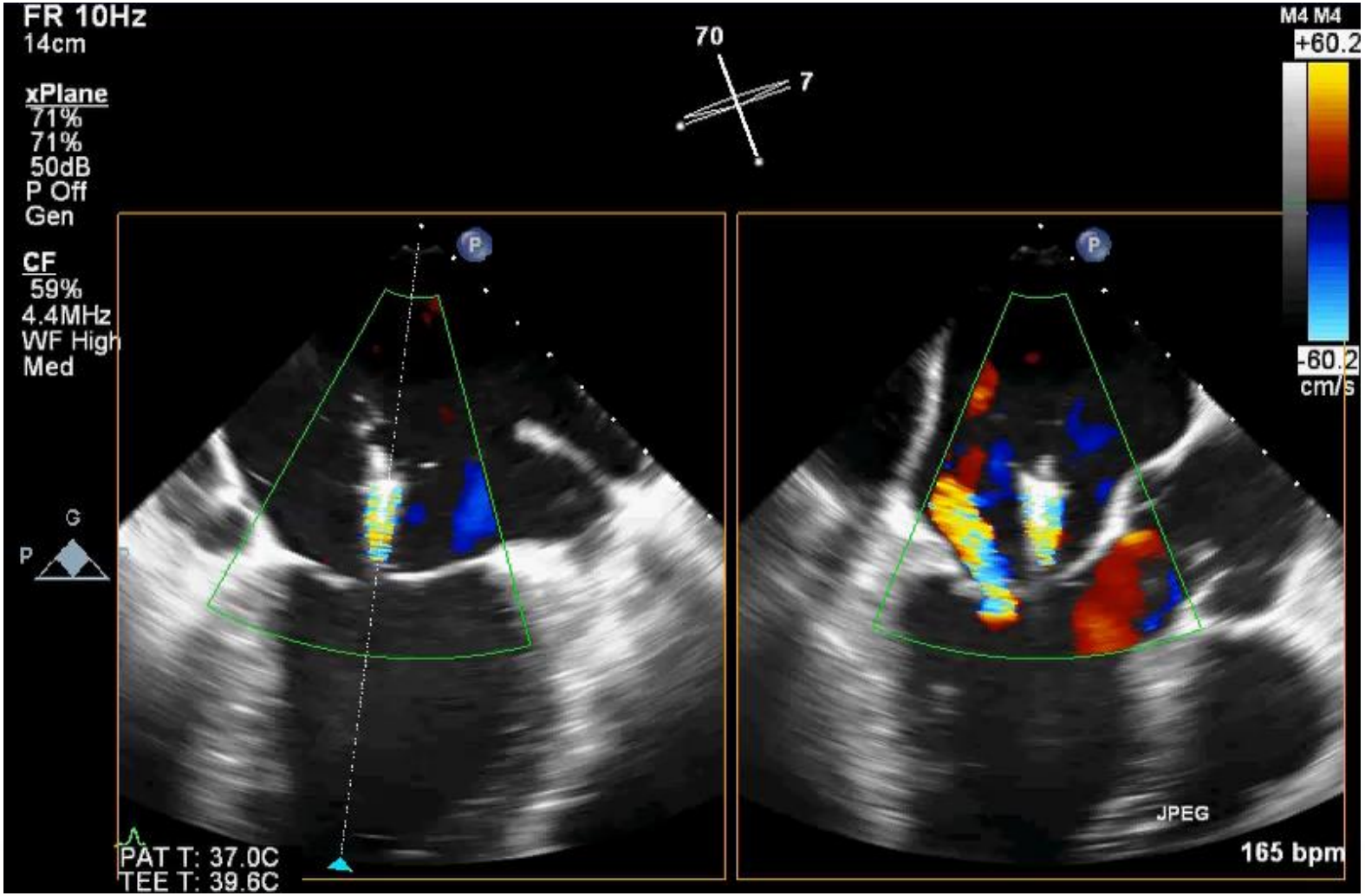

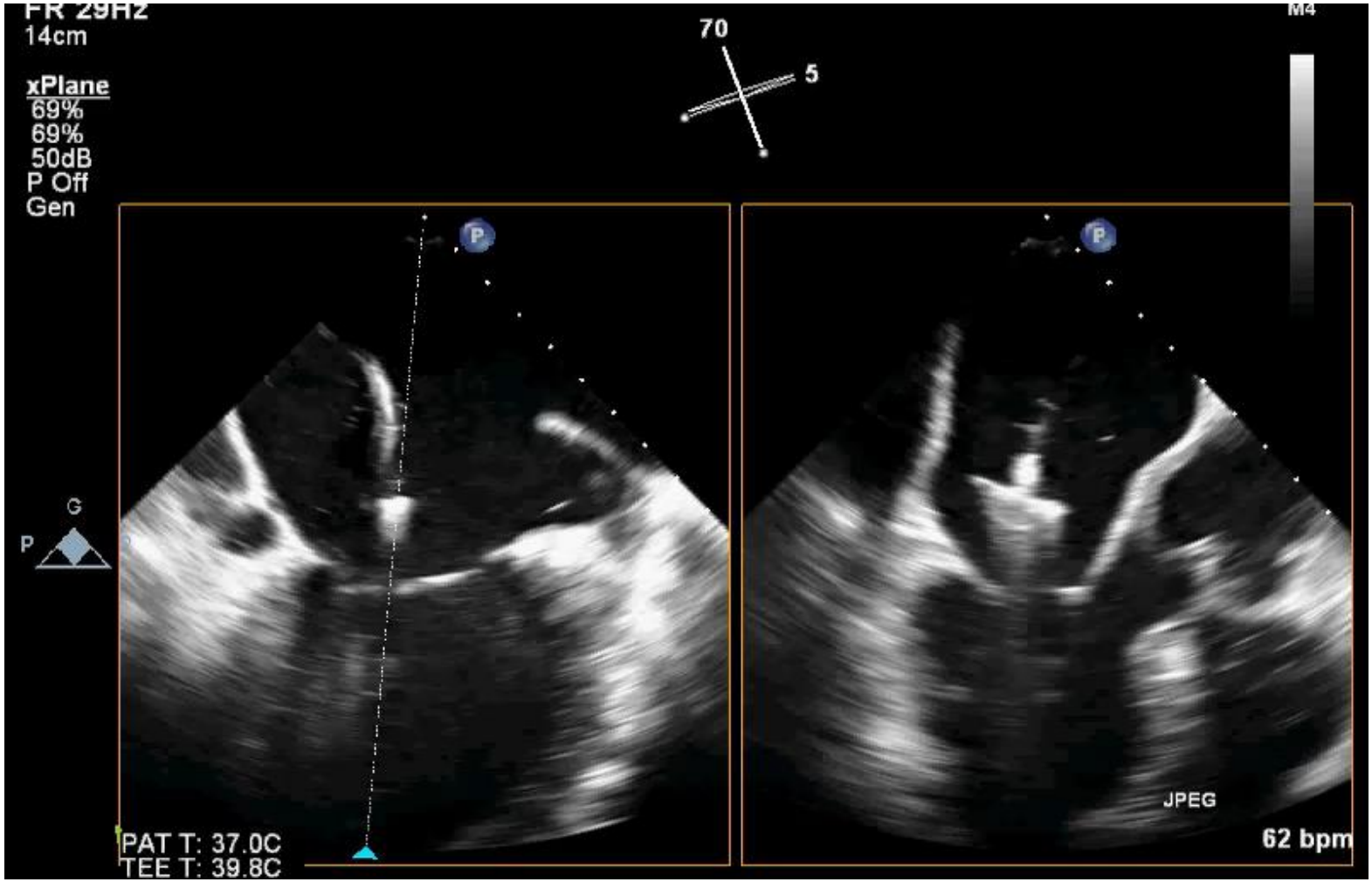
FR 29Hz
14cm
xPlane
69%
69%
50dB
P Off
Gen
70
5
M4
G
P
PAT T: 37.0C
TEE T: 39.8C
JPEG
62 bpm

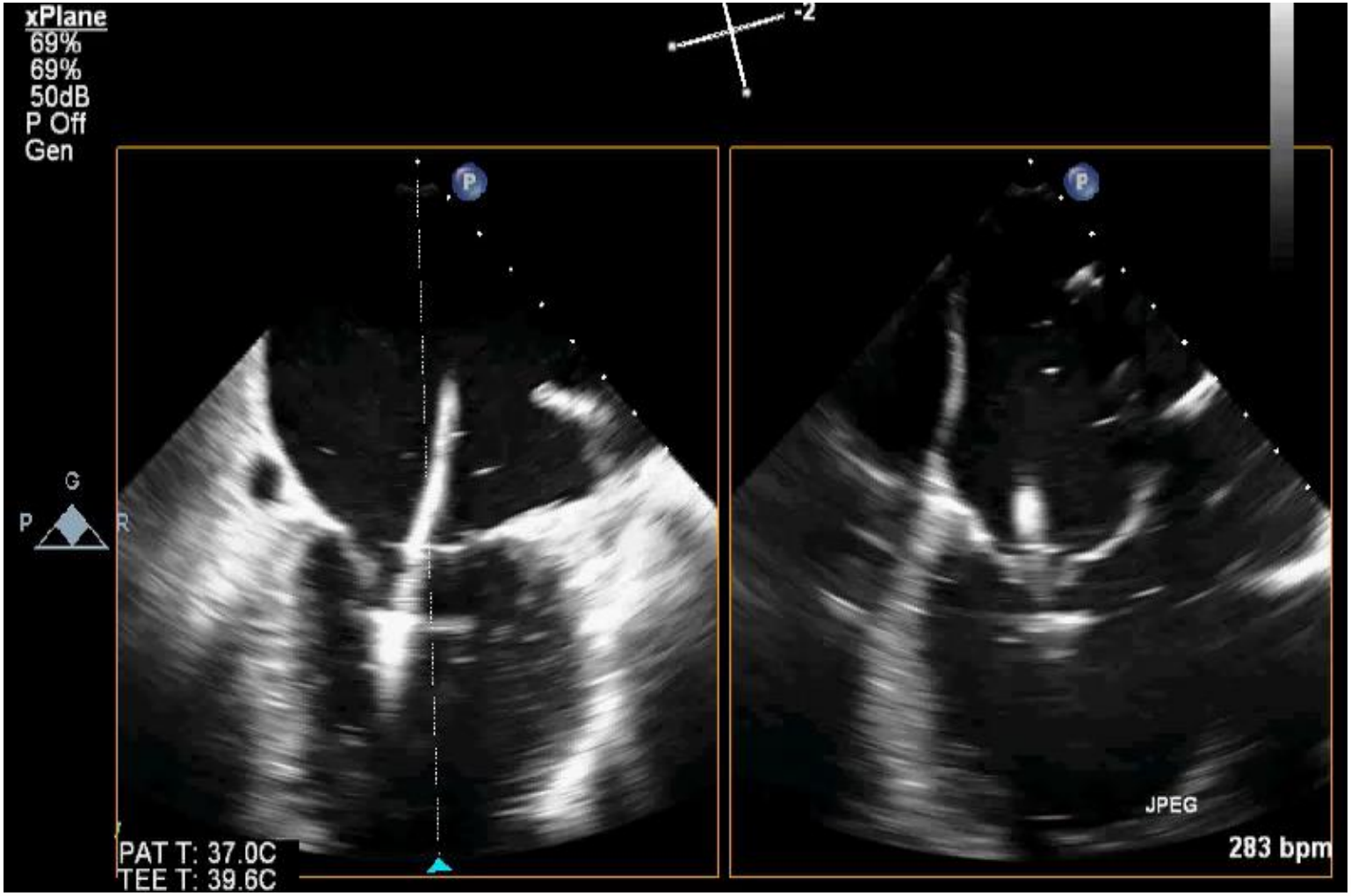
xPlane
69%
69%
50dB
P Off
Gen
-2
P
P
G
P
R
PAT T: 37.0C
TEE T: 39.6C
JPEG
283 bpm

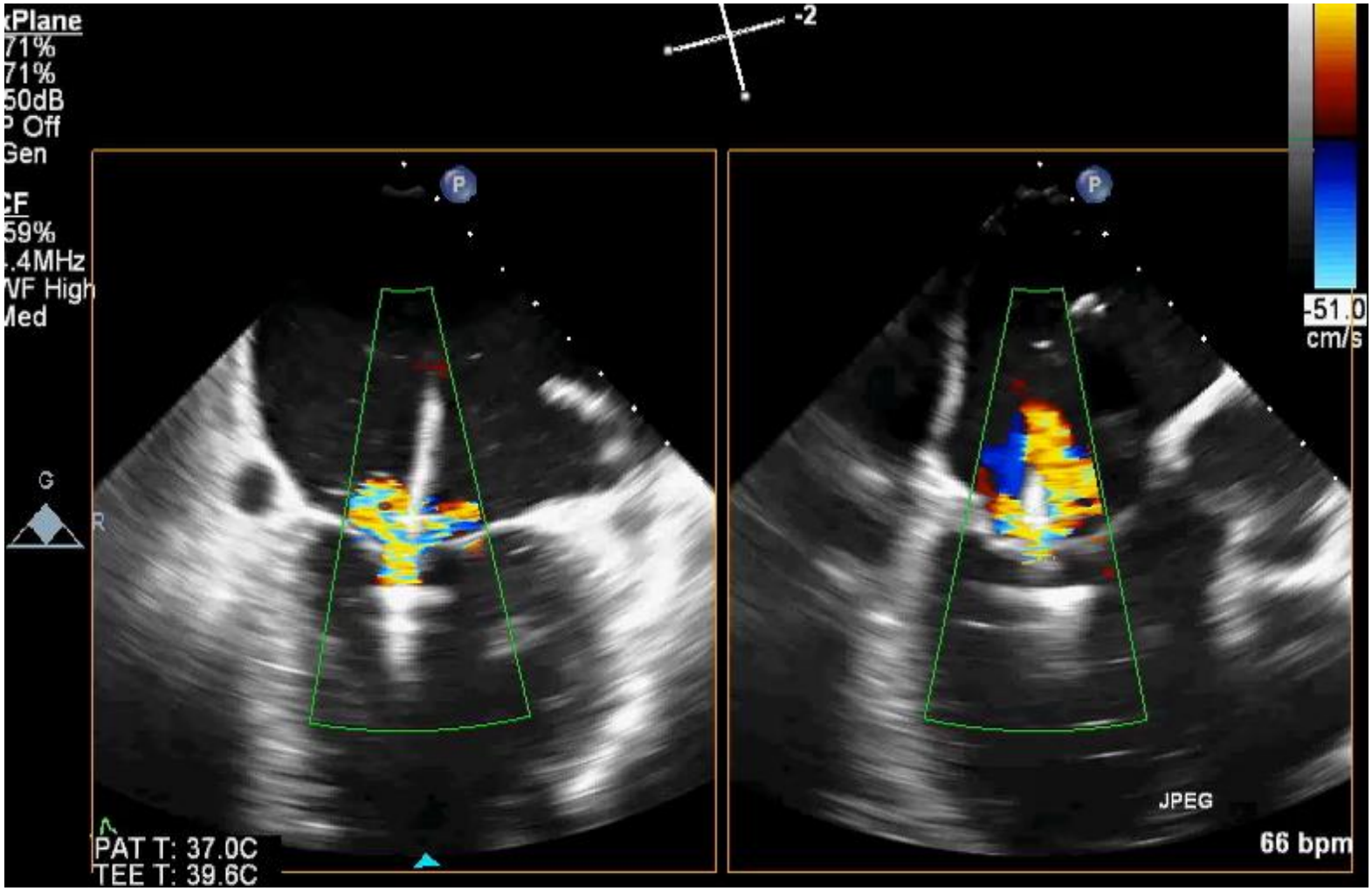
xPlane
71%
71%
50dB
P Off
Gen
CF
59%
.4MHz
VF High
Med
-2
-51.0
cm/s
G
R
P
P
JPEG
66 bpm
PAT T: 37.0C
TEE T: 39.6C

Guiding leaflet grasping

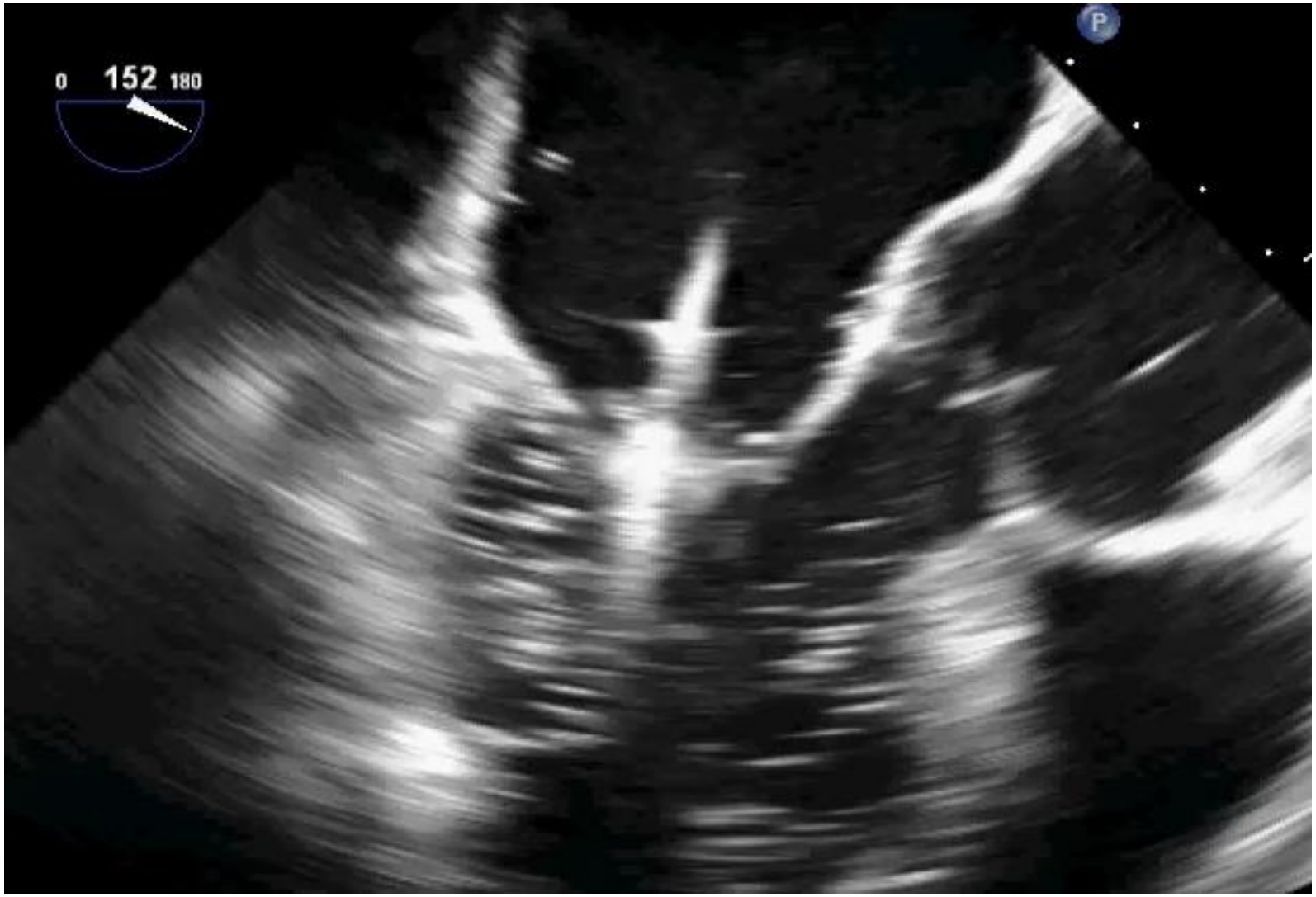

Guiding leaflet grasping

Guiding leaflet grasping

Assessment of the valve after the first clip

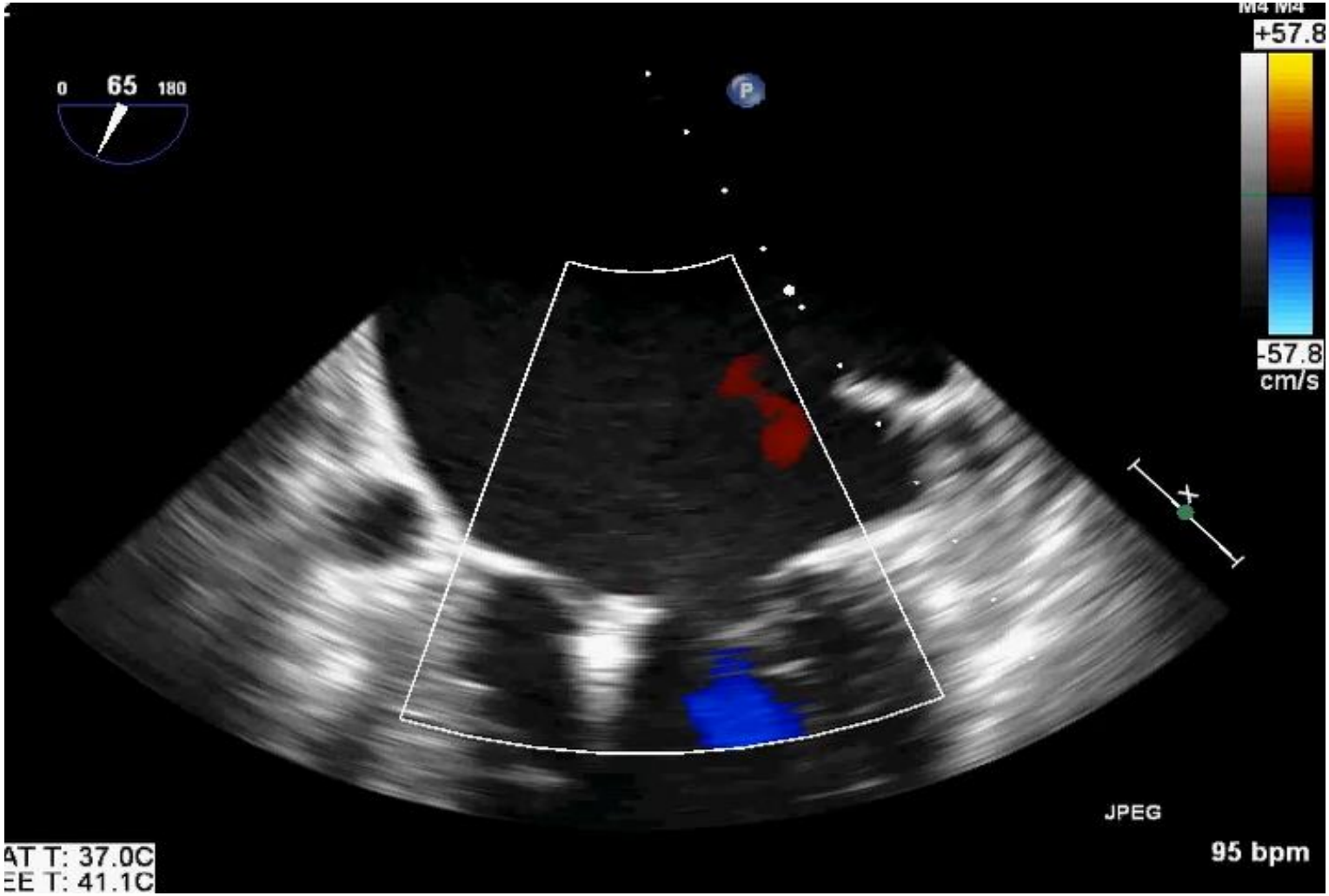

Assessment of the valve after the first clip

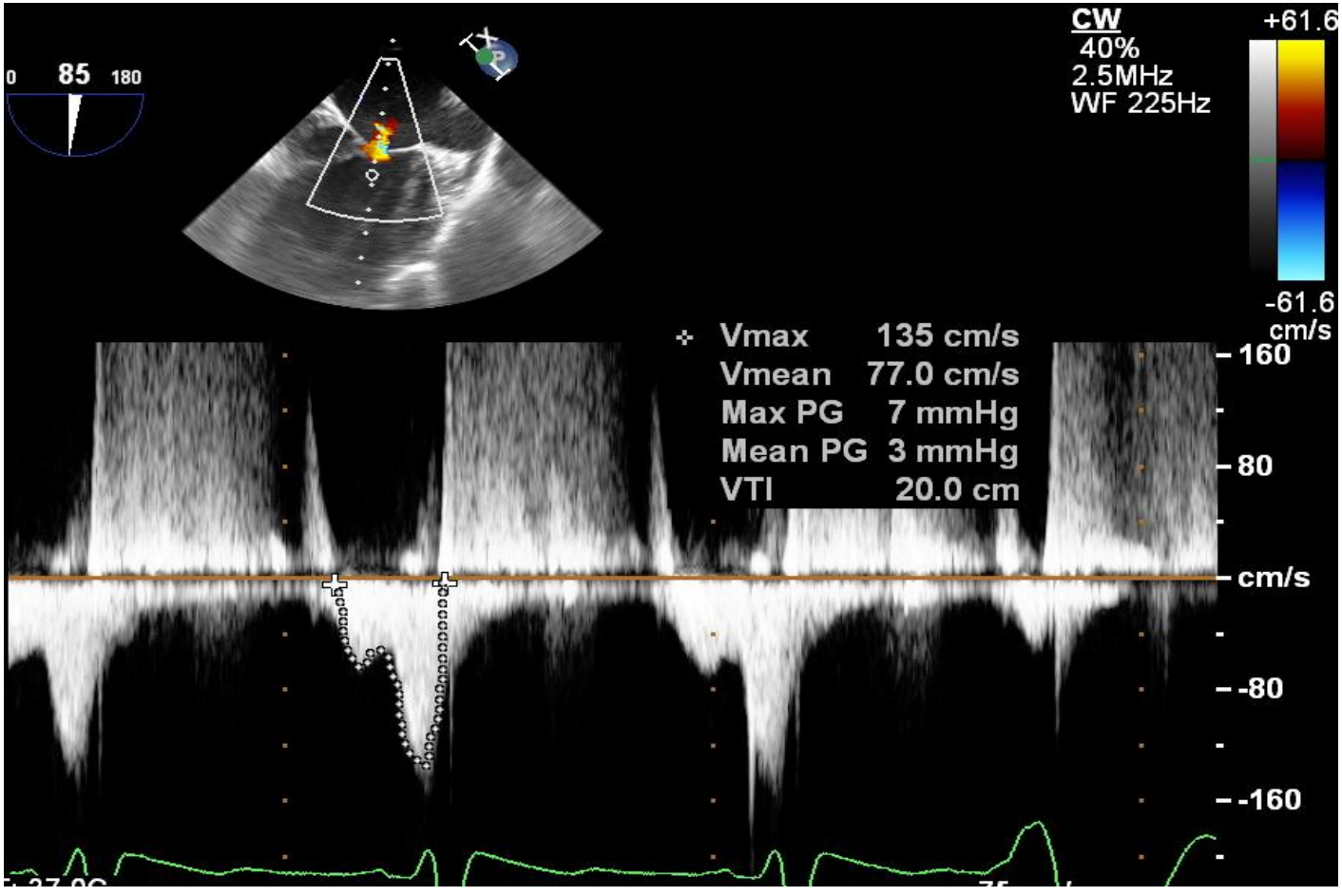

Introduction of the 2nd clip

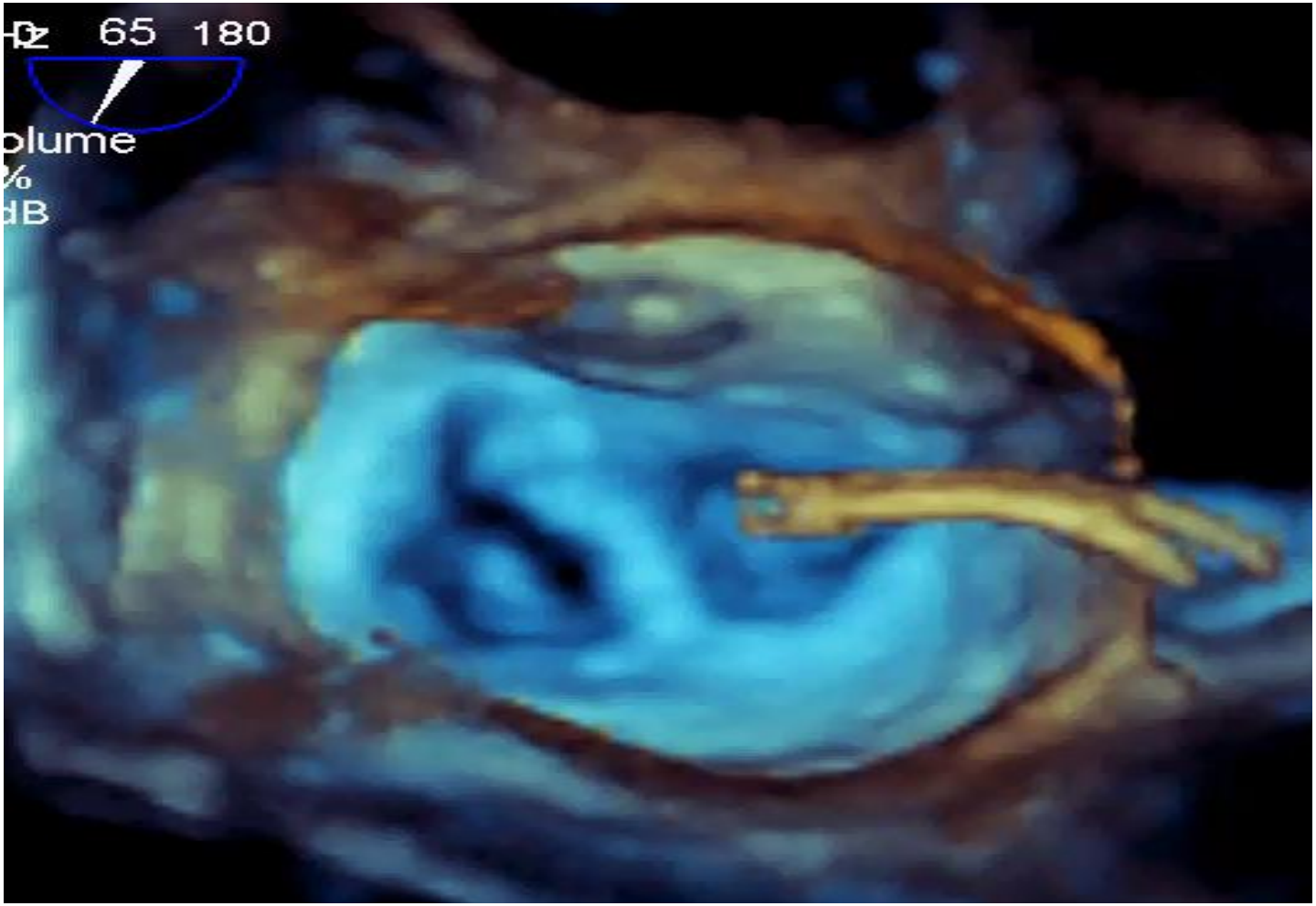

Introduction of the 2nd clip

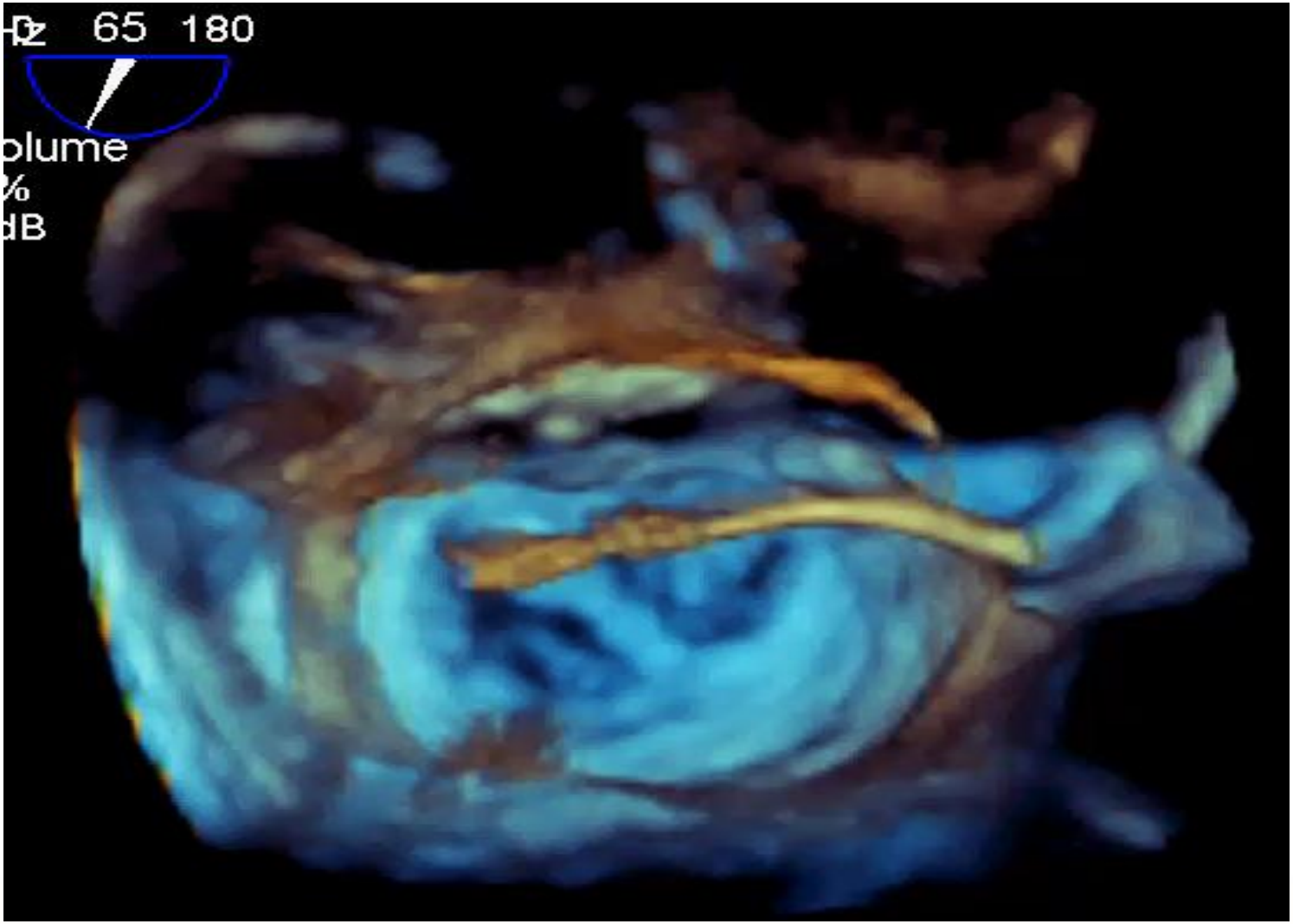

Positioning of the 2nd clip

Positioning of the 2nd clip

Assessment

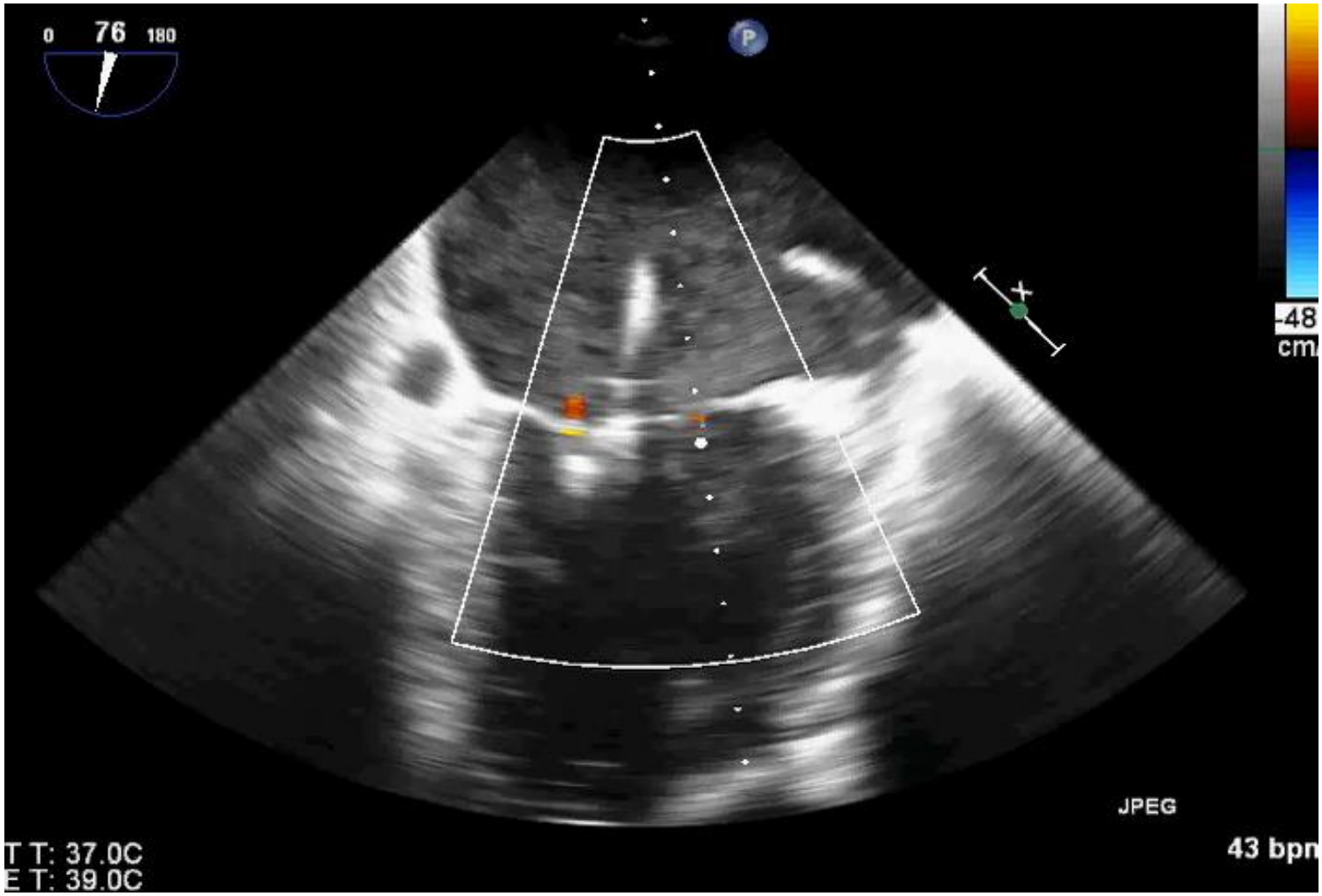

Assessment

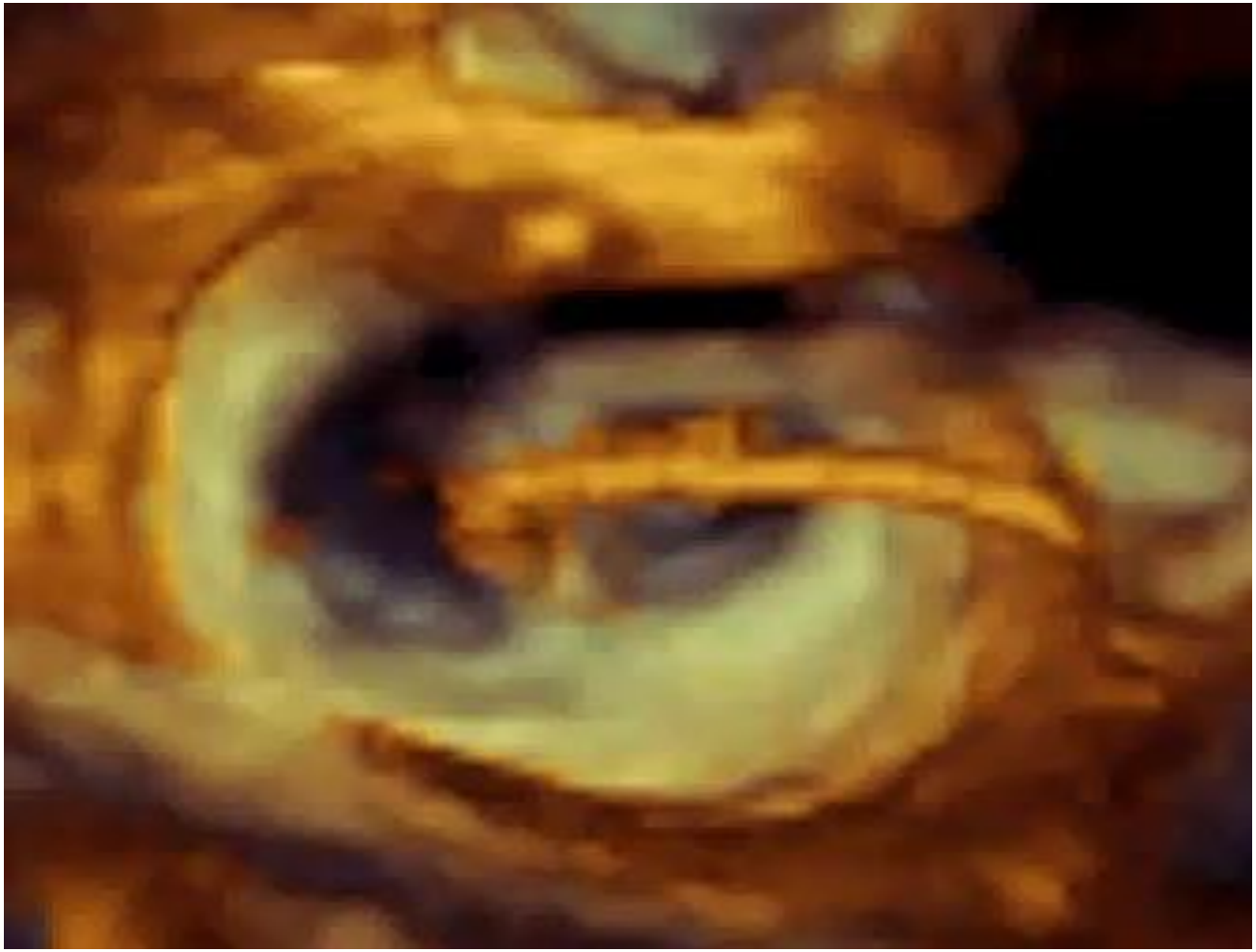

releasing the 2nd clip

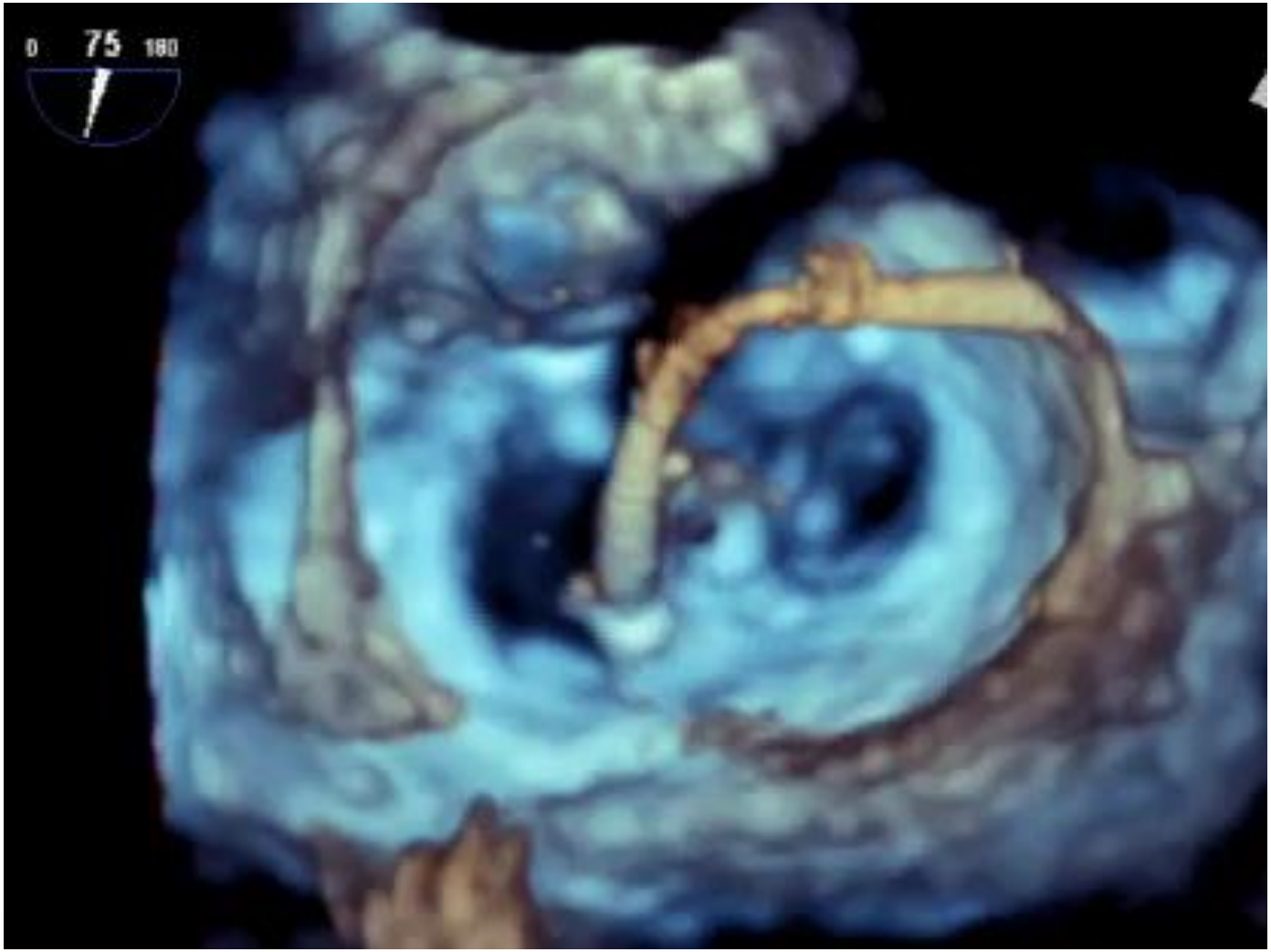

Assessment

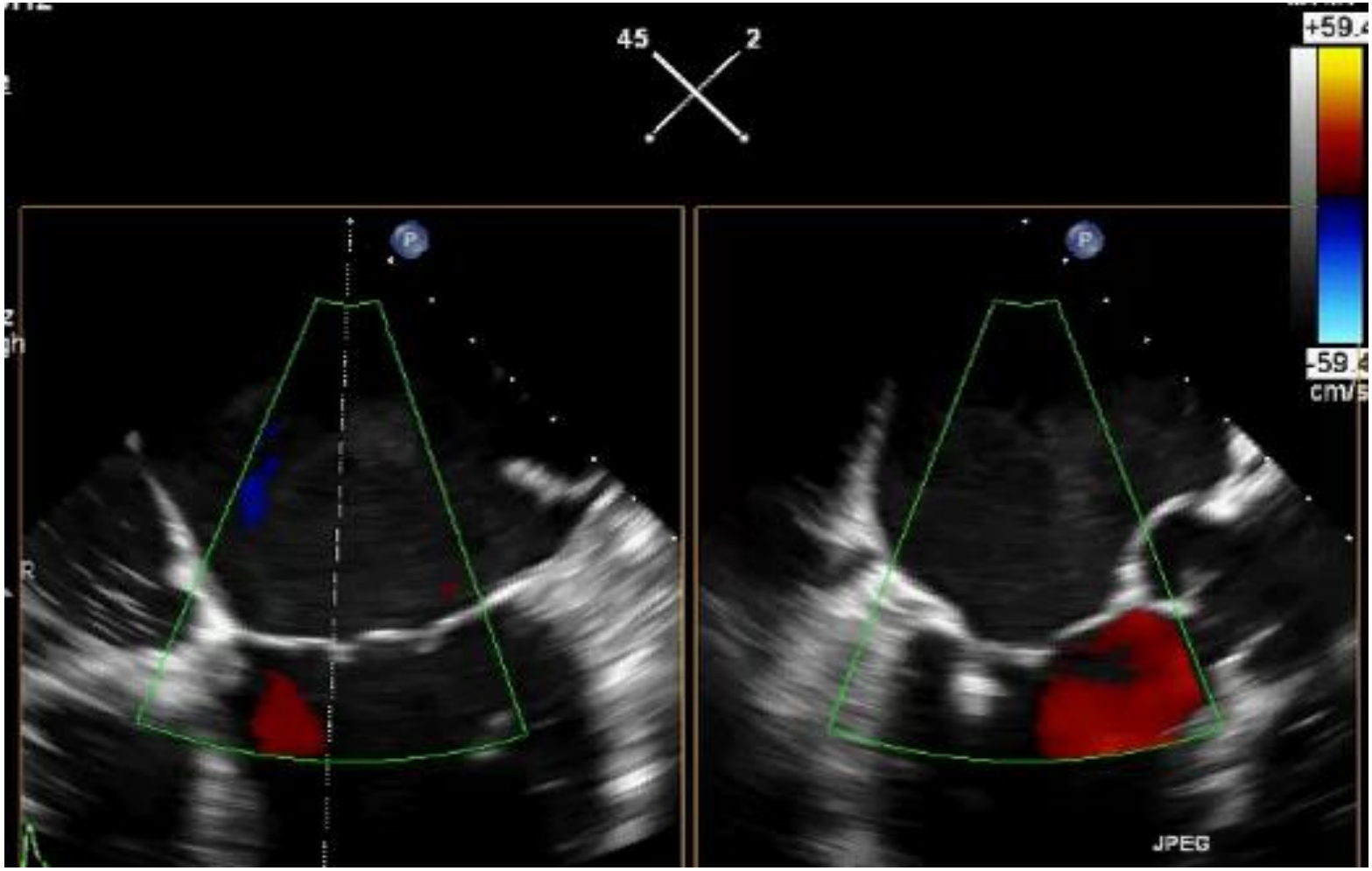

Assessment

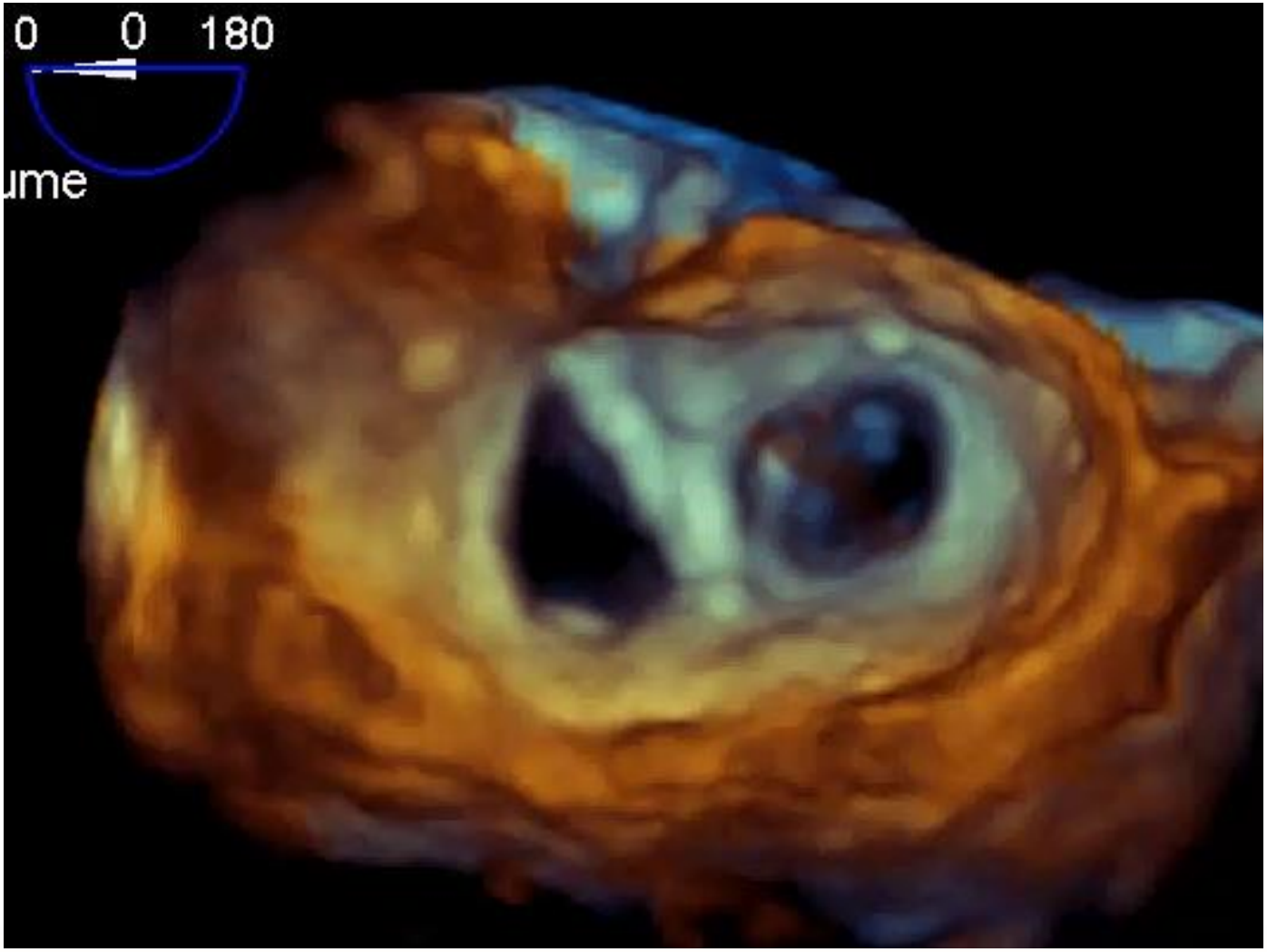

Assessment

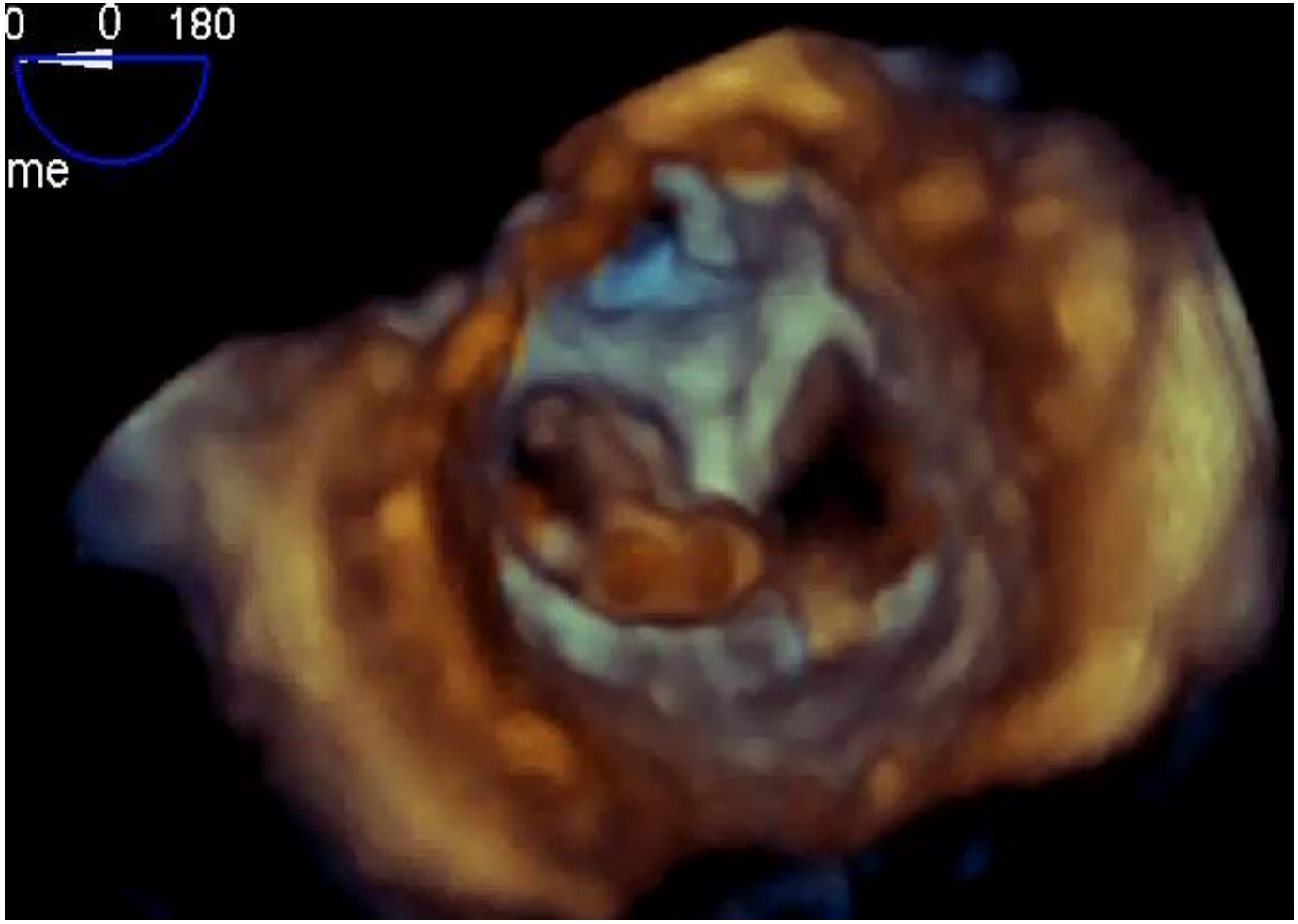

Assessment

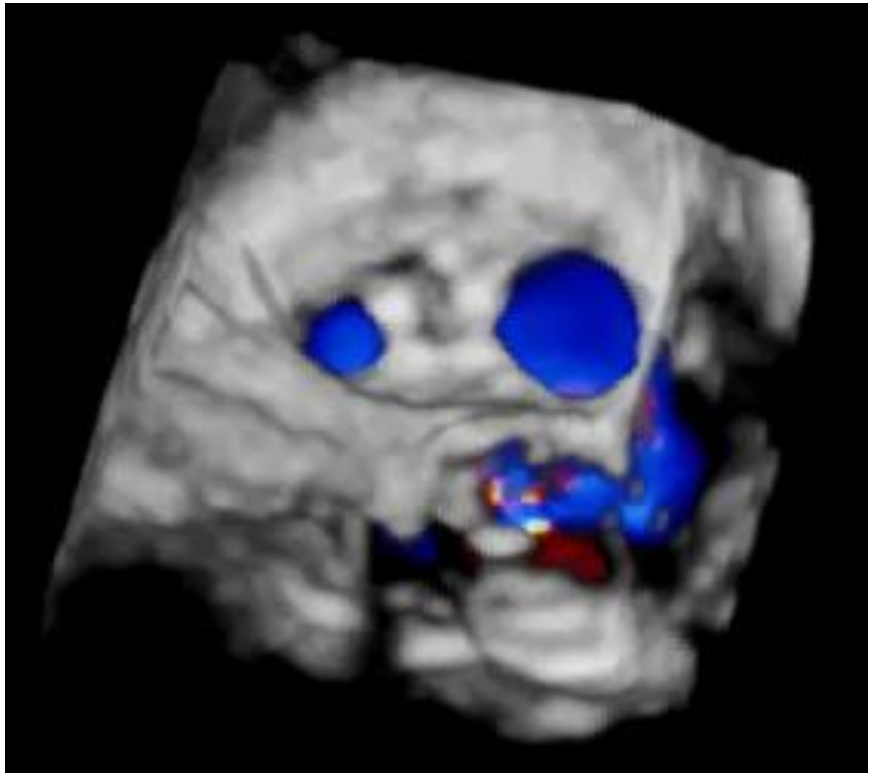

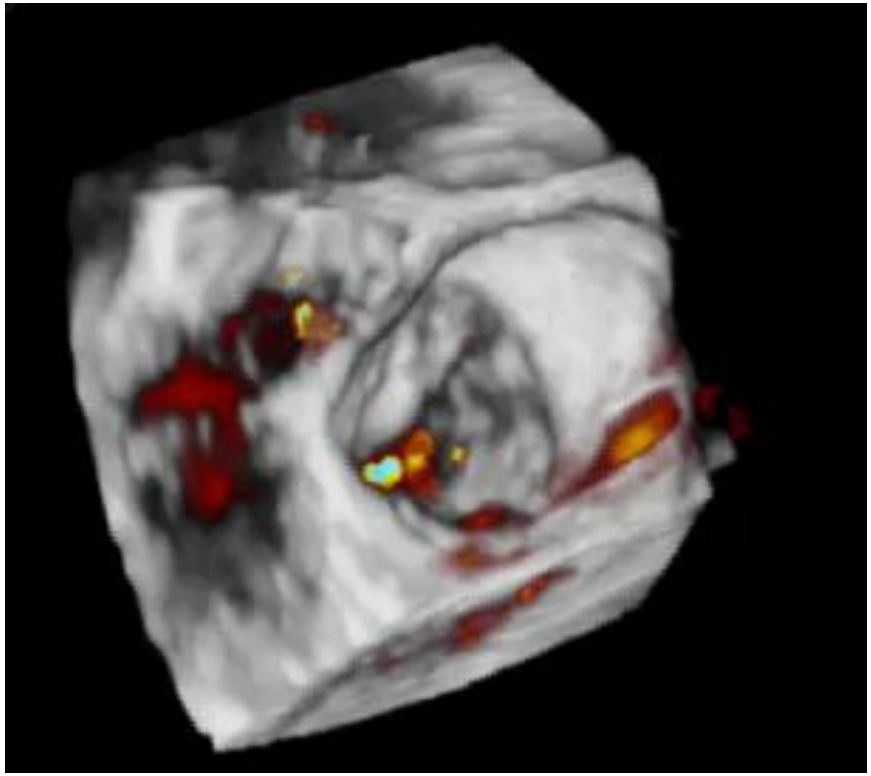

Conclusion

- ✓ **Three-dimensional TOE has an incremental role during MitraClip percutaneous therapy.**
- ✓ **It can create a common language between the echocardiologist & the interventionist through providing anatomically oriented views.**
- ✓ **It really saves time, can reduce the radiation exposure "fluoroscopy time".**
- ✓ **It reduces the need to get trans-gastric 2D-TEE views.**

CIC

مركز فحوصات القلب

CARDIAC INVESTIGATION CENTER

www.ciceg.net