ASD/PFO and LAA

Dr. Hani Mahmoud-Elsayed

MBBCh, MSc, MD, FESC, FASE, FEACVI

Consultant cardiologist, Director of Echocardiography Lab
Aswan Heart Centre, Magdi Yacoub Foundation, Egypt

CIC
مركز فحوصات القلب
CARDIAC INVESTIGATION CENTER

HIT
EACVI's Heart Imagers of Tomorrow

EACVI
EUROPEAN ASSOCIATION OF CARDIOVASCULAR IMAGING

EUROPEAN SOCIETY OF CARDIOLOGY®

Disclosure

- ***All members of the Faculty have provided a declaration of potential or actual All members conflict of interest''***

ASD & PFO

- **Atrial septal communications account for approximately 6%–10% of congenital heart defects, with an incidence of 1 in 1,500 live births.**

- **The patent foramen ovale (PFO) is more common and is present in greater than 20%–25% of adults.**

ASD & PFO

- **A thorough echocardiographic evaluation of PFO and ASD includes**
- **the detection and quantification of:**
  - ✓ The size and shape of the septal defects
  - ✓ The rims of tissue surrounding the defect
  - ✓ The degree and direction of shunting
  - ✓ The remodeling and changes in size and function of the cardiac chambers and pulmonary circulation

ASD & PFO

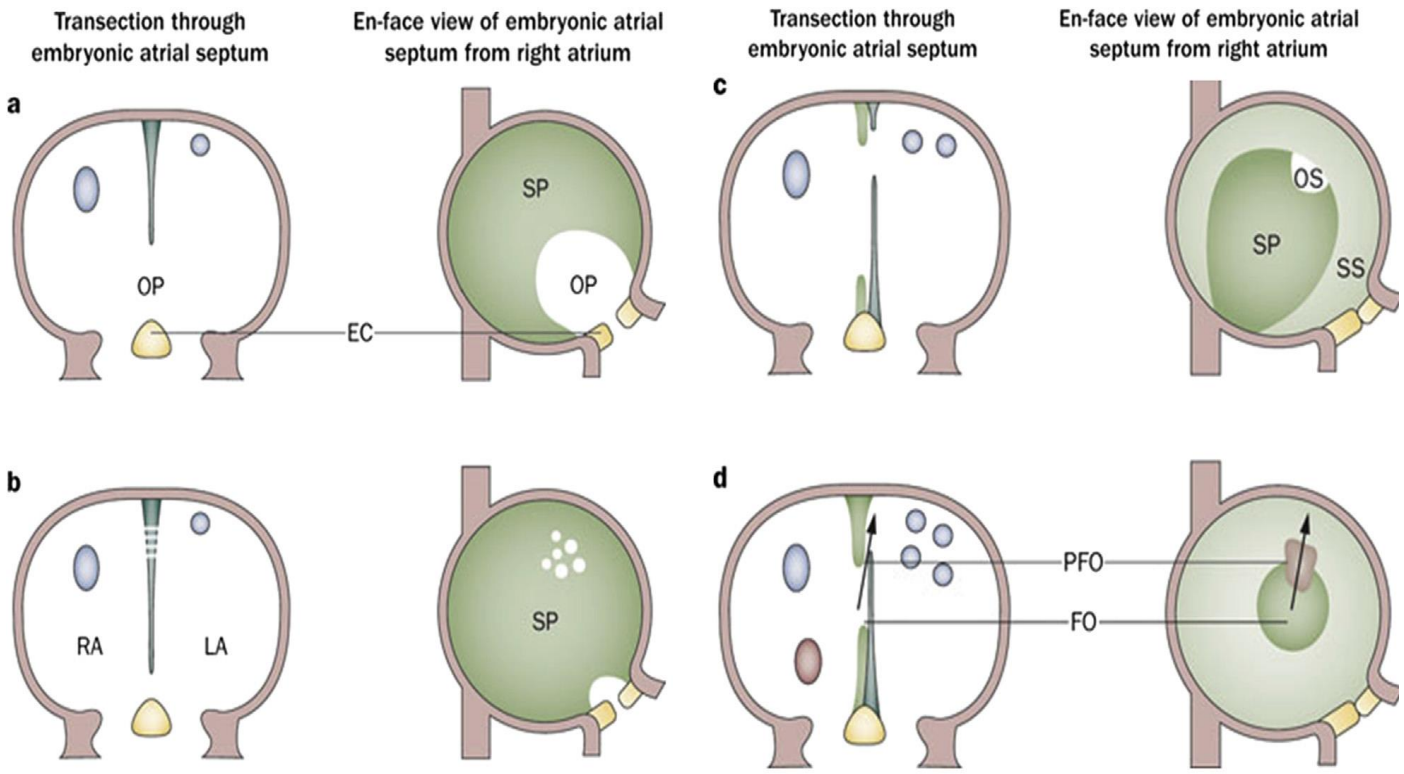

Silvestry FE et al. J Am Soc Echocardiogr. 2015;28:910-58

ASD & PFO

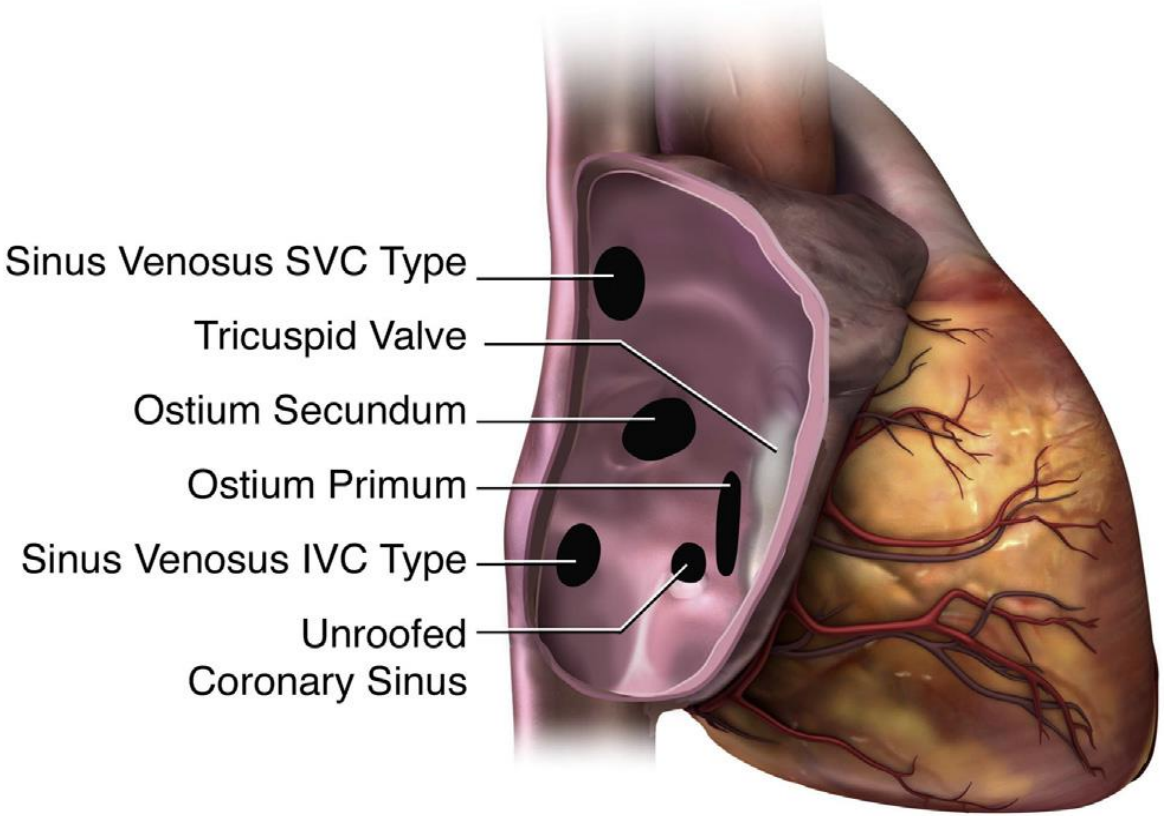

Silvestry FE et al. J Am Soc Echocardiogr. 2015;28:910-58

Patent Foramen Ovale
PFO

PFO

- A (PFO) is <u>not</u> a true deficiency of atrial septal tissue but rather a potential space or separation between the septum primum and septum secundum located in the anterosuperior portion of the atrial septum

- It is not considered a true ASD, because no structural deficiency of the atrial septal tissue is present.

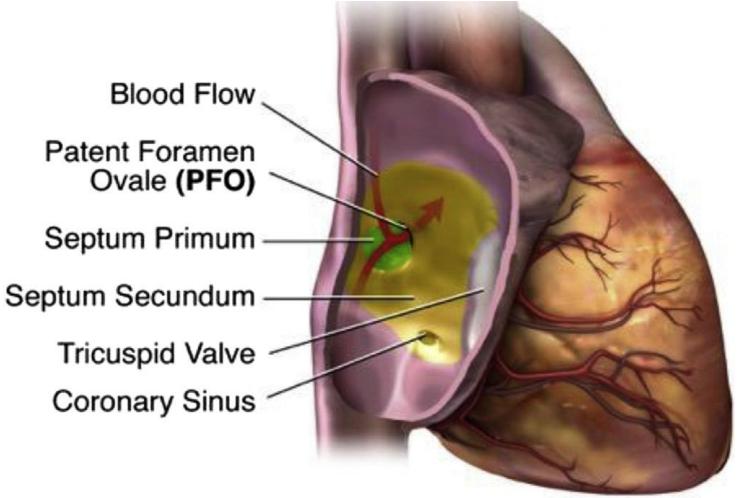

Silvestry FE et al. J Am Soc Echocardiogr. 2015;28:910-58

PFO

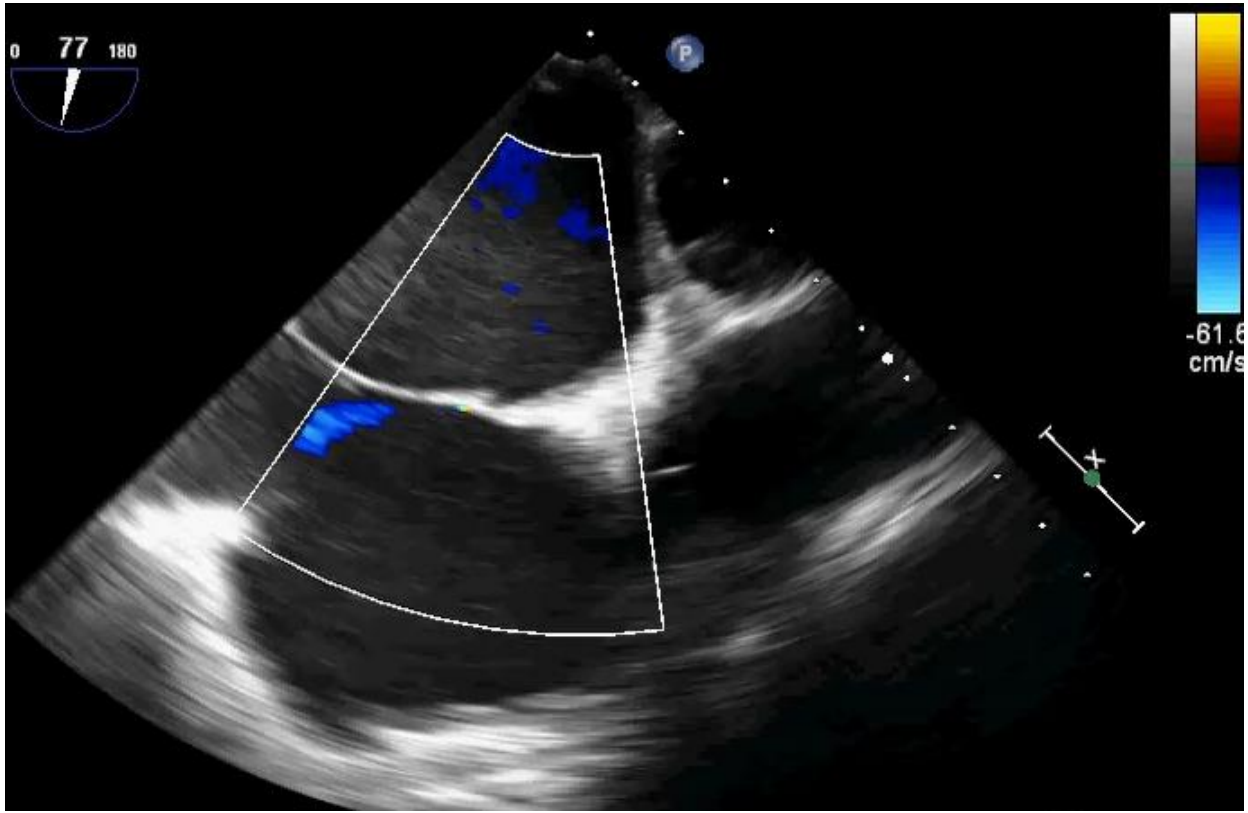

PFO

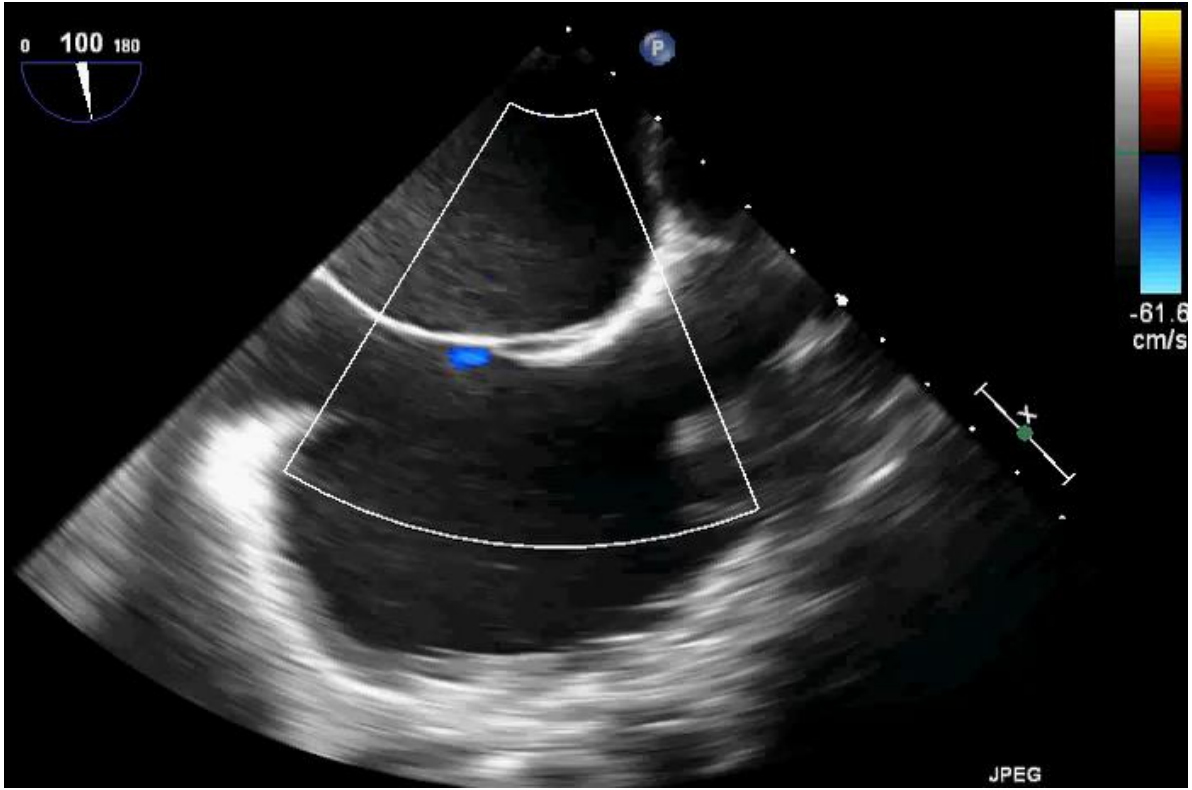

PFO

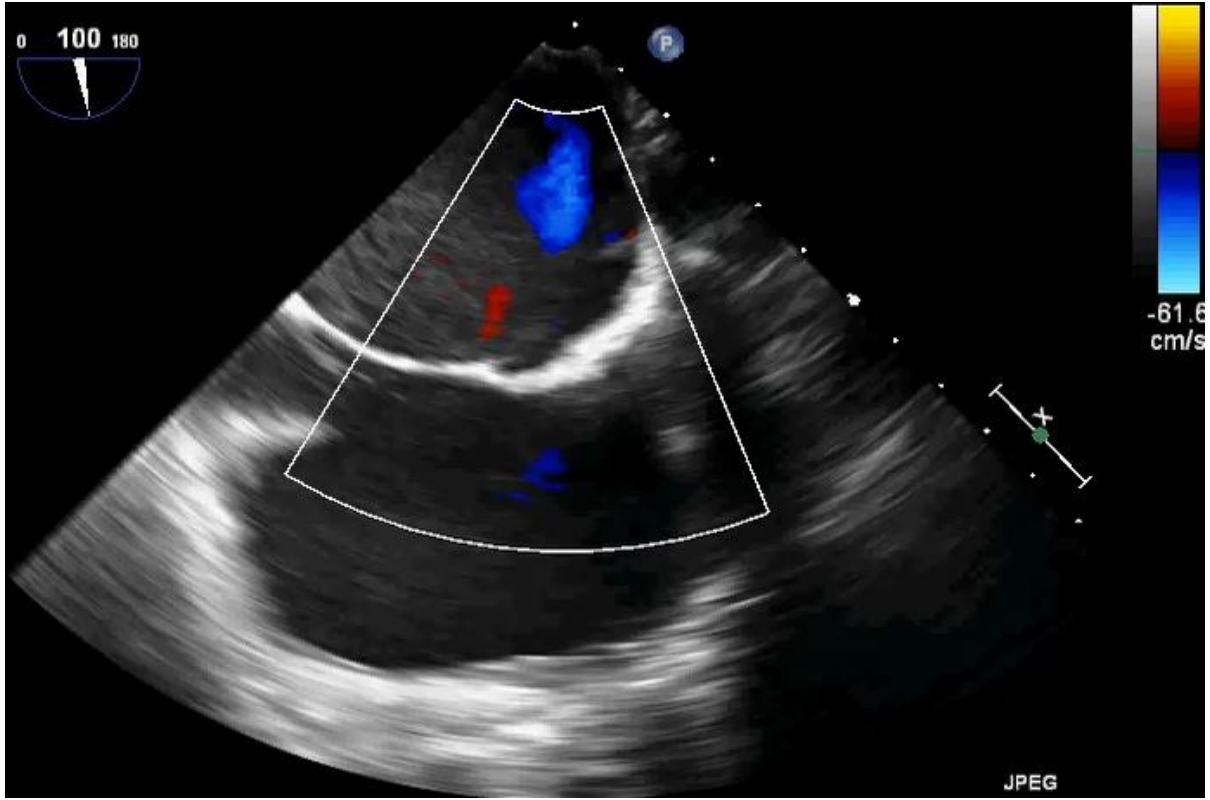

PFO

PFO

Ostium secondum ASD

Ostium secondum ASD

- An ostium secundum ASD most often occurs as the result of a true deficiency of septum primum tissue

- It is the most common form of a true ASD

- The superior and posterior margins of the defect are composed of the septum secundum, the anterior margin is composed of the AV canal septum, and the inferior margin is composed of the septum primum and left venous valve of the inferior vena cava

Ostium secondum ASD

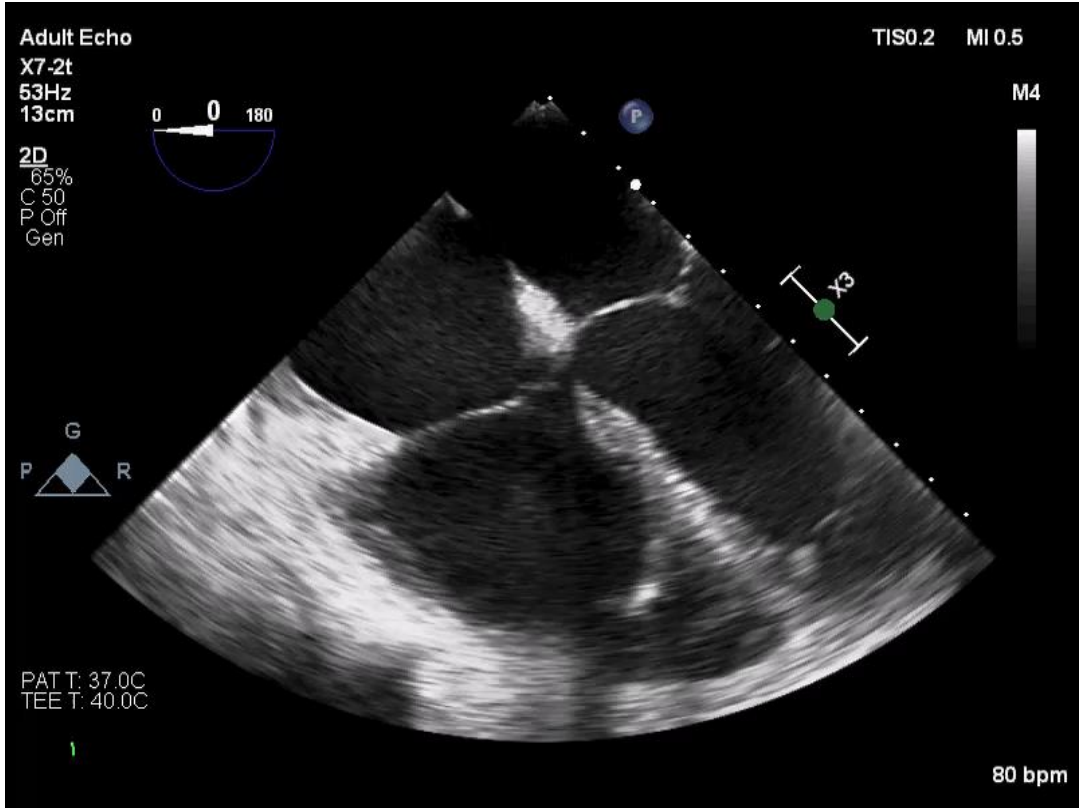

2D TOE imaging protocol

0 Degrees (Up & down)

90 Degrees (side to side)

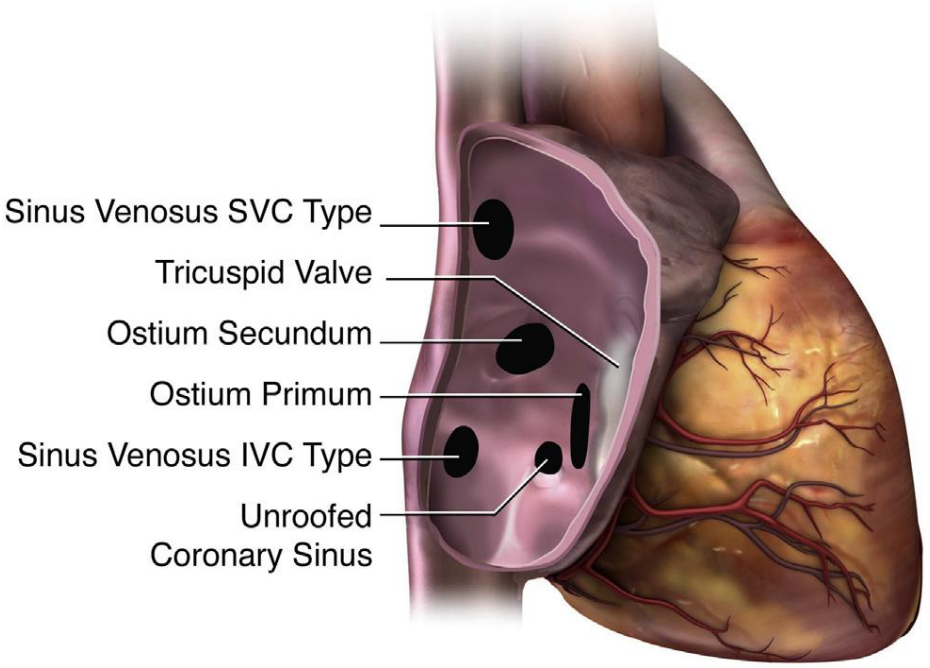

Ostium secondum ASD

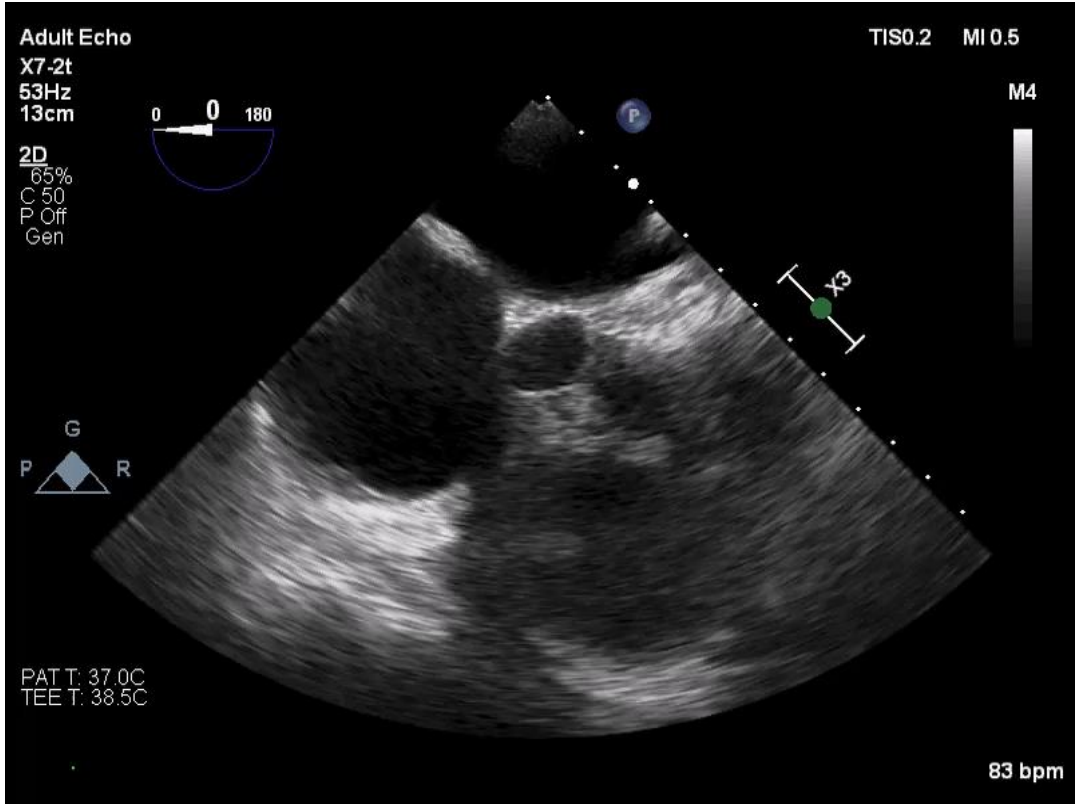

Ostium secondum ASD

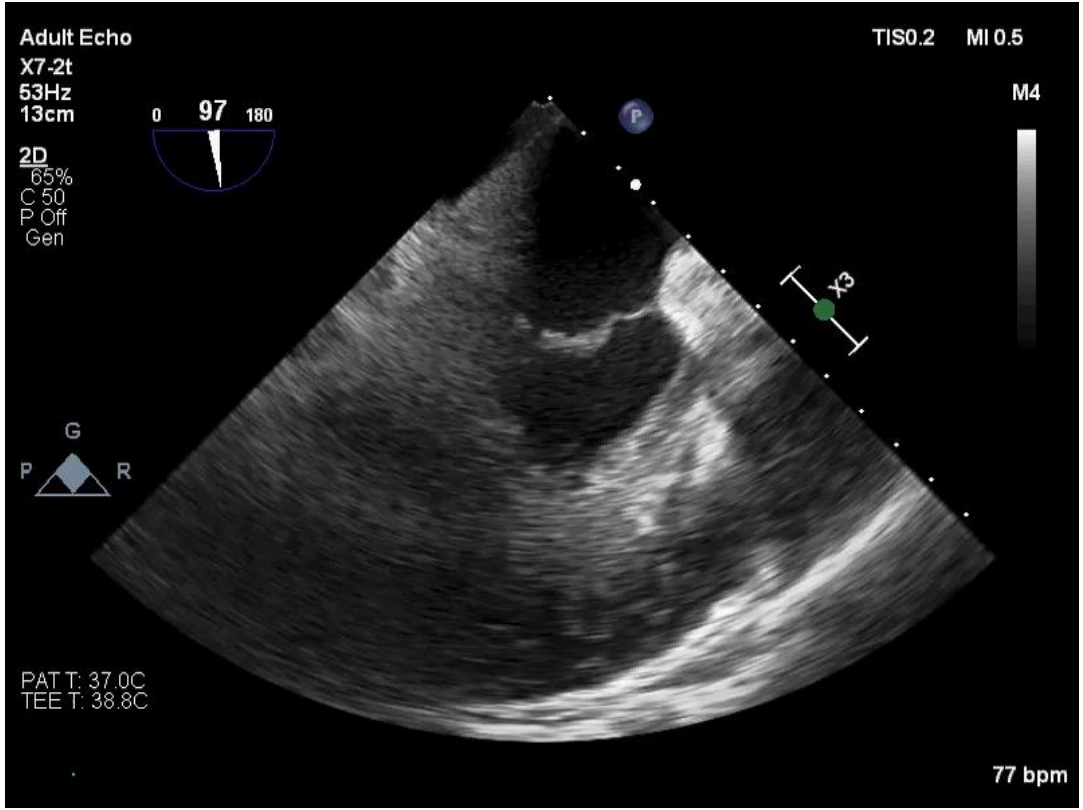

Ostium secondum ASD

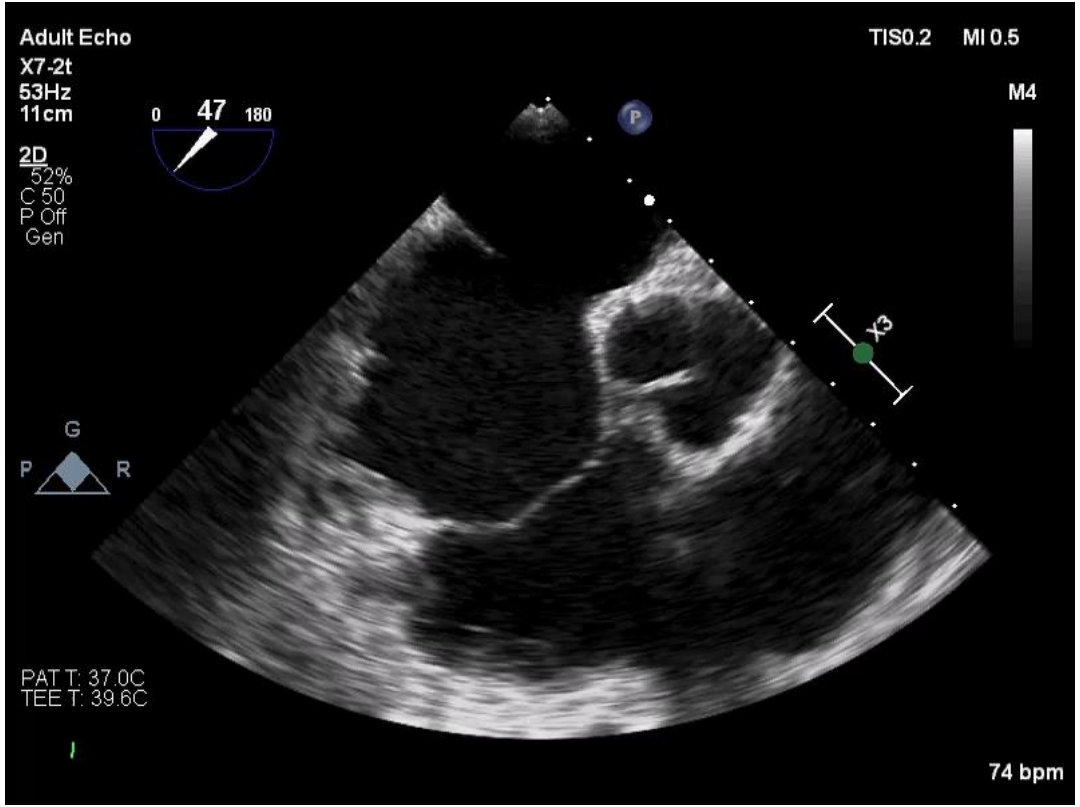

Ostium secondum ASD

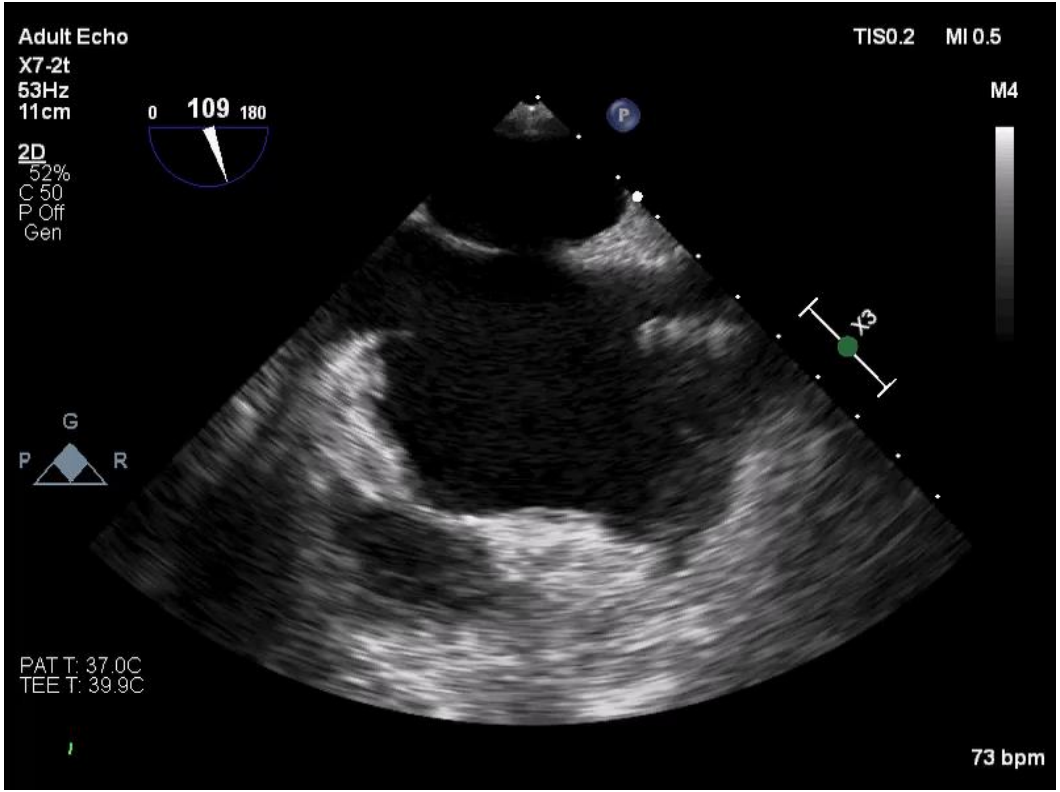

Imaging of the inter-atrial septum

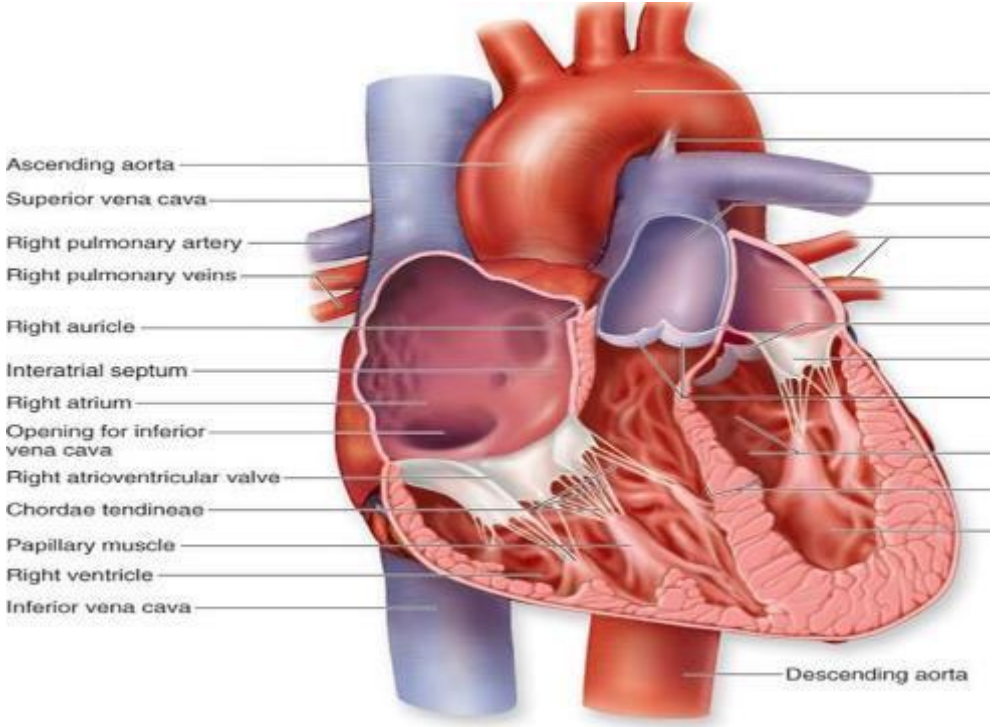

RATLe-90 maneuver

Imaging of the inter-atrial septum
RATLe-90 maneuver

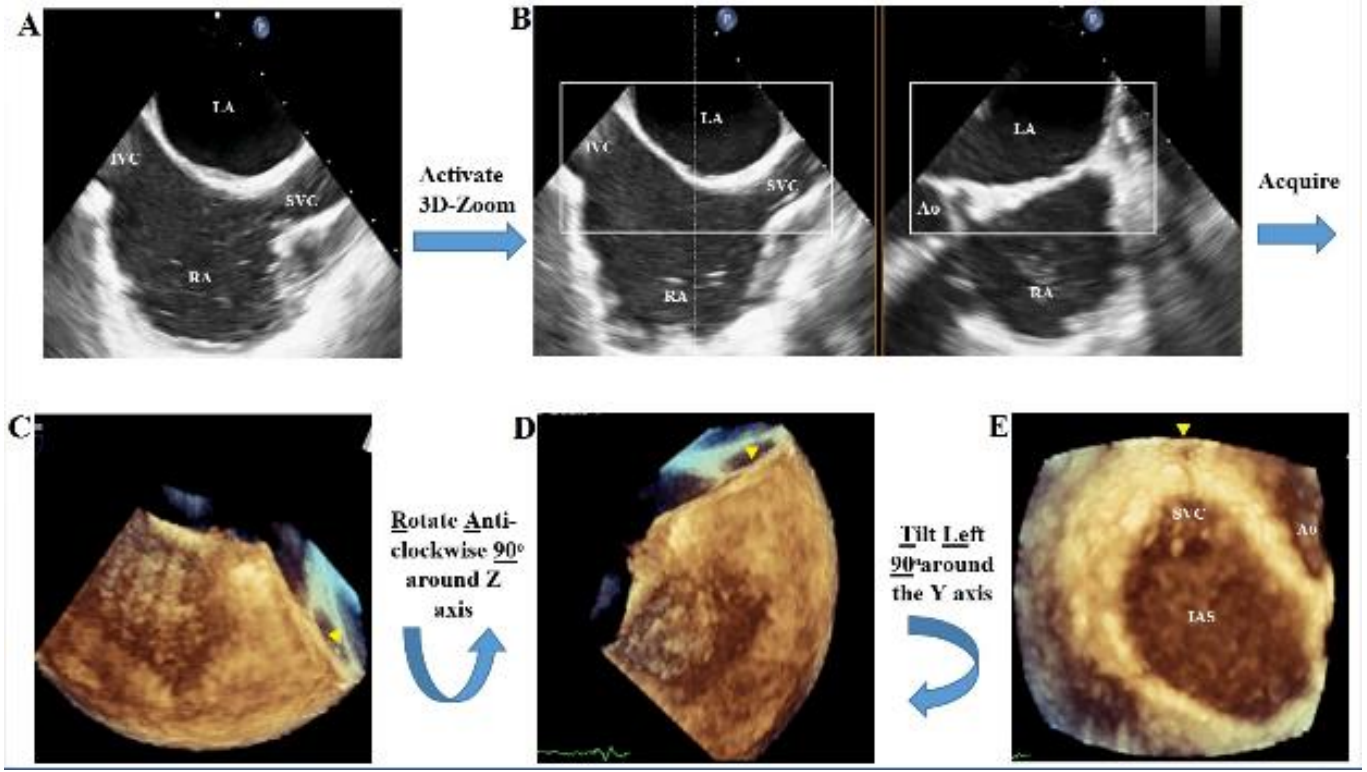

H. Mahmoud et al. Cardiol Res Pract, 2015. doi:10.1155/2015/174051

Imaging of the inter-atrial septum
RATLe-90 maneuver

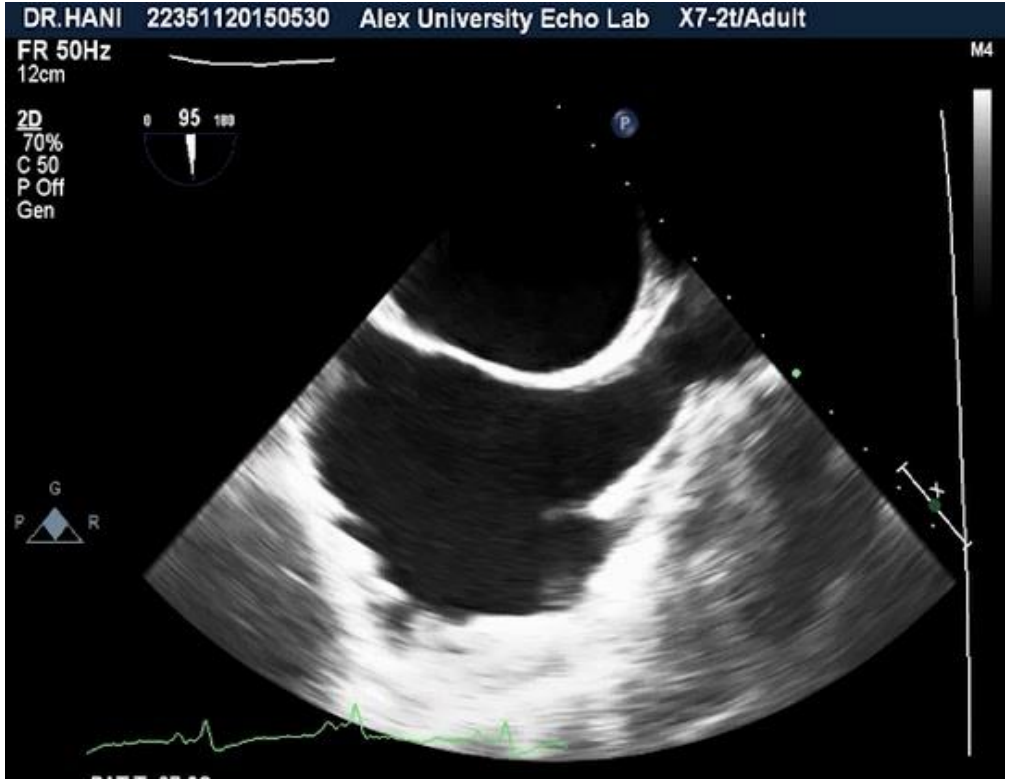

H. Mahmoud et al. Cardiol Res Pract, 2015. doi:10.1155/2015/174051

Imaging of the inter-atrial septum
RATLe-90 maneuver

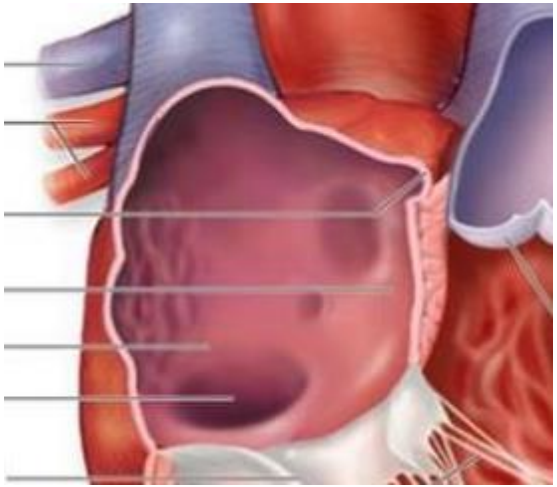

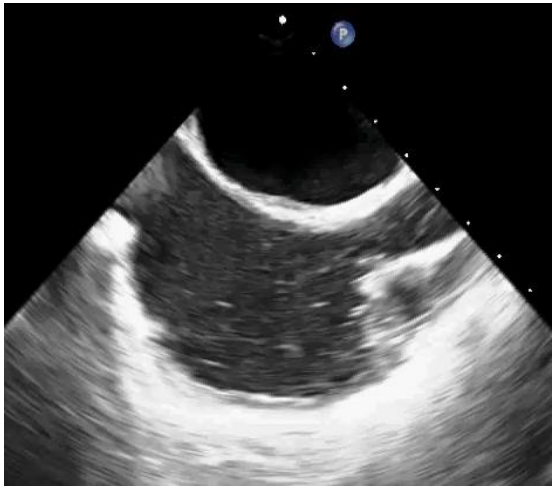

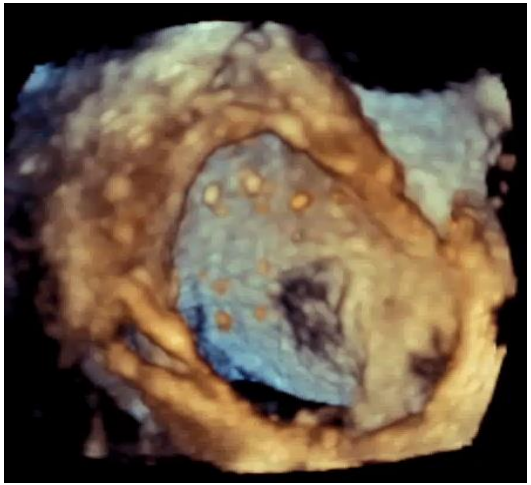

H. Mahmoud et al. Cardiol Res Pract, 2015. doi:10.1155/2015/174051

Dr. Hani Mahmoud

Imaging of the inter-atrial septum
RATLe-90 maneuver

Cardiology Research and Practice

Cardiology Research and Practice
Volume 2015 (2015), Article ID 174051, 4 pages
http://dx.doi.org/10.1155/2015/174051

Research Article

A Proposed Maneuver to Guide Transseptal Puncture Using Real-Time Three-Dimensional Transesophageal Echocardiography: Pilot Study

Hani M. Mahmoud,[1] Mohammed A. Al-Ghamdi,[1] Abdullah E. Ghabashi,[1] and Ashraf M. Anwar[2]

Received 20 April 2015; Revised 17 May 2015; Accepted 19 May 2015

Academic Editor: Terrence D. Ruddy

Ostium secondum ASD

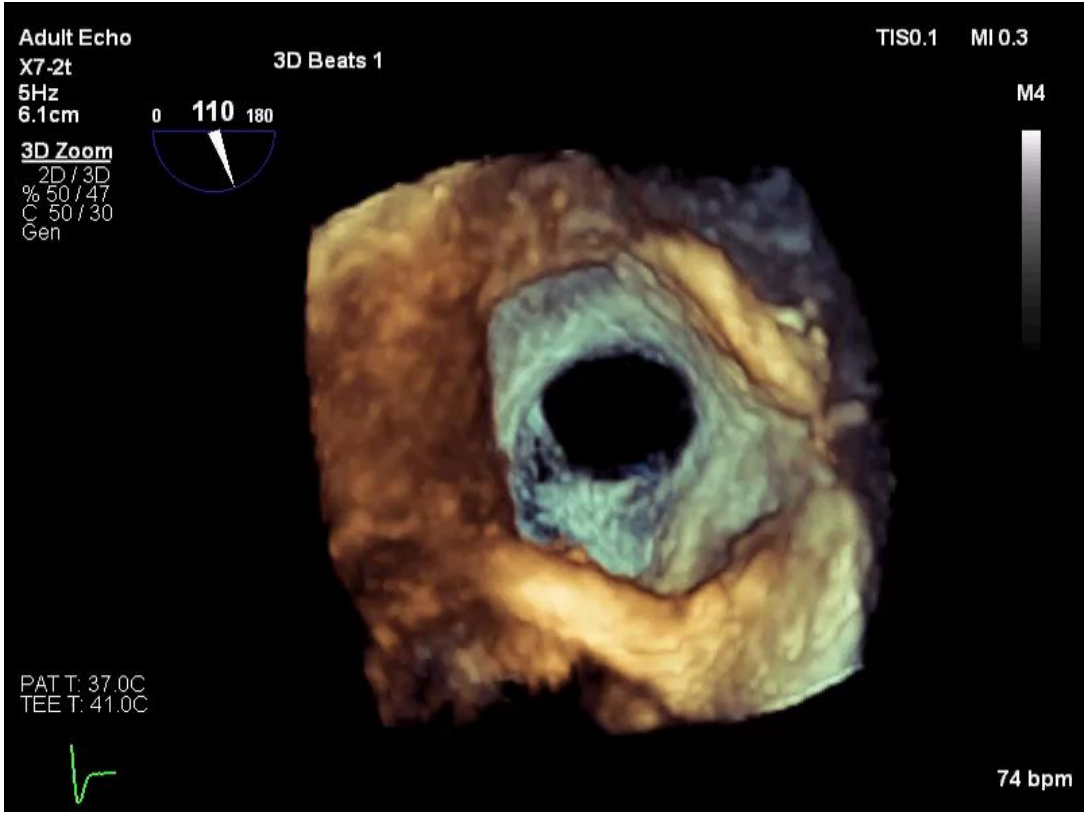

Ostium secondum ASD

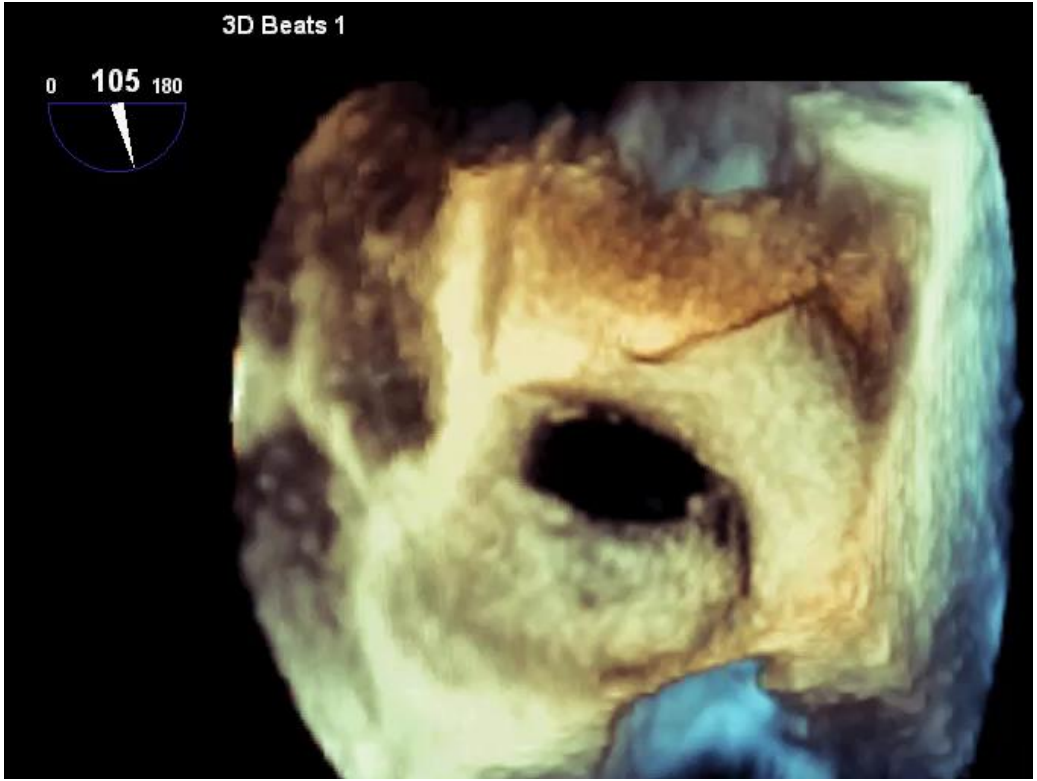

Ostium secondum ASD

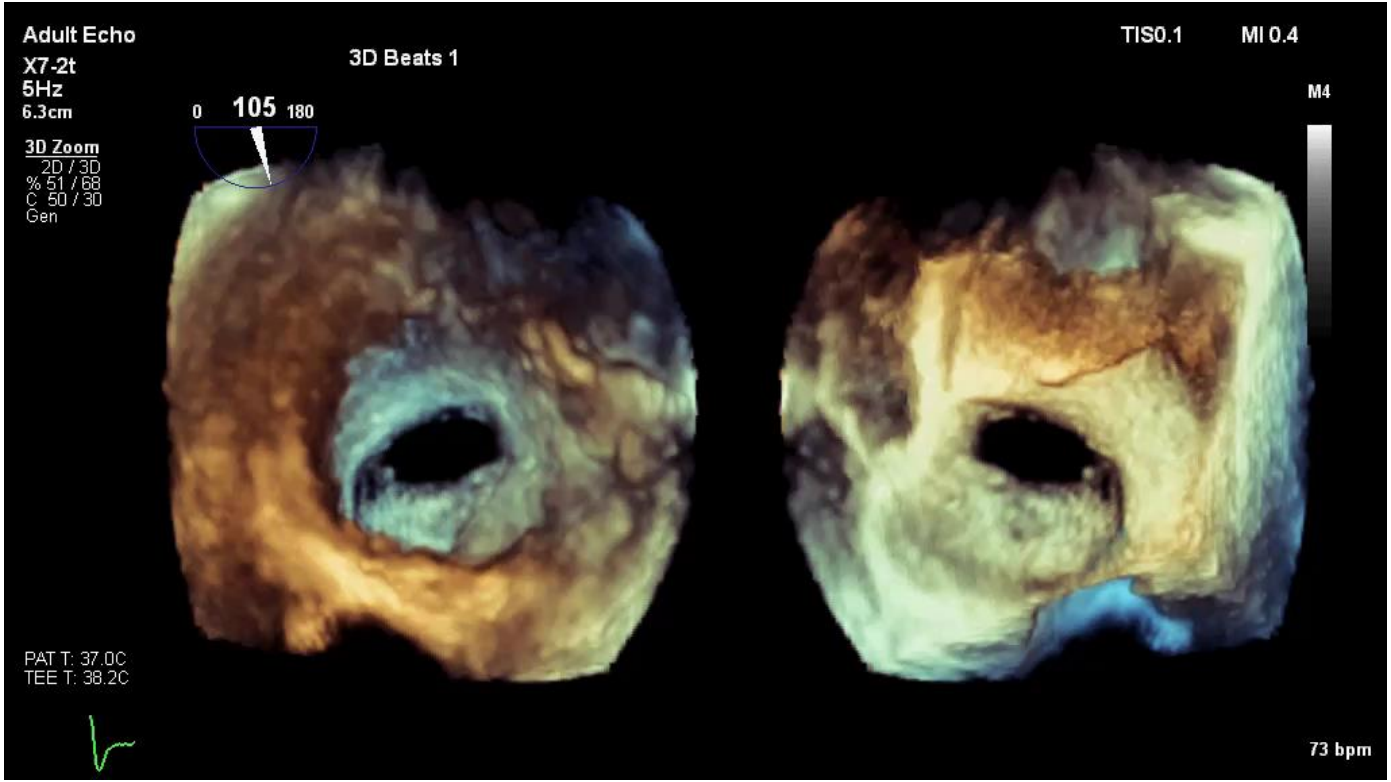

Ostium secondum ASD

Fenestrated ASD

Ostium secondum ASD

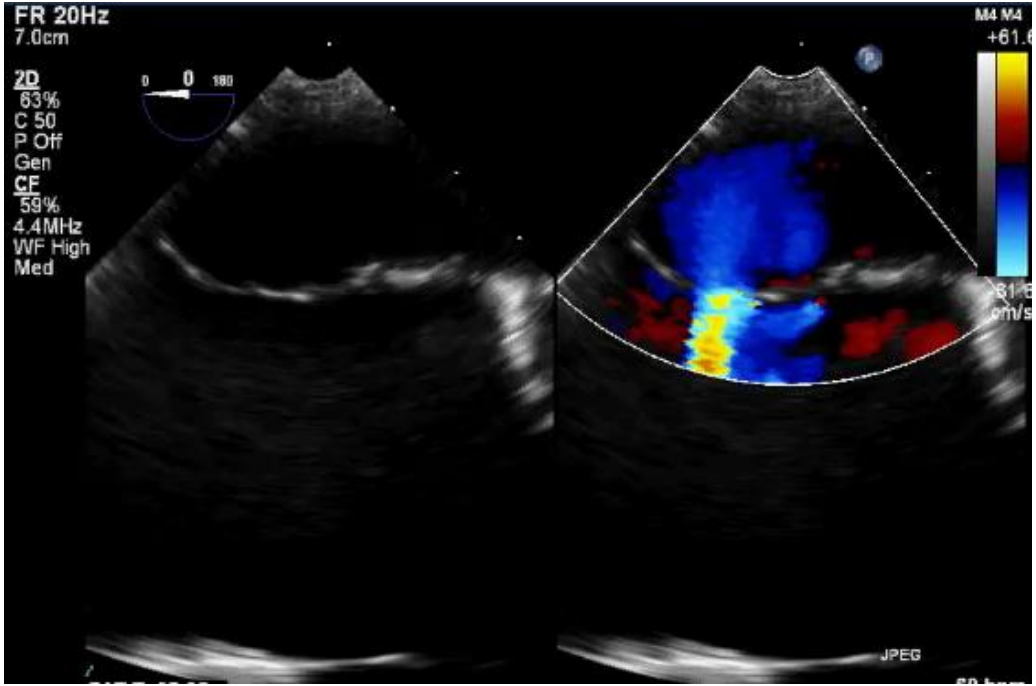

Ostium secondum ASD

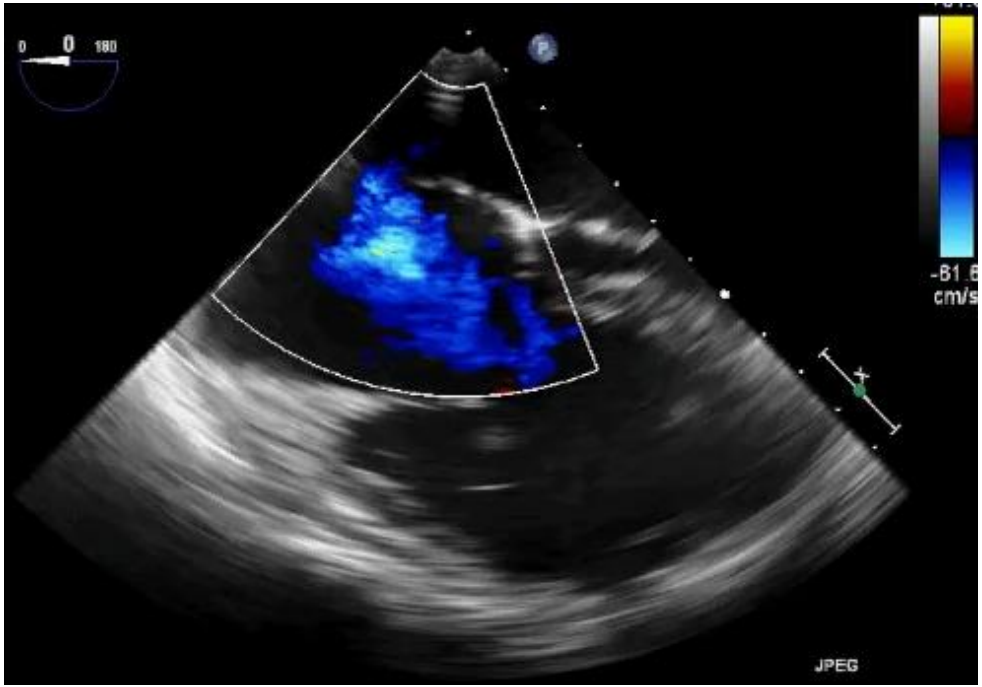

Ostium secondum ASD

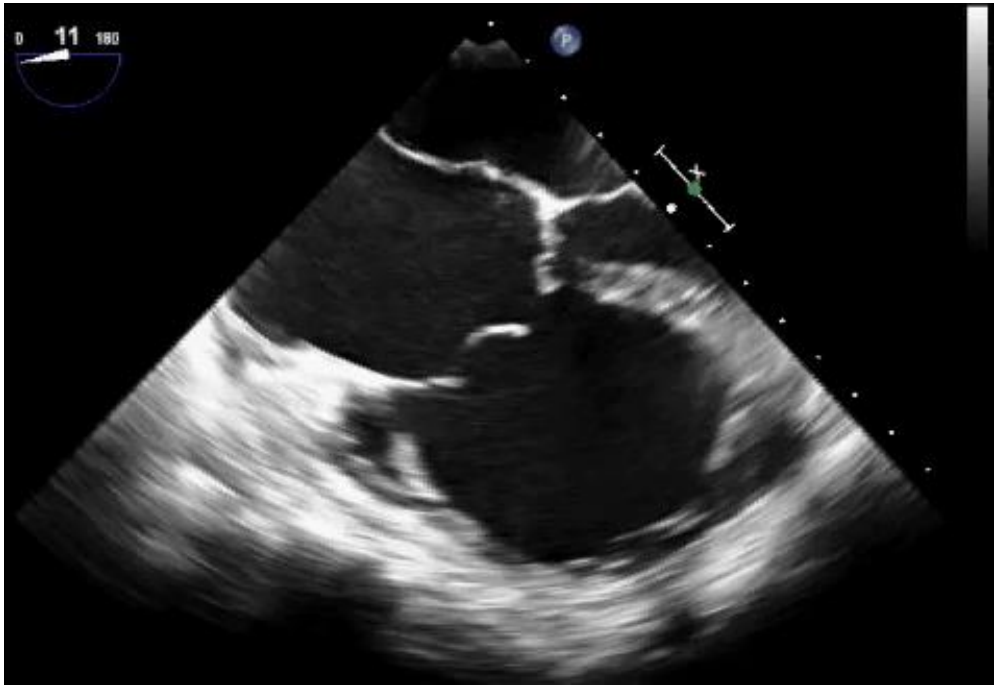

Ostium secondum ASD

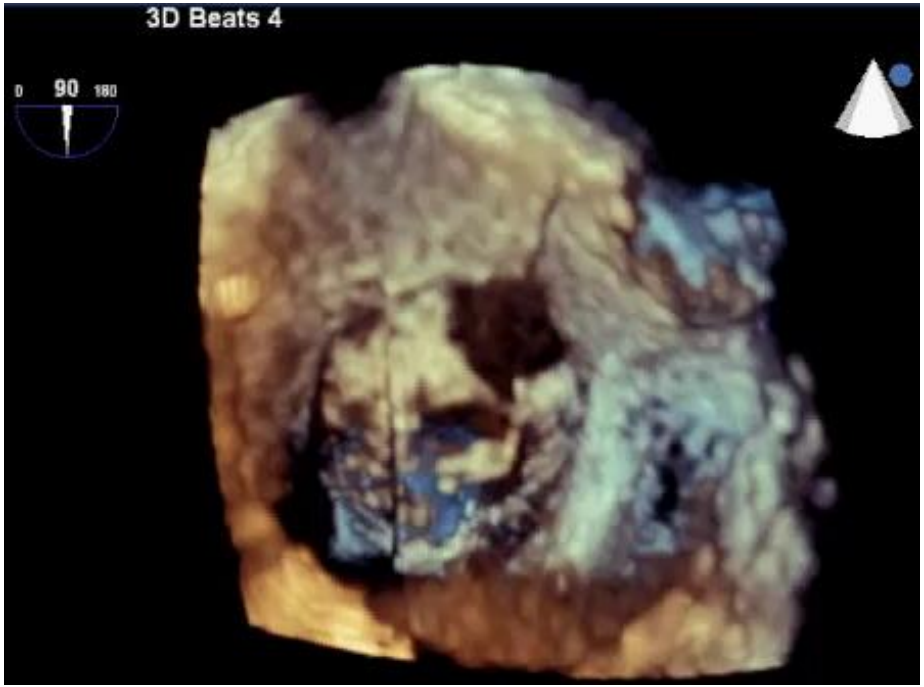

Ostium secondum ASD

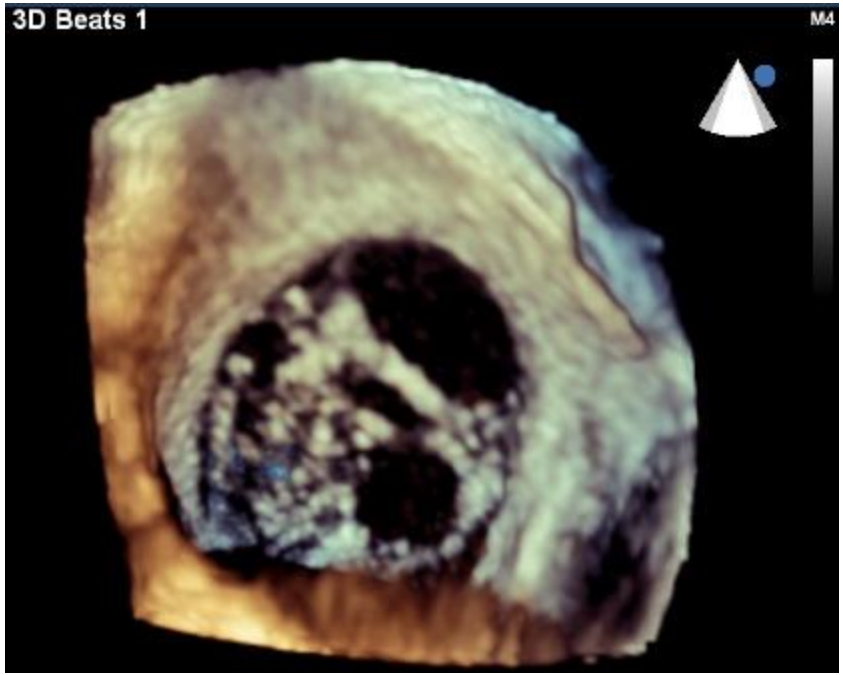

Ostium secondum ASD

High ostium secundum ASD

High Ostium secondum ASD

- A rare form of ostium secundum ASD occurs when the superior limbic band of the septum secundum is absent. In such cases, the atrial communication is ‘‘high’’ in the septum, in close proximity to the SVC.

- However, these defects should not be confused with the sinus venosus defect of the SVC type. Importantly, the high ostium secundum ASD is not associated with anomalous pulmonary venous return.

High Ostium secondum ASD

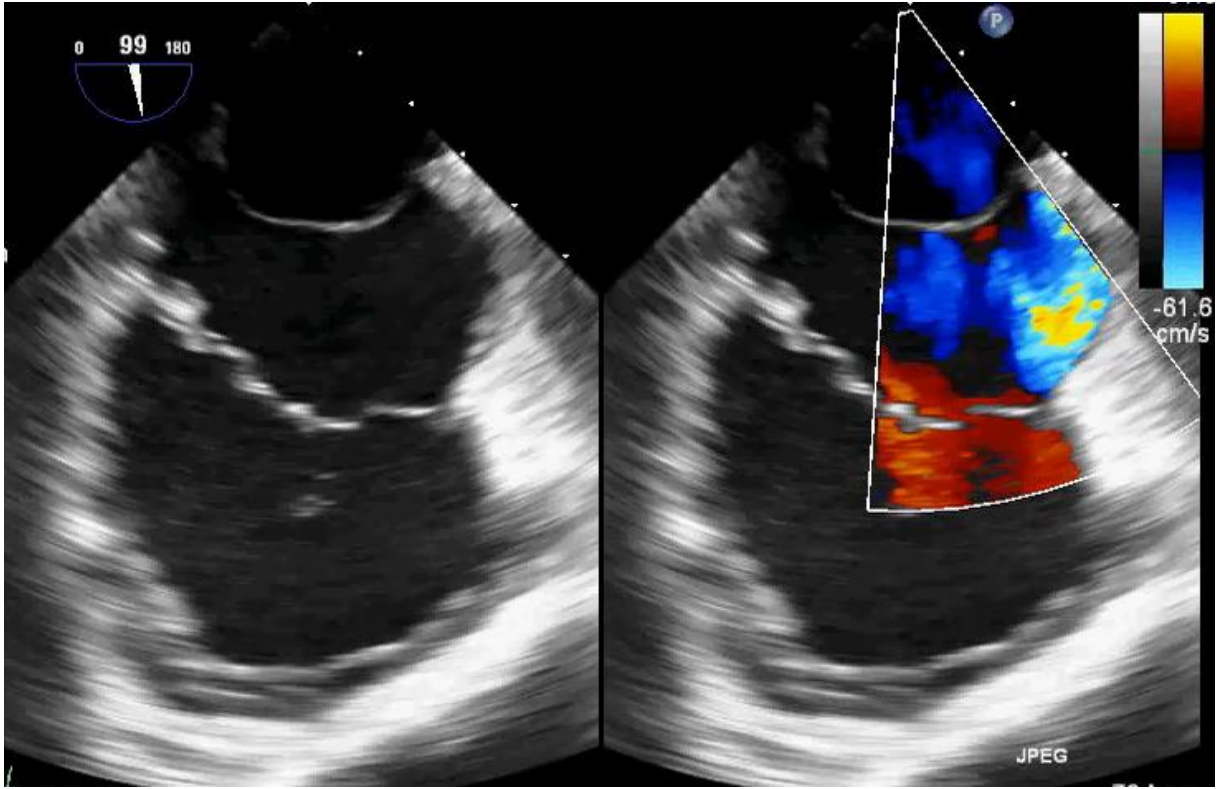

High Ostium secondum ASD

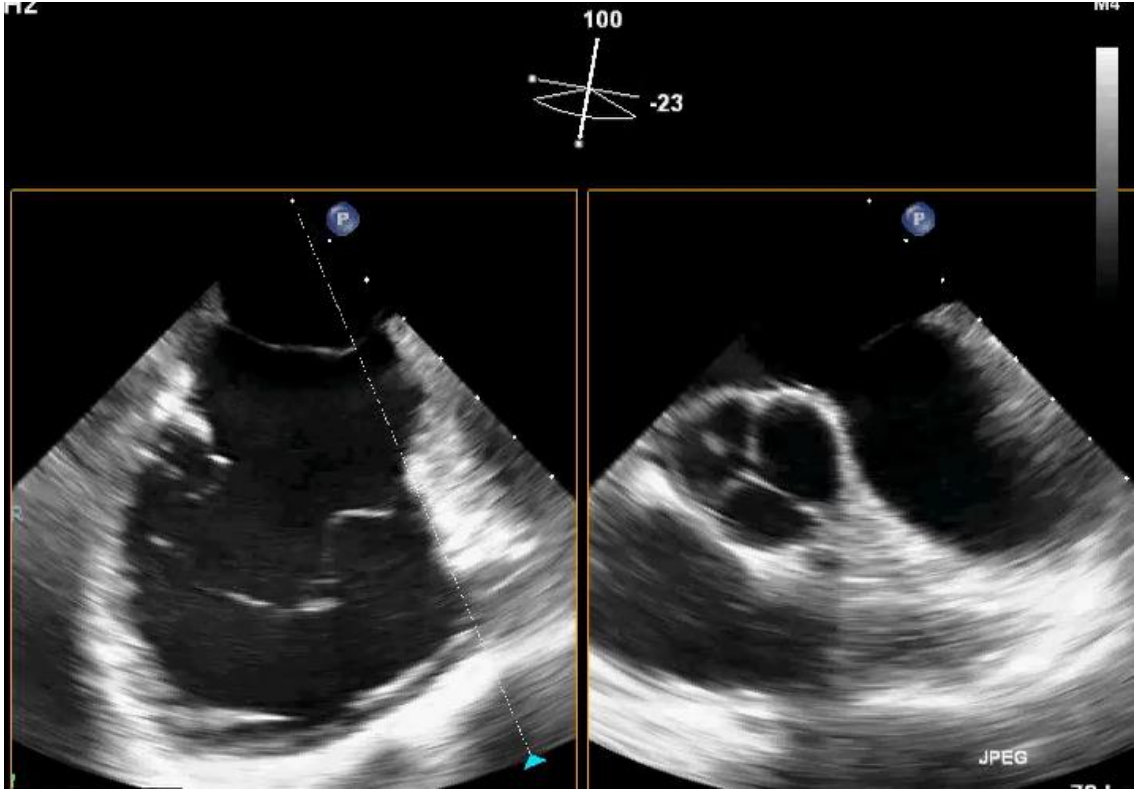

High Ostium secondum ASD

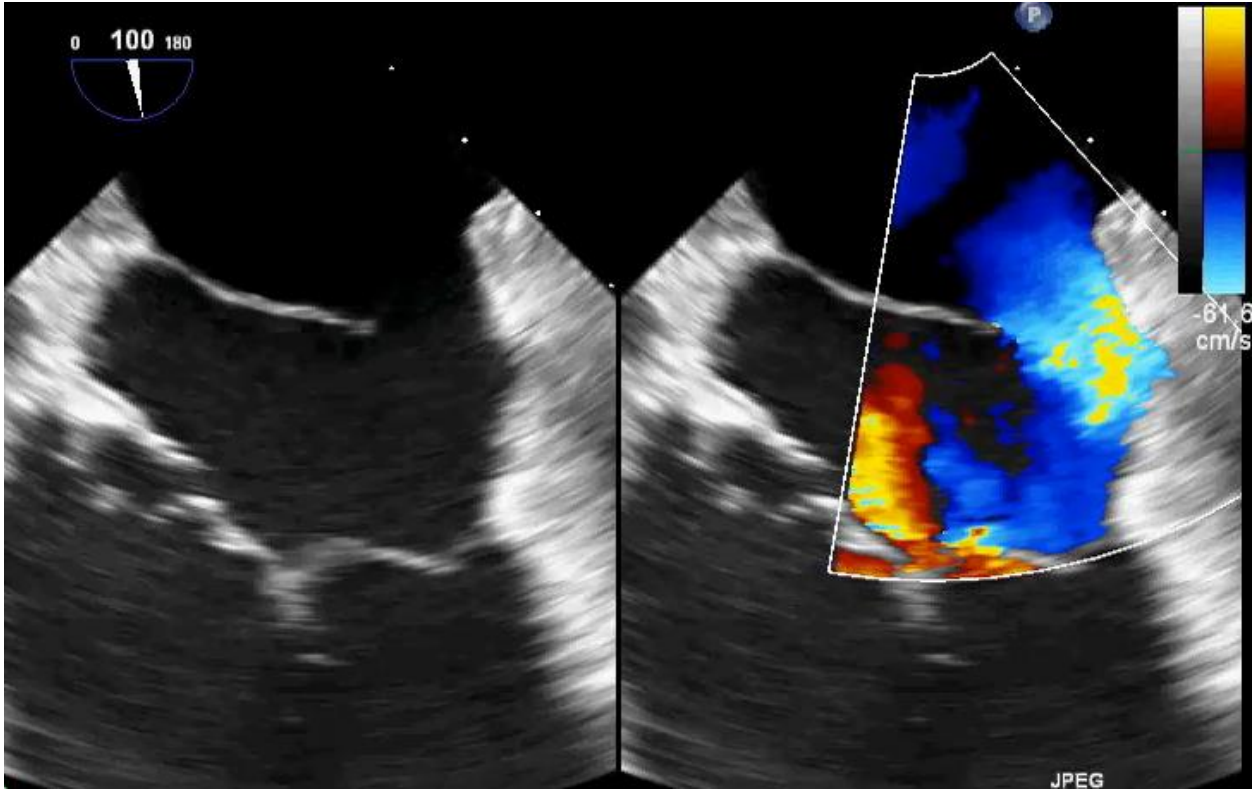

High Ostium secondum ASD

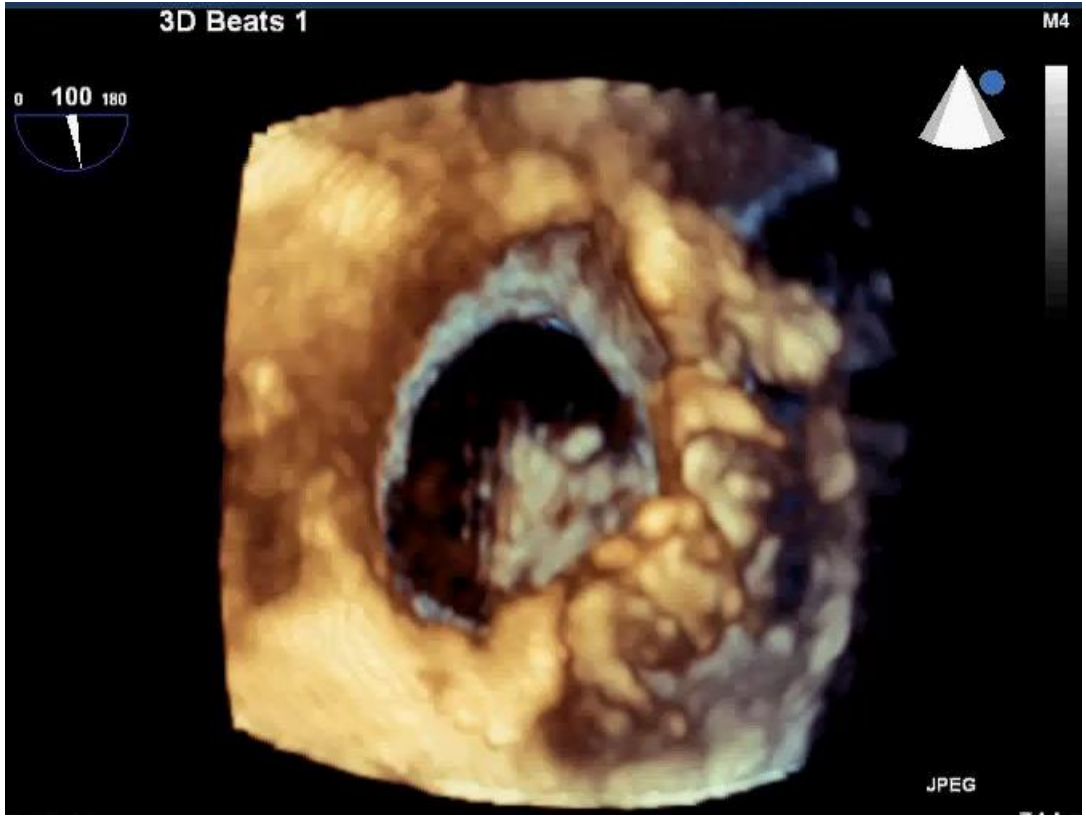

High Ostium secondum ASD

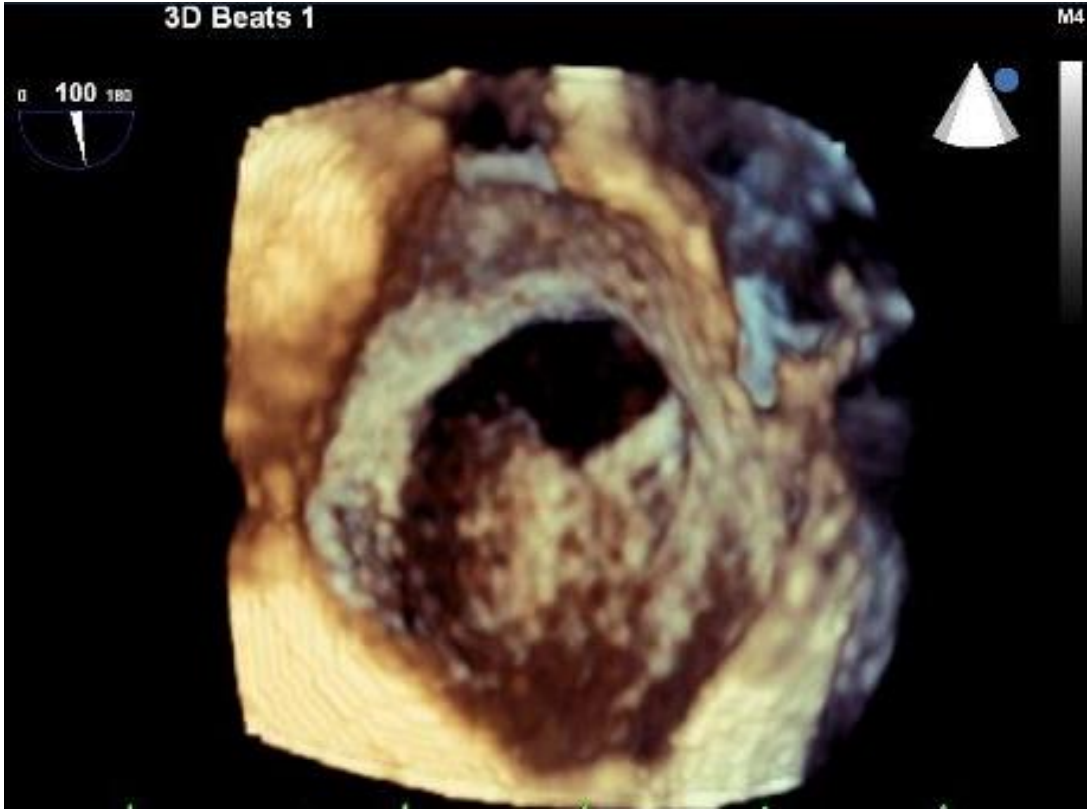

High Ostium secondum ASD

High Ostium secondum ASD

Ostium Primum ASD

Ostium Primum ASD

- An ostium primum ASD is a congenital anomaly that exists within the spectrum of an AV canal Defect
- In early embryologic development, these defects occur when the endocardial cushions fail to fuse because of abnormal migration of mesenchymal cells
- The defect is characterized by an atrial communication resulting from absence of the AV canal portion of the atrial septum in association with a common AV valve annulus and two AV valve orifices

Ostium Primum ASD

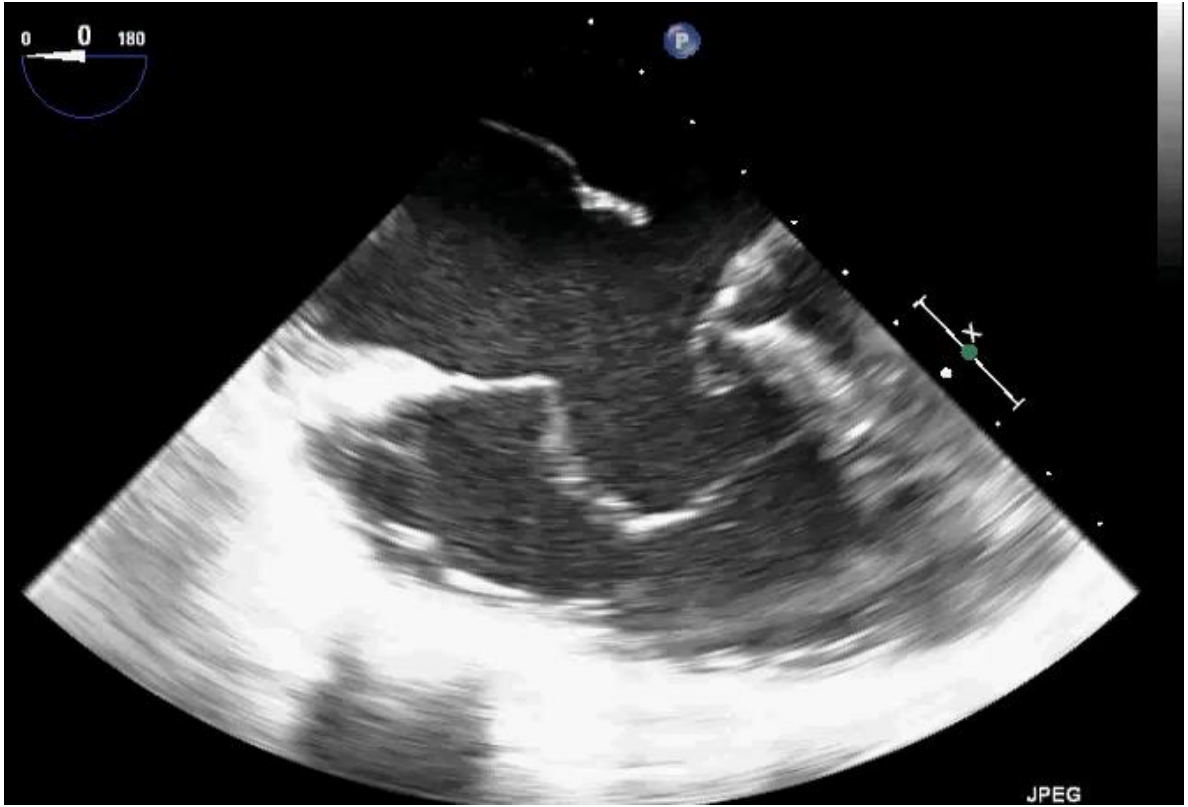

Ostium Primum ASD

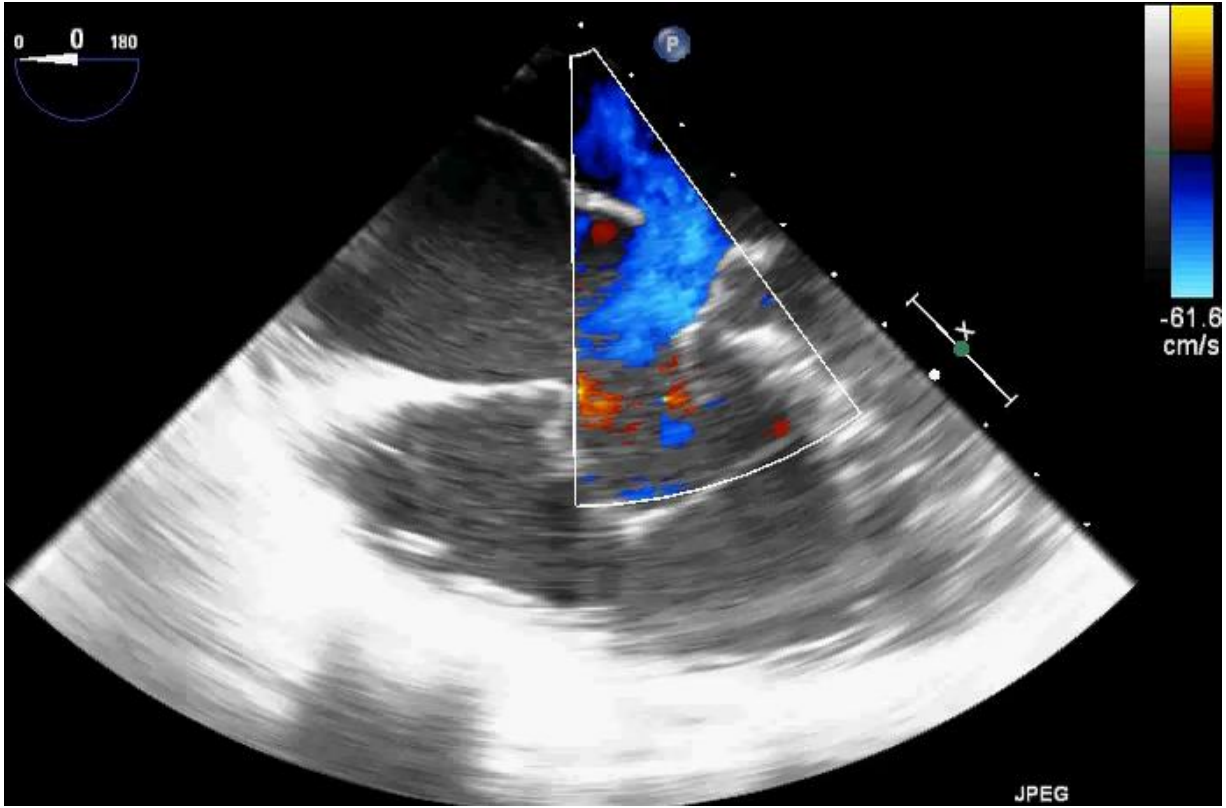

Ostium Primum ASD

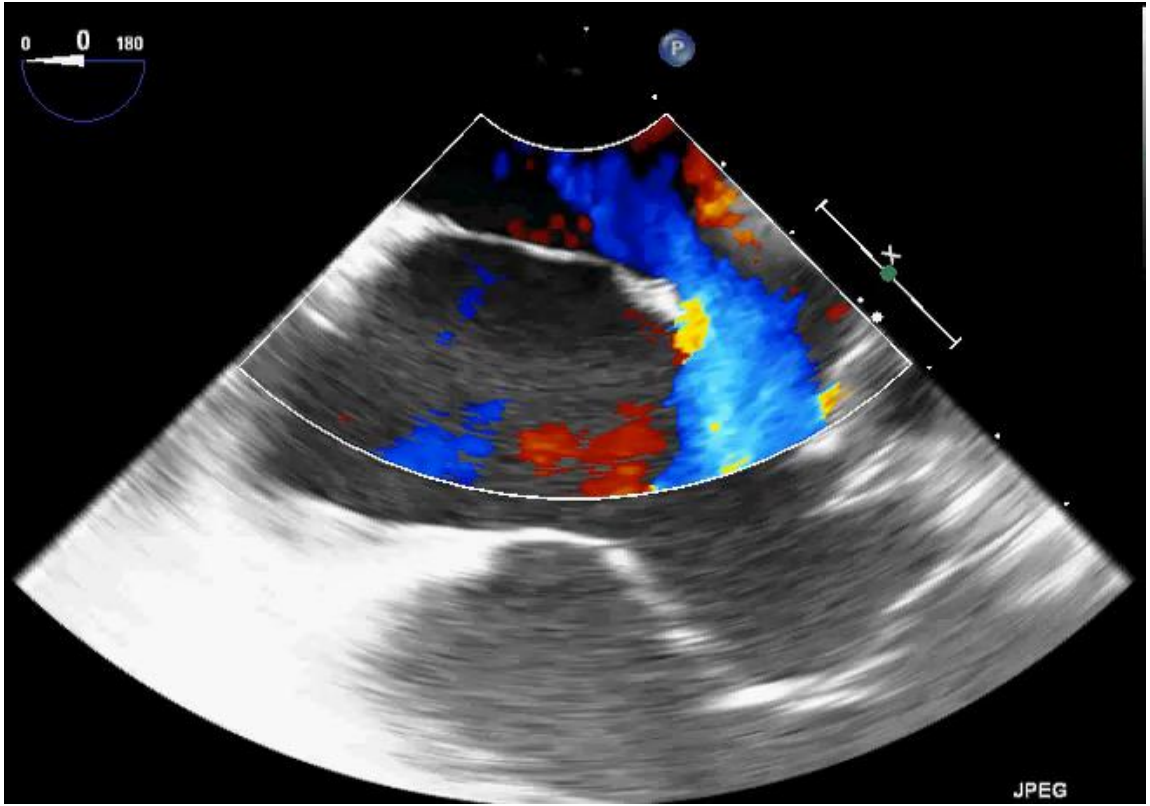

Ostium Primum ASD

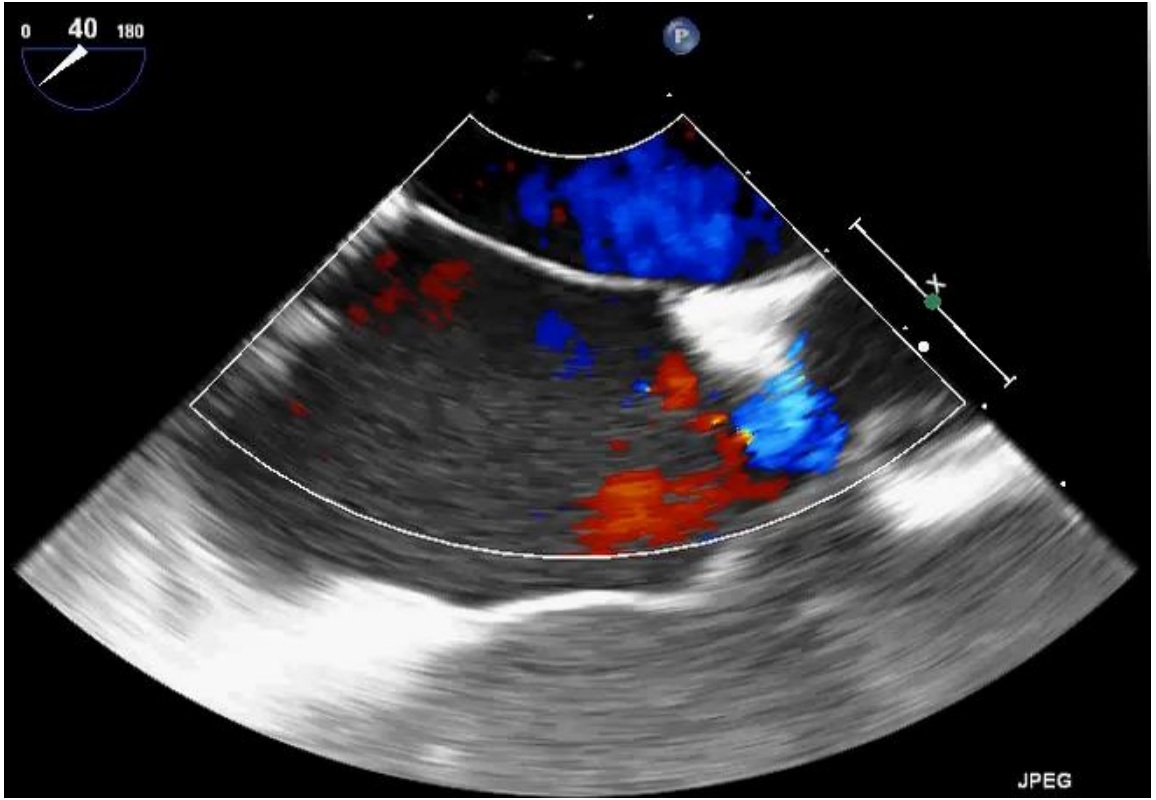

Ostium Primum ASD

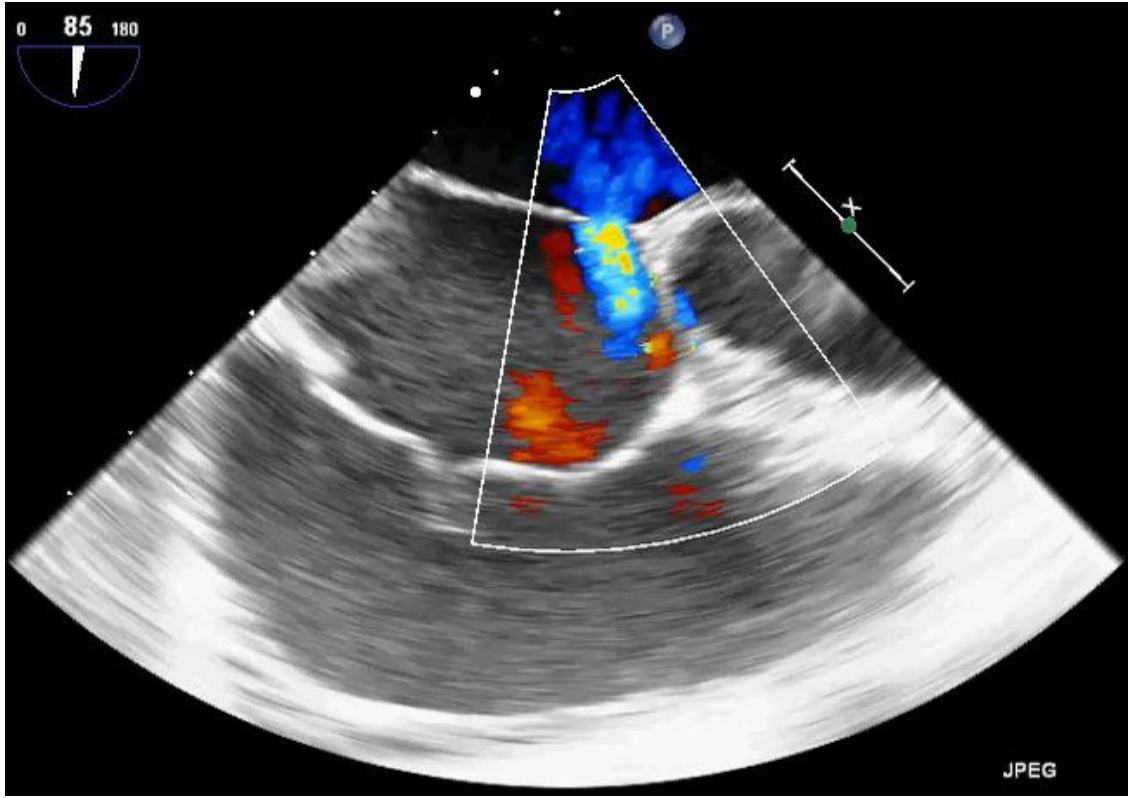

Ostium Primum ASD

Ostium Primum ASD

Ostium Primum ASD

Ostium Primum ASD

Sinus Venosus Defect

Sinus Venosus Defect

- **Sinus venosus defects are less common than ostium secundum ASDs and are not true ASDs**

- **These defects occur as a result of a partial or complete absence of the sinus venosus septum between the SVC and the right upper pulmonary vein (SVC type) or the right lower and middle pulmonary veins and the RA (inferior vena cava (IVC) type**

Silvestry FE et al. J Am Soc Echocardiogr. 2015;28:910-58

Sinus Venosus Defect

- In most cases of sinus venosus defects of the SVC type, the right upper pulmonary vein is connected normally but drains anomalously to the RA.

- However, in some cases, the right pulmonary vein or veins will be abnormally connected to the SVC superior to the RA.

Sinus Venosus Defect

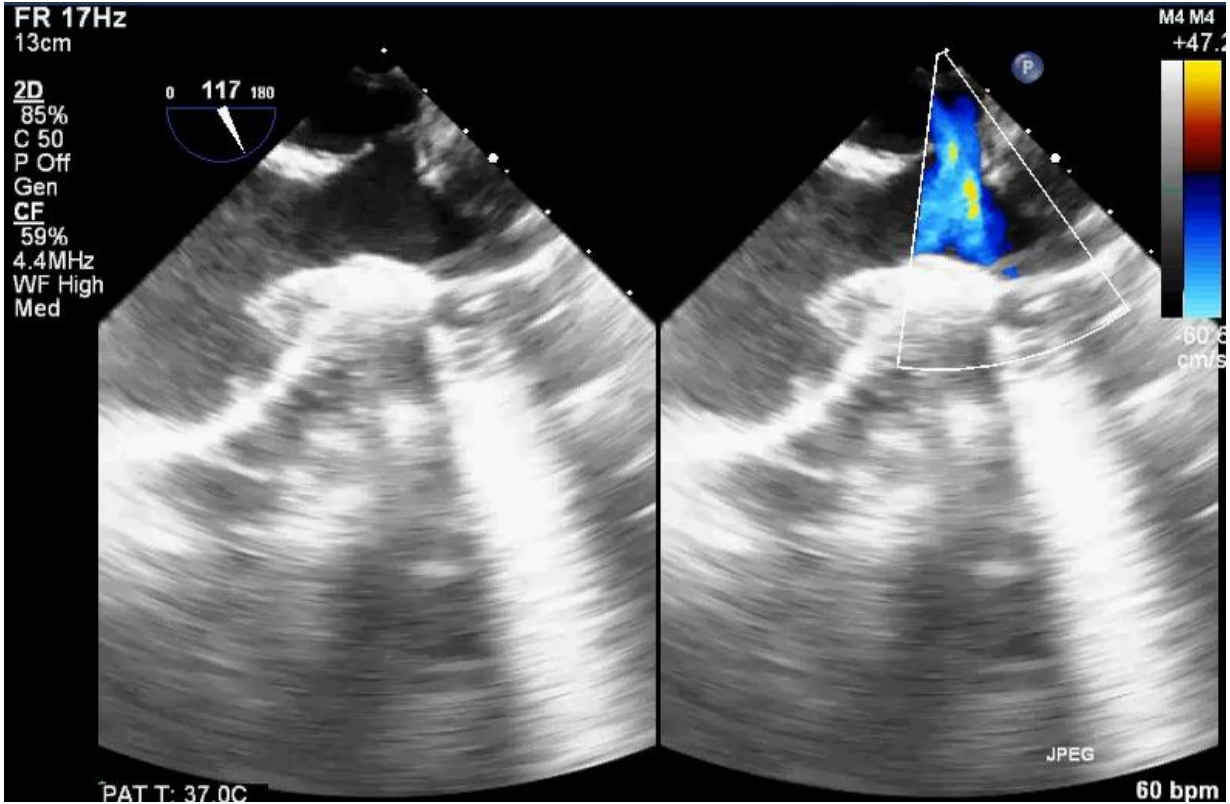

EACVI

EUROPEAN SOCIETY OF CARDIOLOGY

Sinus Venosus Defect

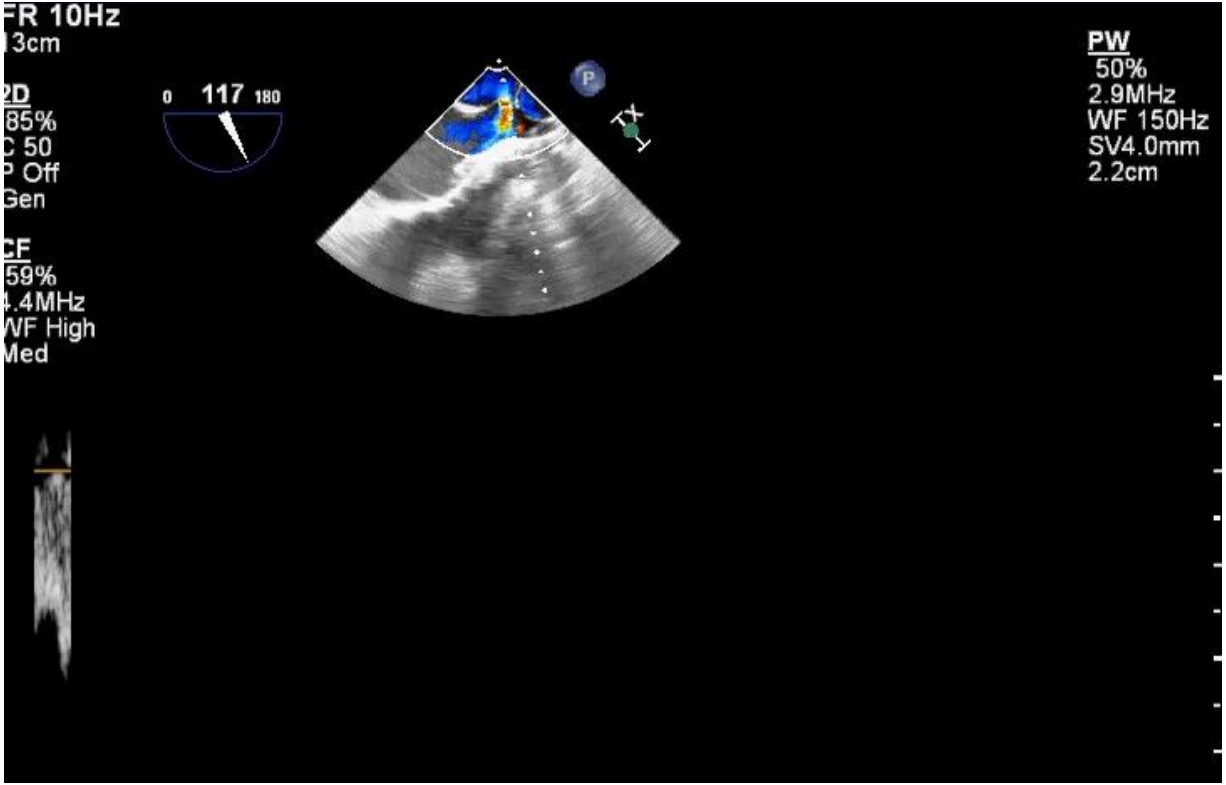

Sinus Venosus Defect

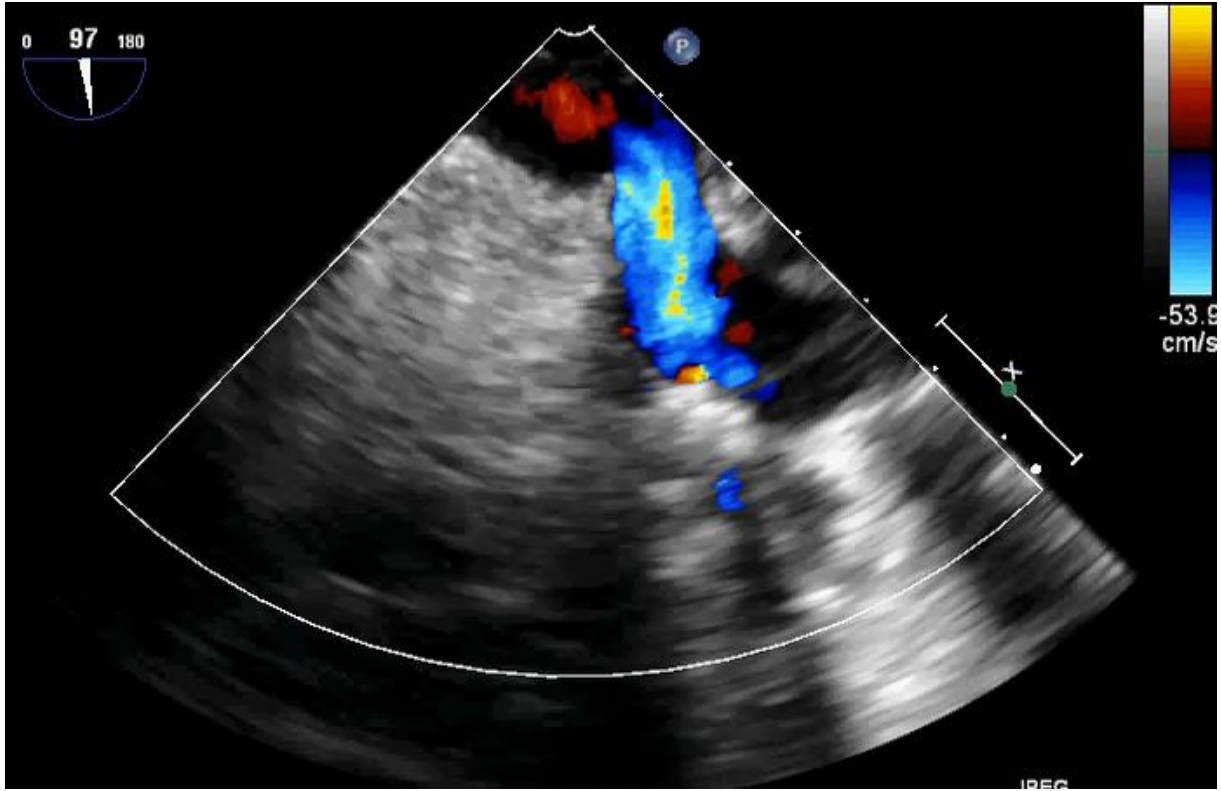

Deroofed coronary sinus

Deroofed coronary sinus

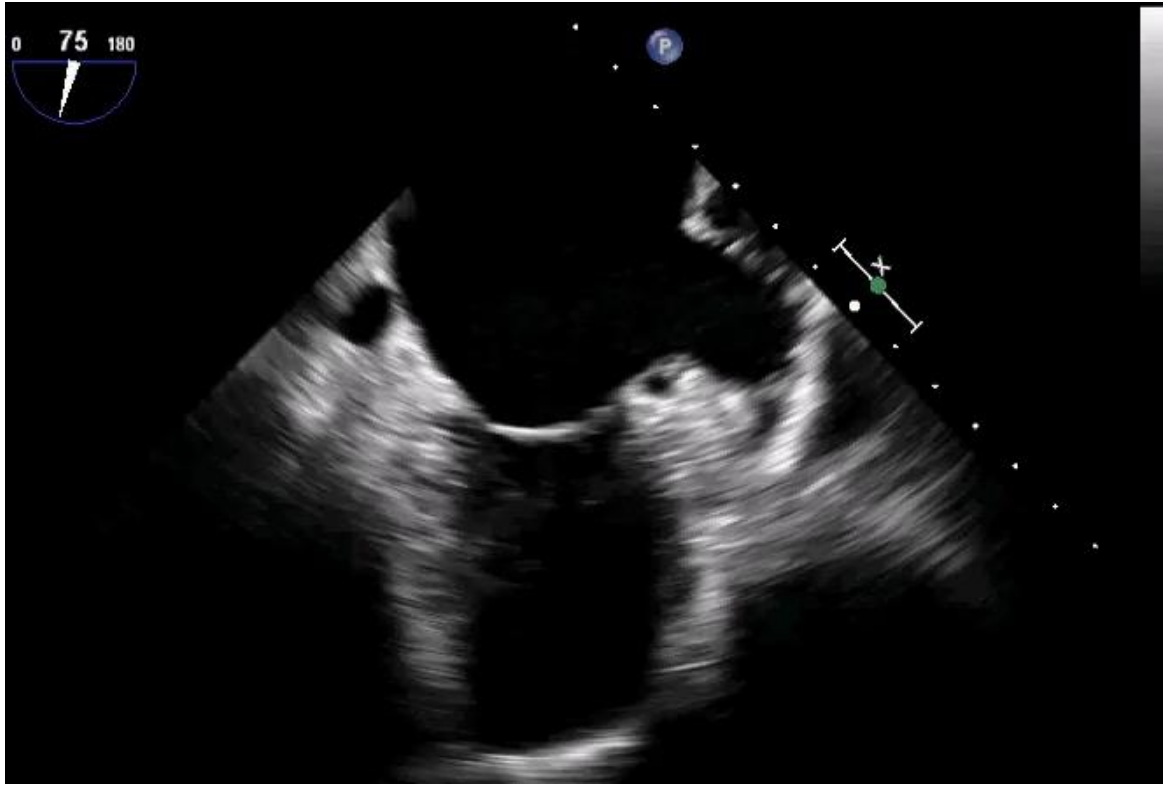

Deroofed coronary sinus

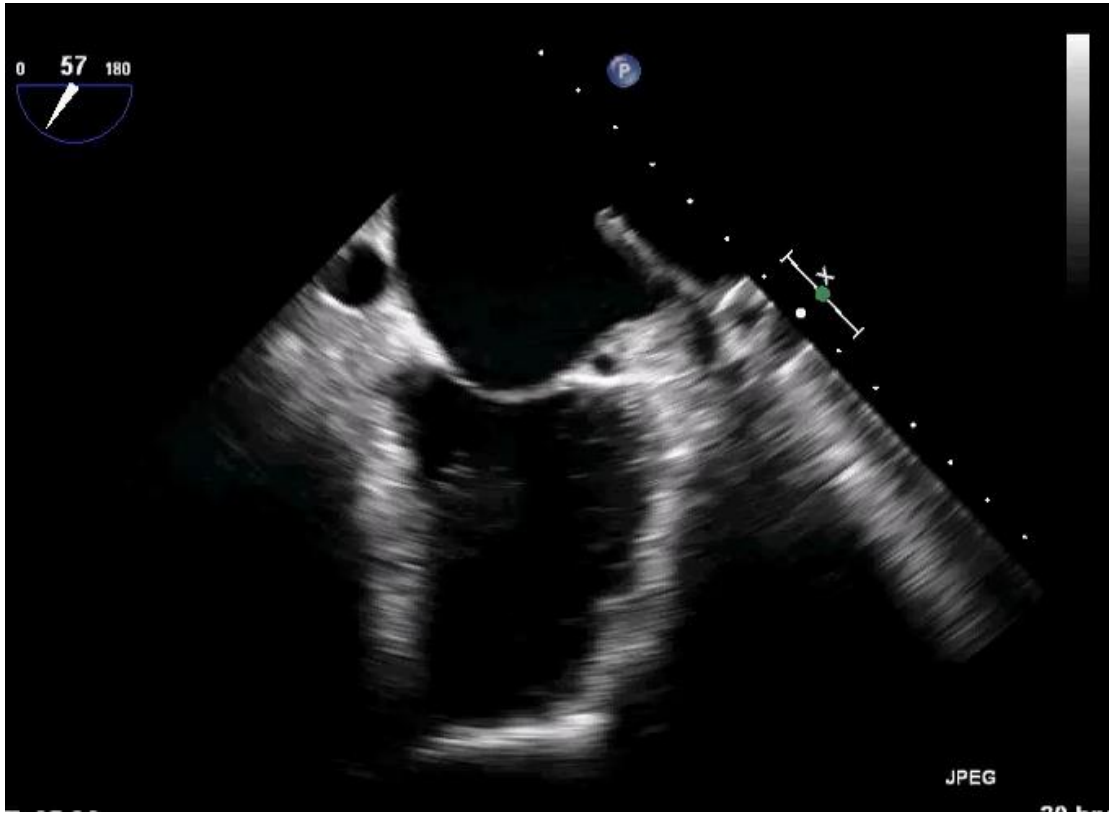

Deroofed coronary sinus

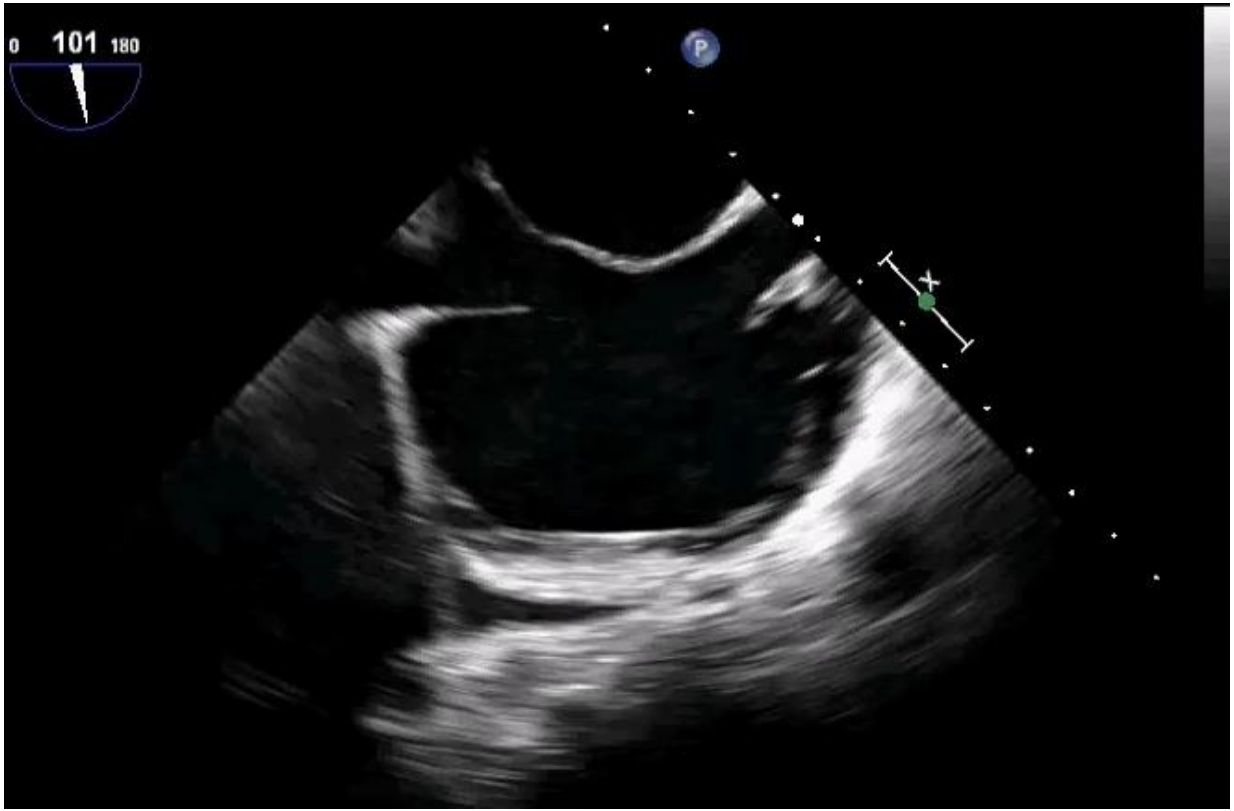

Deroofed coronary sinus

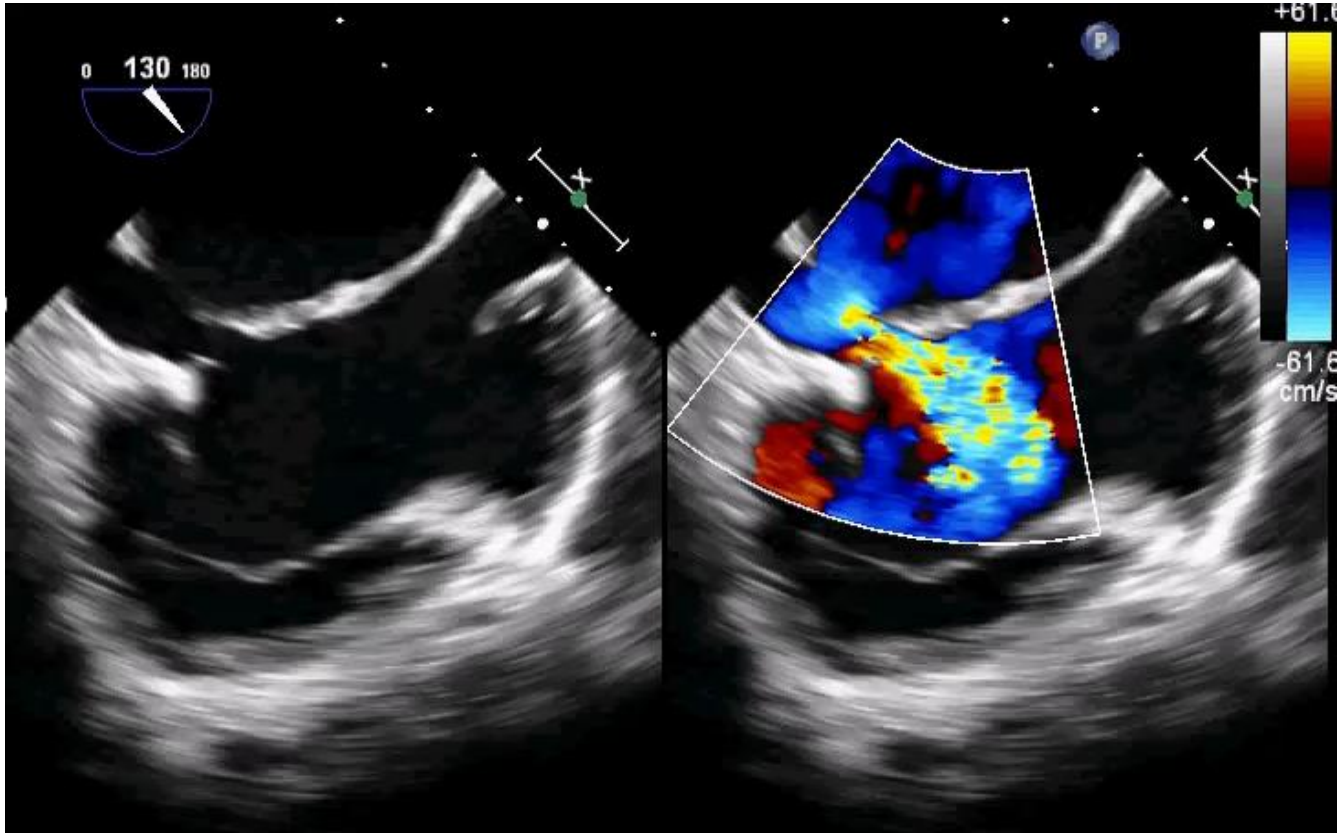

Deroofed coronary sinus

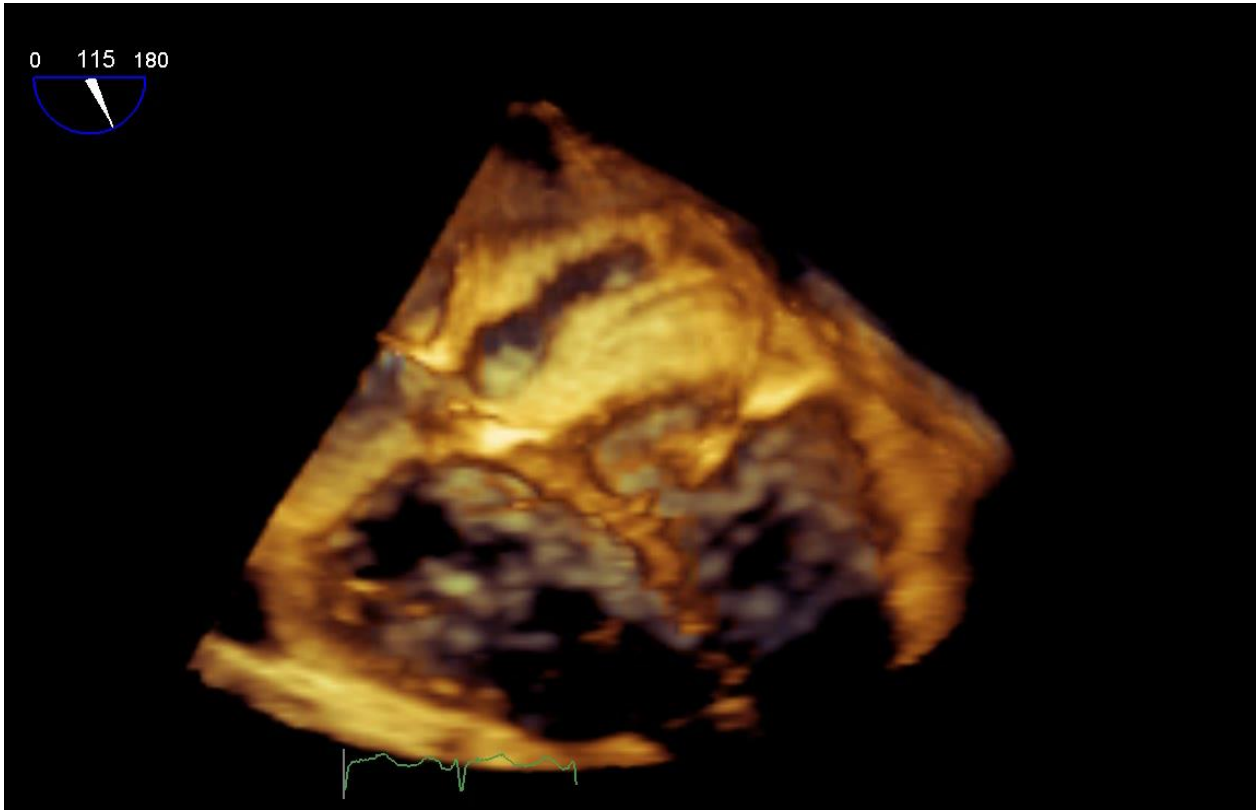

Deroofed coronary sinus

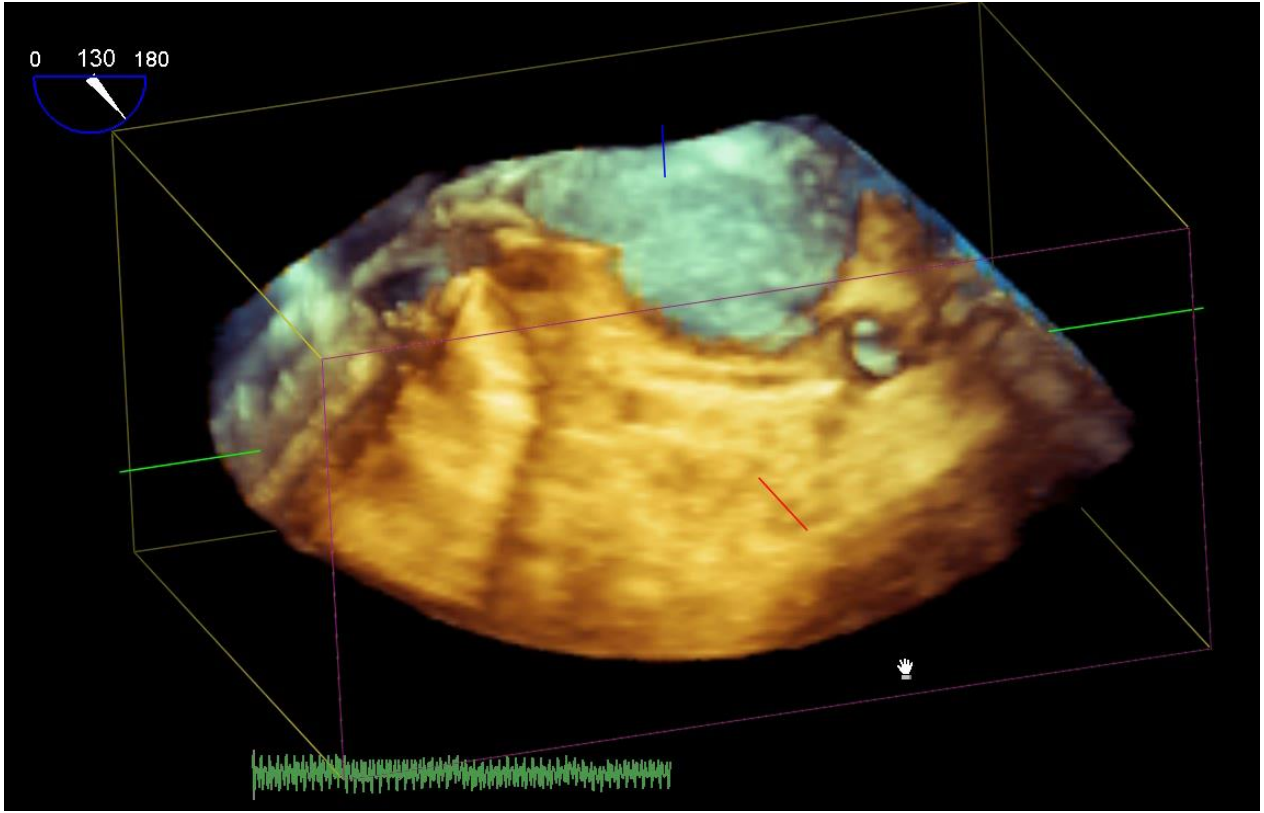

Specific characteristics of ASD that should be routinely measured and reported
ASD type—PFO, primum ASD, secundum ASD, or other atrial communication (sinus venosus defect, unroofed coronary sinus, anomalous pulmonary vein drainage)
Doppler flow—presence of left to right, right to left or bidirectional flow
Presence or absence of ASA
Associated findings—eustachian valve or Chiari network
ASD size—maximal and minimal diameters (optimally measured from 3D volume data sets), ASD area
ASD location in septum (i.e., high secundum ASD, sinus venosus defect SVC or IVC type)
Measurement of all rims—aortic, RUPV, superior, posterior, inferior, AV septal
Shape of ASD—round, oval, irregular
Presence of multiple fenestrations
Dynamic nature of ASD—measurement of area and maximum/minimal diameters in end-systole and end-diastole
Stop-flow diameter of ASD (when balloon sizing is used for percutaneous transcatheter closure)

Silvestry FE et al. J Am Soc Echocardiogr. 2015;28:910-58

ASE GUIDELINES & STANDARDS

Guidelines for the Echocardiographic Assessment of Atrial Septal Defect and Patent Foramen Ovale: From the American Society of Echocardiography and Society for Cardiac Angiography and Interventions

Frank E. Silvestry, MD, FASE, Chair, Meryl S. Cohen, MD, FASE, Co-Chair, Laurie B. Armsby, MD, FSCAI, Nitin J. Burkule, MD, DM, FASE, Craig E. Fleishman, MD, FASE, Ziyad M. Hijazi, MD, MPH, MSCAI, Roberto M. Lang, MD, FASE, Jonathan J. Rome, MD, and Yan Wang, RDCS, *Philadelphia, Pennsylvania; Portland, Oregon; Thane, India; Orlando, Florida; Doha, Qatar; and Chicago, Illinois*

(J Am Soc Echocardiogr 2015;28:910-58.)

EACVI

EUROPEAN SOCIETY OF CARDIOLOGY

Pulmonary veins

Left pulmonary veins

<u>120-140°</u> then tilt to extreme left

Left pulmonary veins

<u>120-140°</u> then tilt to extreme left

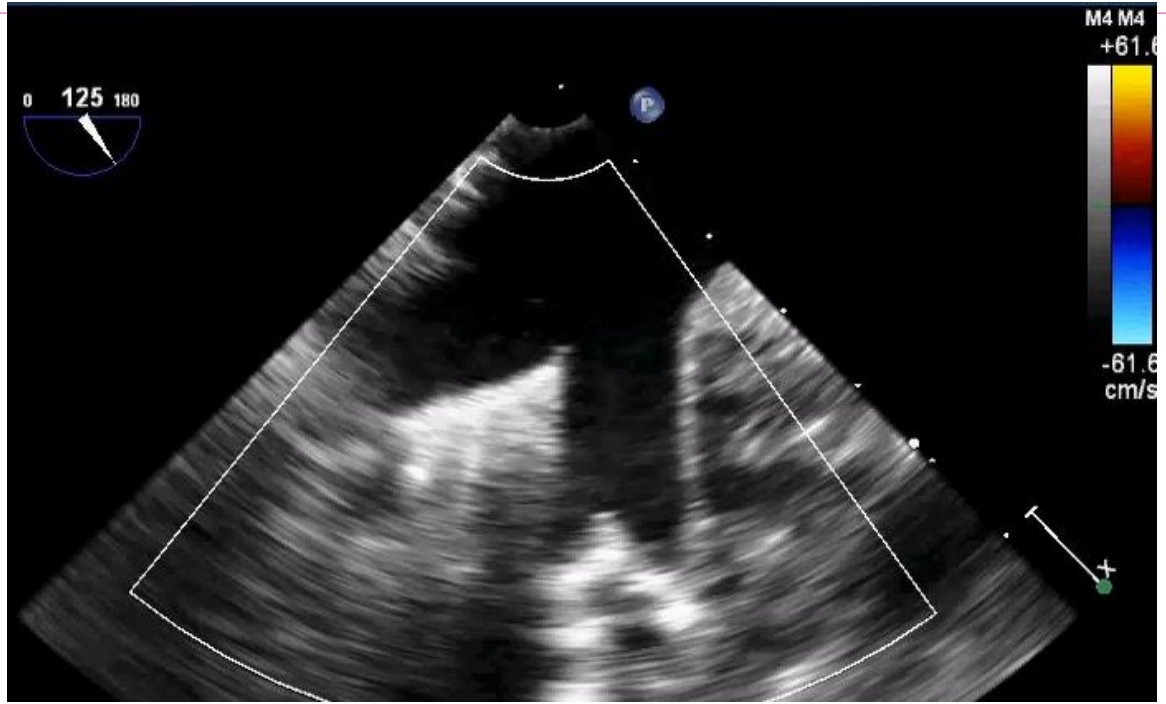

Rt pulmonary veins

45° then
Tilt to extreme right

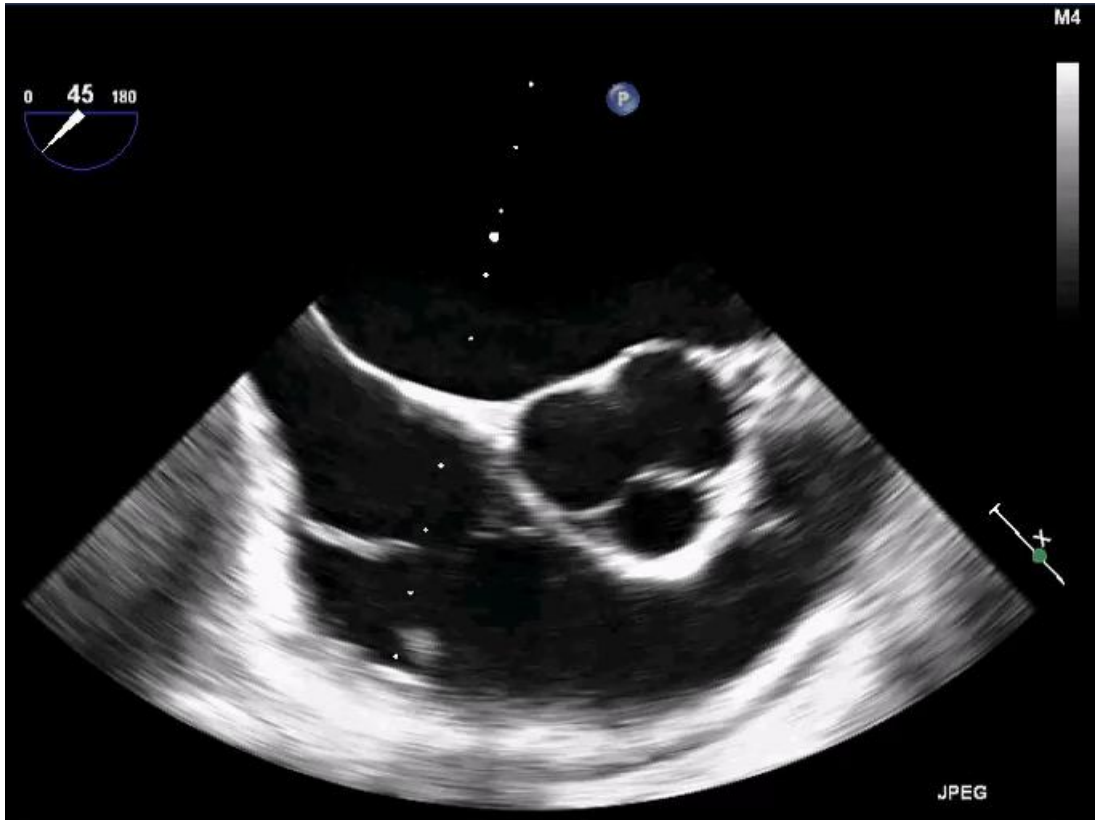

Rt pulmonary veins

45° then
Tilt to extreme right

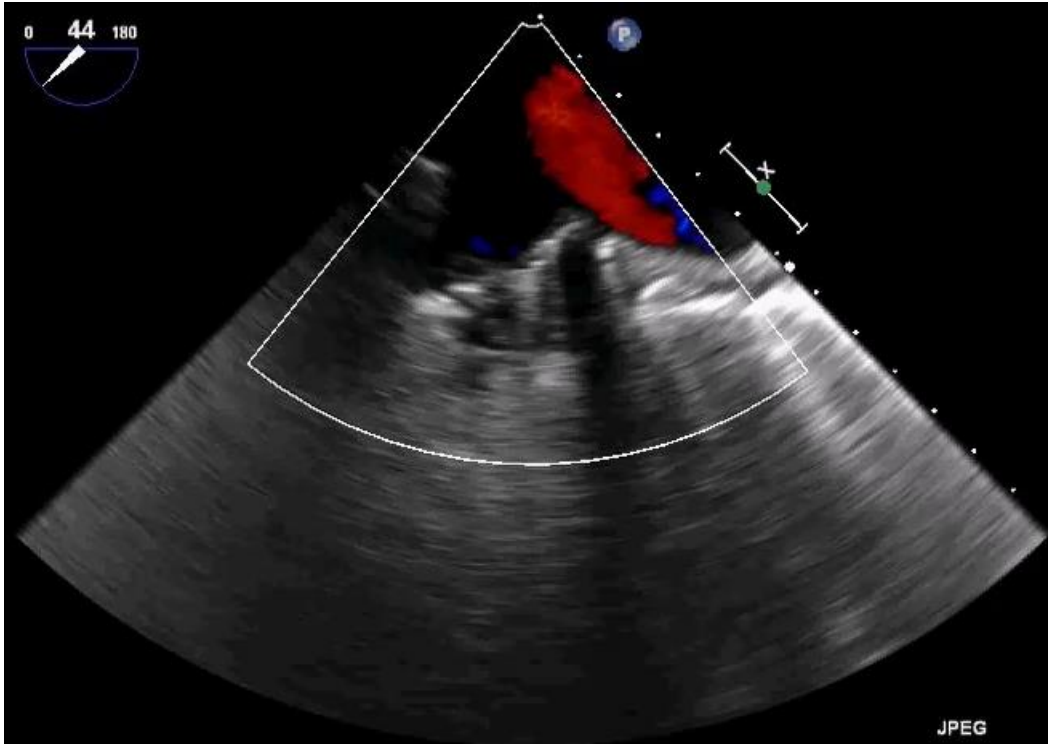

Rt pulmonary veins

45° (Short axis) then
Tilt to extreme right

Lt pulmonary veins

120° (Long axis) then
Tilt to extreme left

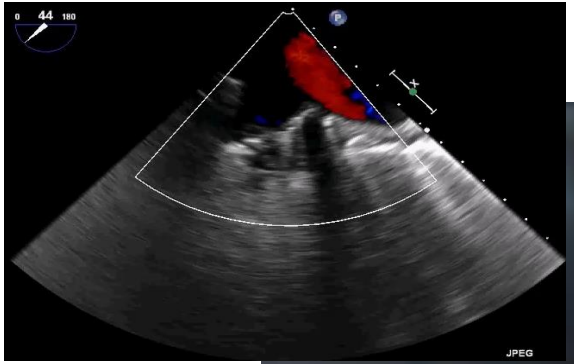

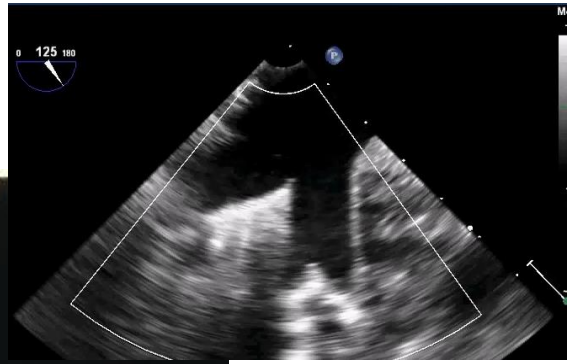

ShoRt = Right ☺ Long = Left

Left atrial appendage

- **Assessment of the LAA**

- **Exclude thrombi**
- **Shape**
- **Number of lobes**
- **Dimensions**

LAA closure

- **Exclude thrombi**

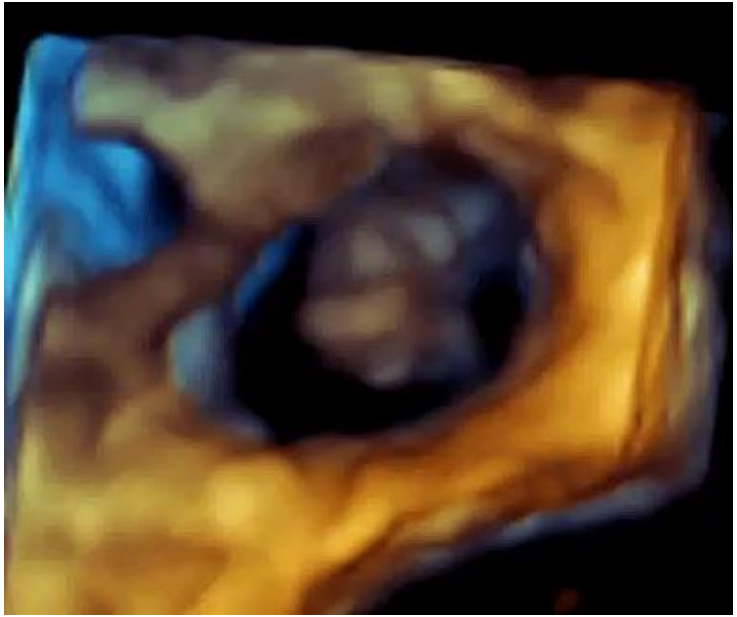

LAA assessment

➢ Shape

The **WindSock Type** LAA is an anatomy in which one dominant lobe of sufficient length is the primary structure.

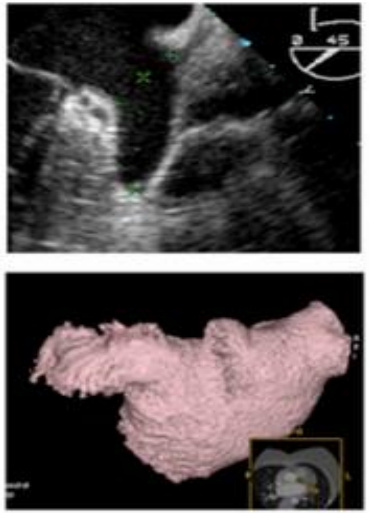

The **ChickenWing Type** LAA is an anatomy whose main feature is a sharp bend in the dominant lobe of the LAA anatomy at some distance from the perceived LAA ostium.

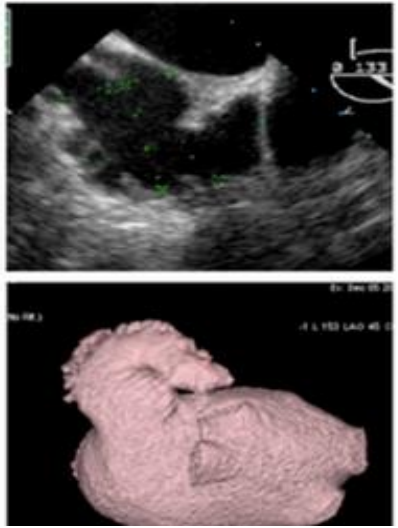

The **Broccoli Type** LAA is an anatomy whose main feature is an LAA that has limited overall length with more complex internal characteristics.

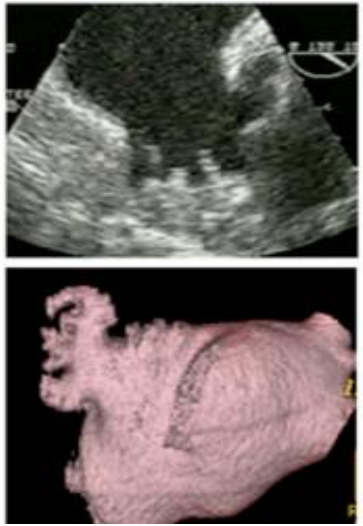

LAA assessment

- **Number of lobes**
  - ✓ **> 80% has more than 1 lobe**
  - ✓ **Go to the major lobe**

0 degrees

LAA assessment

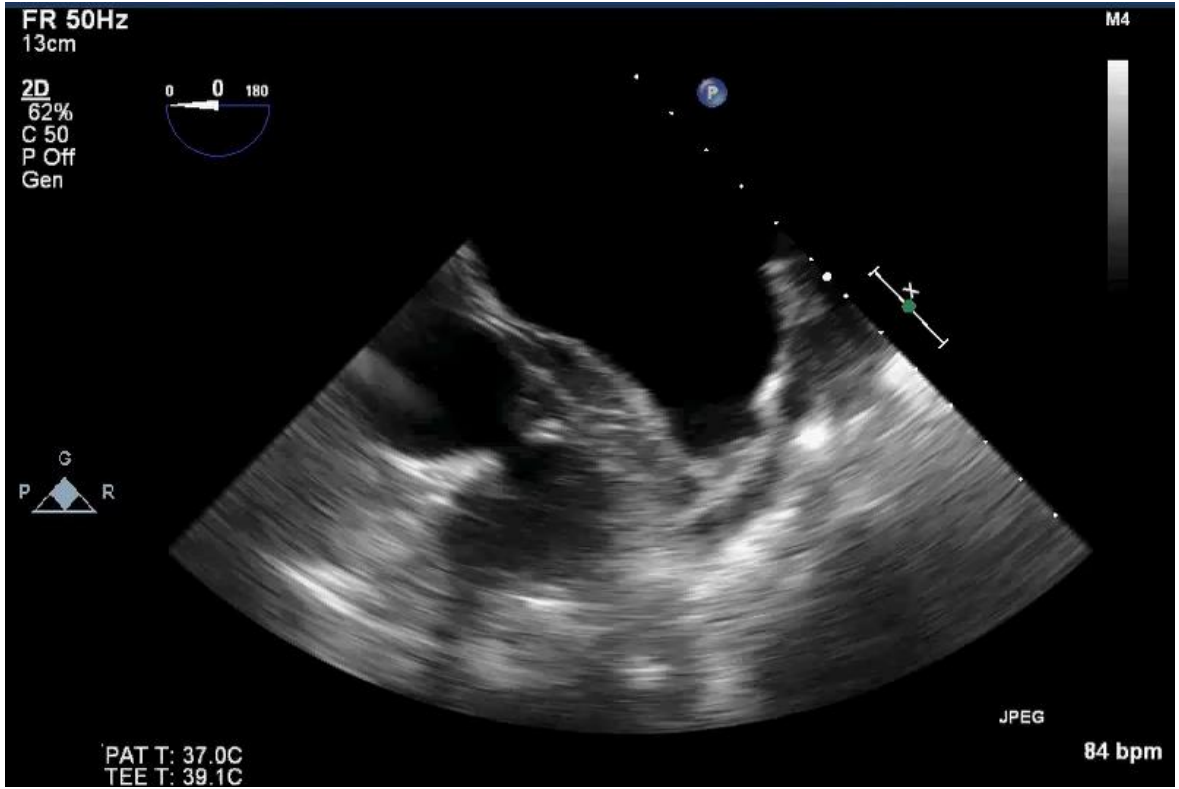

LAA assessment

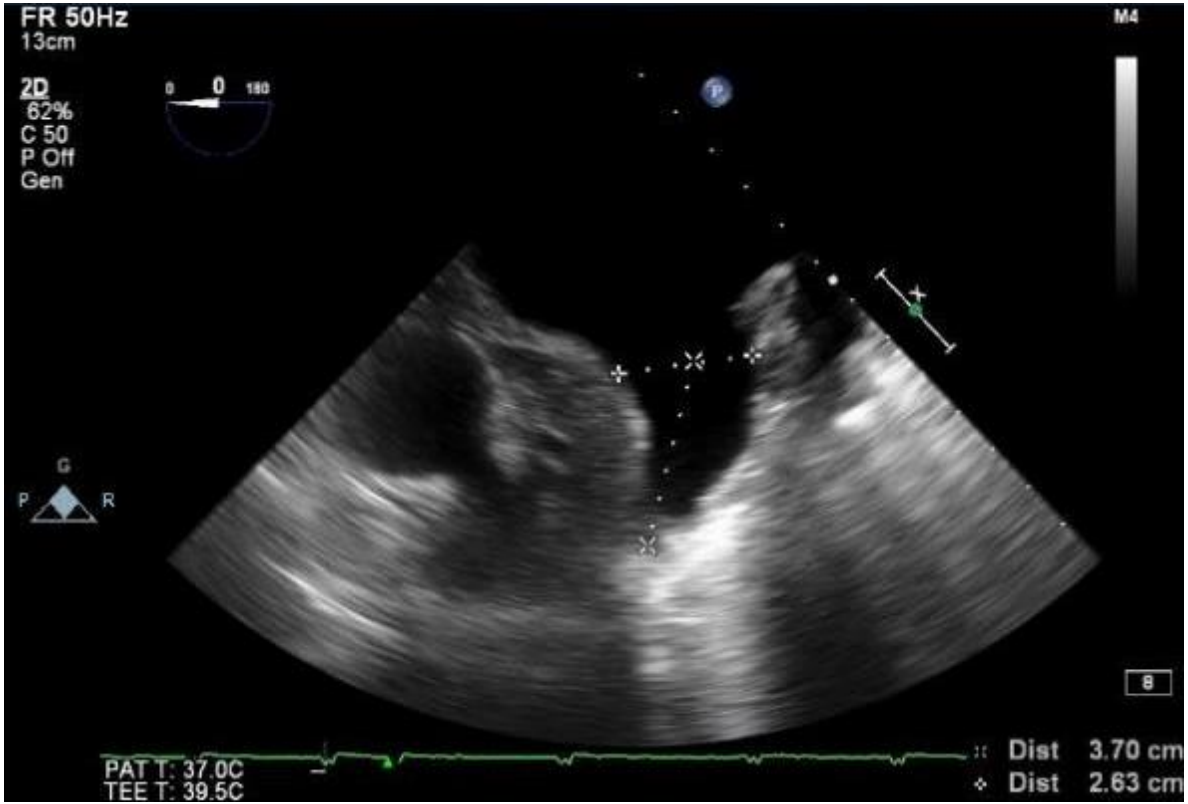

45 degrees

LAA assessment

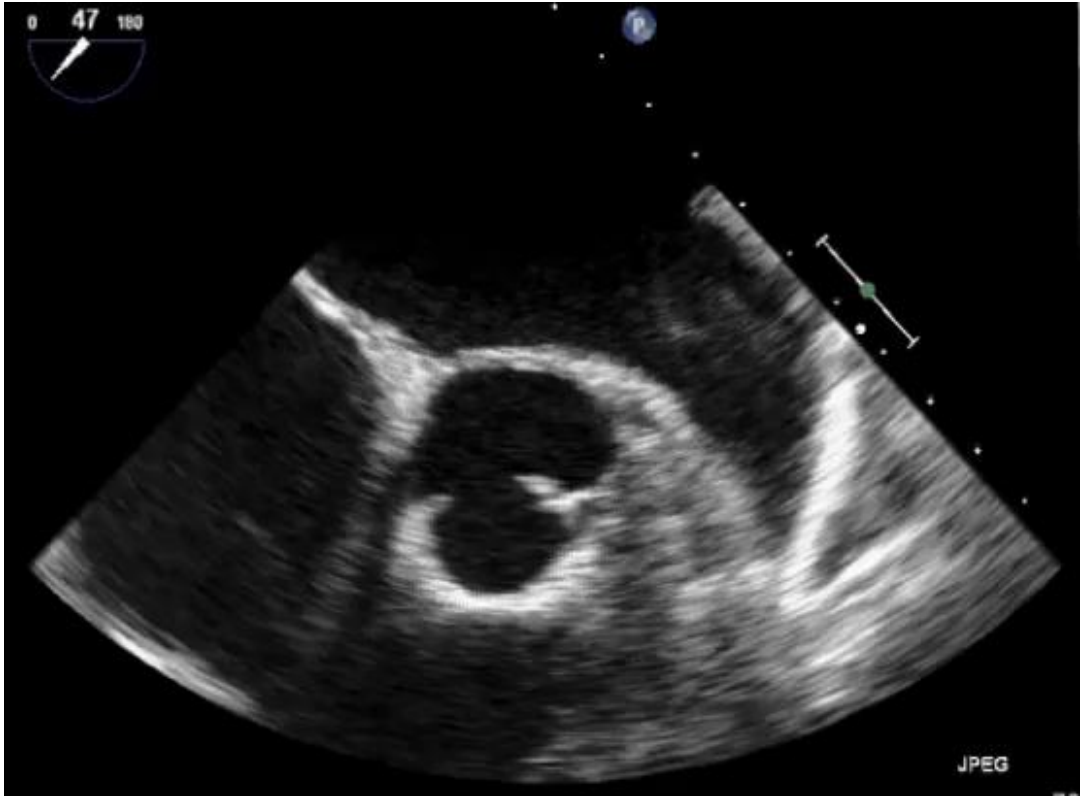

EACVI
EUROPEAN SOCIETY OF CARDIOLOGY

LAA assessment

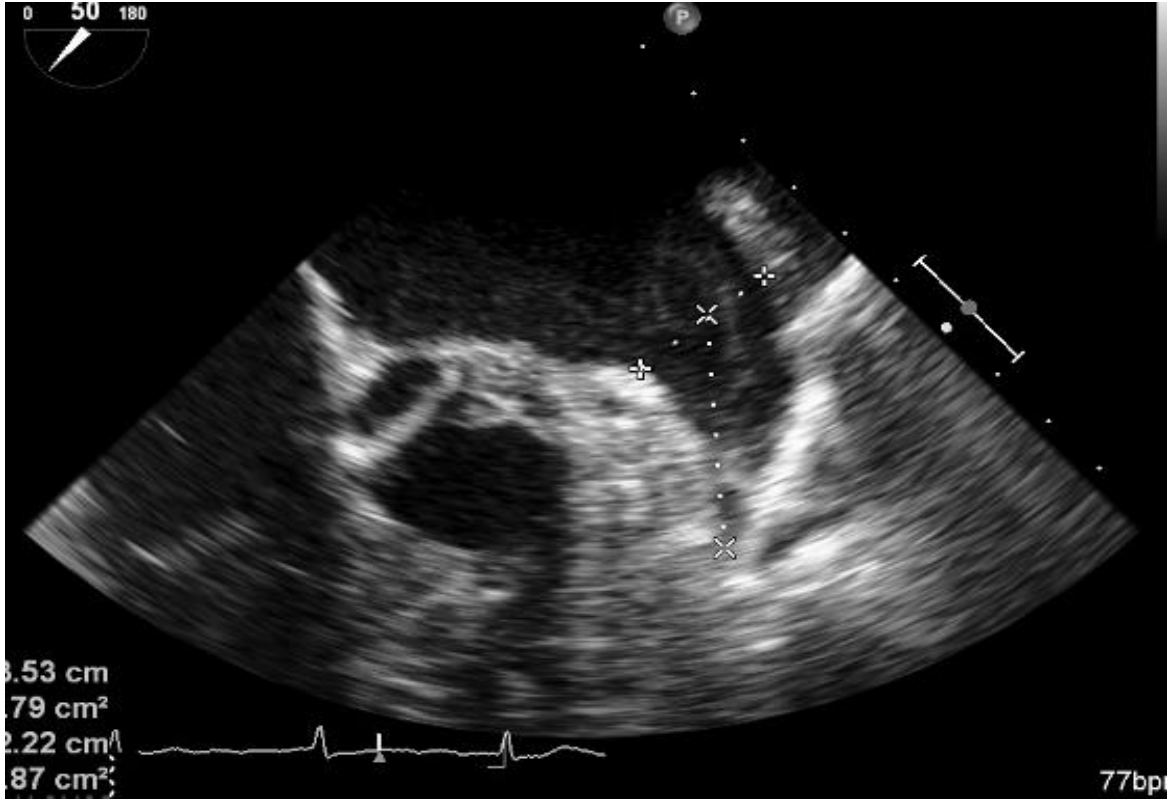

90 degrees

LAA assessment

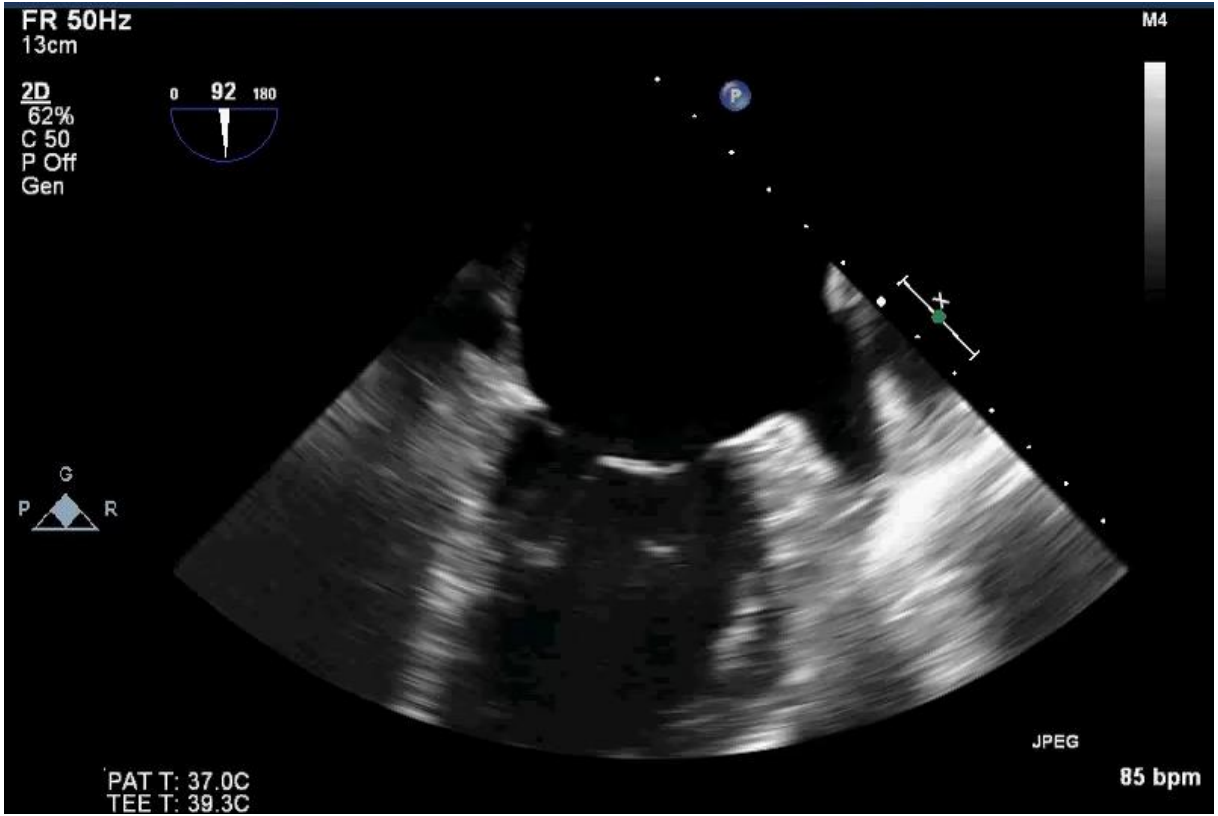

LAA assessment

135 degrees

LAA assessment

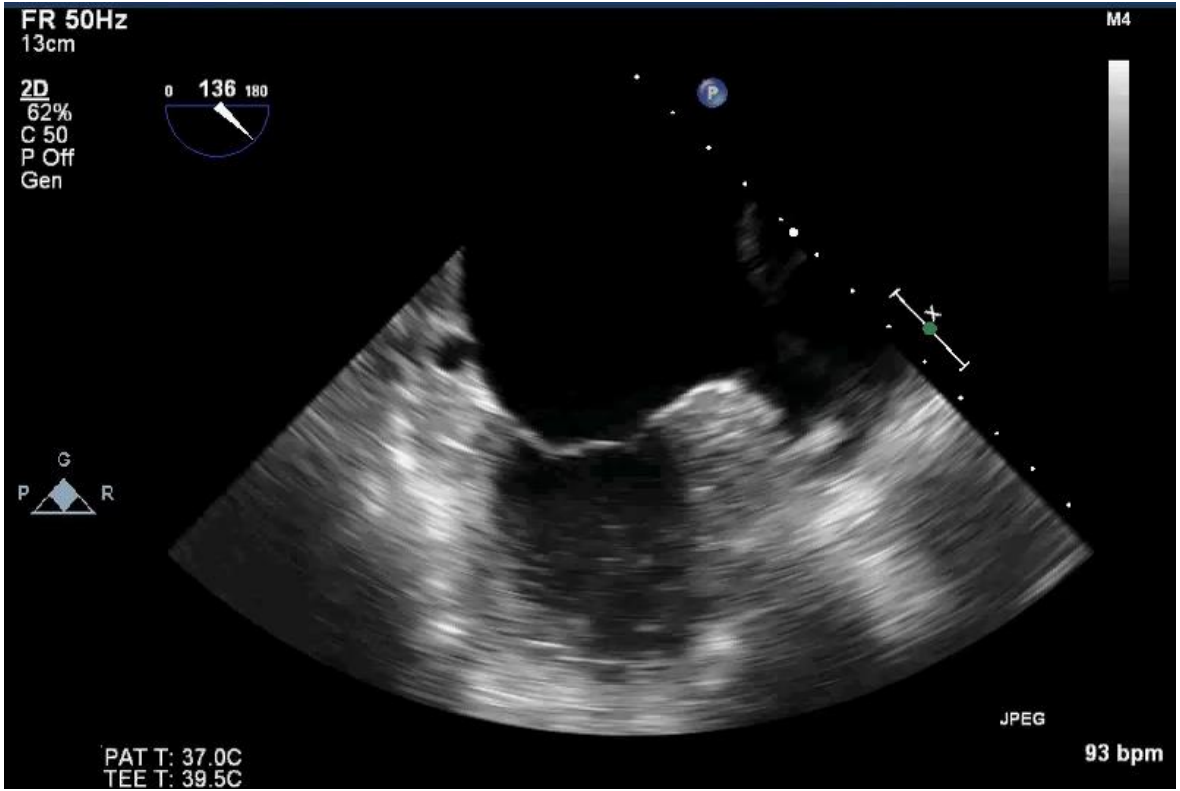

LAA assessment

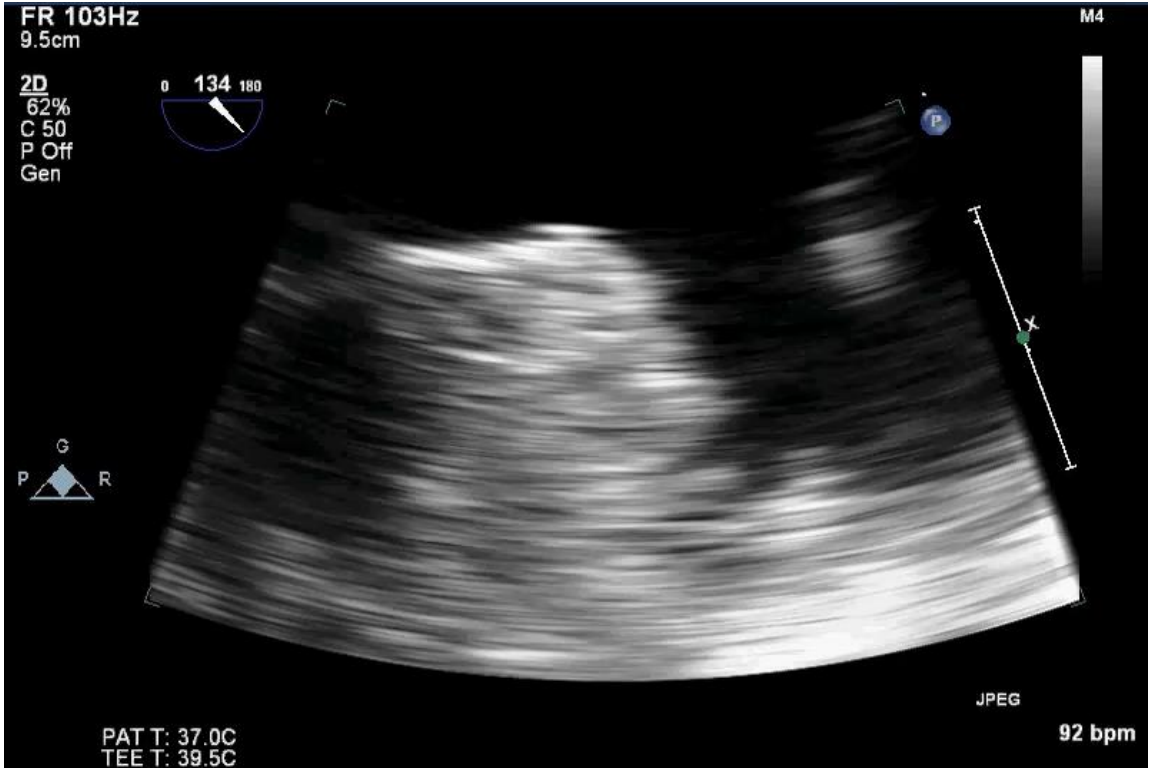

LAA assessment

3D-TEE

LAA assessment

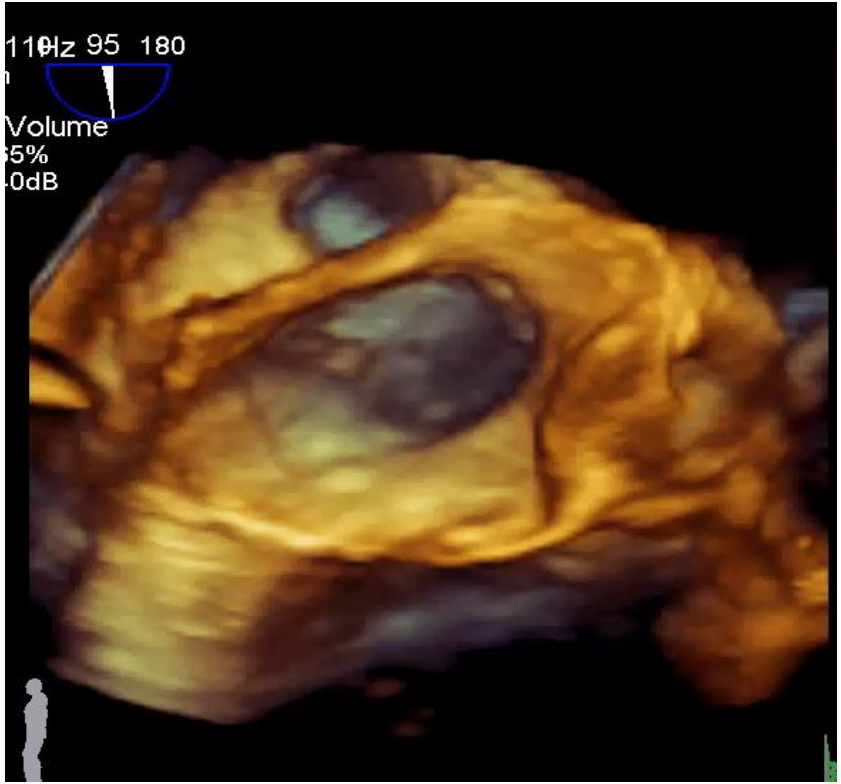

EACVI

EUROPEAN SOCIETY OF CARDIOLOGY

LAA assessment

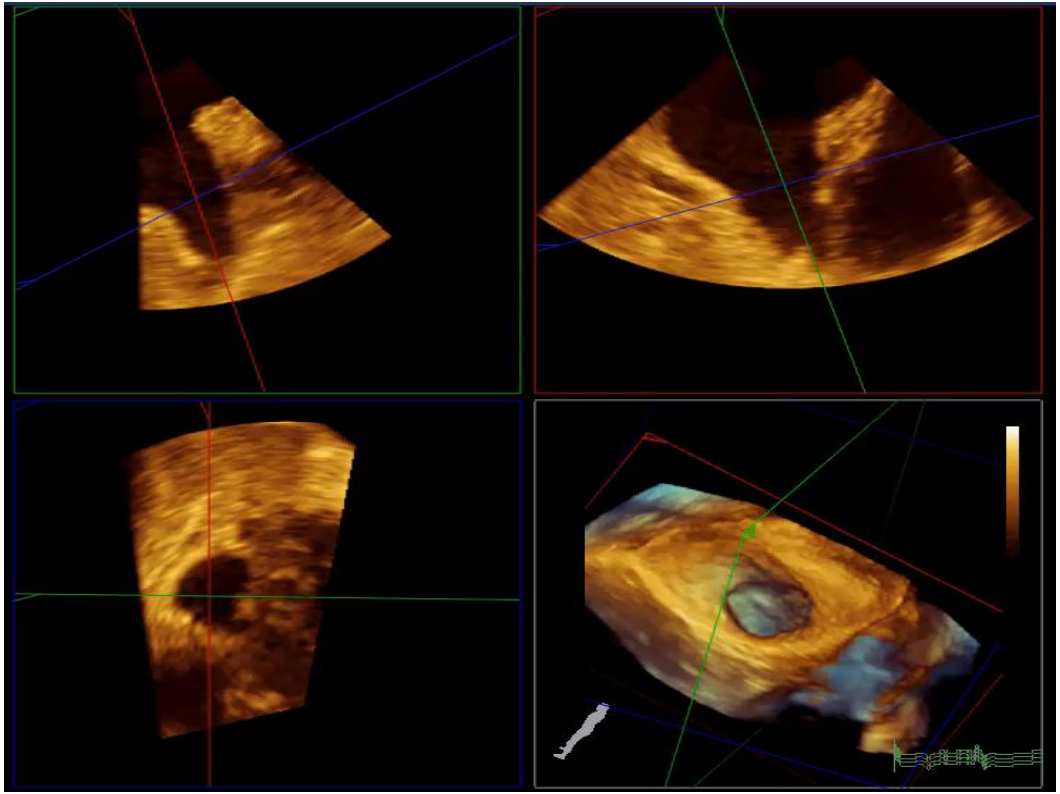

LAA assessment

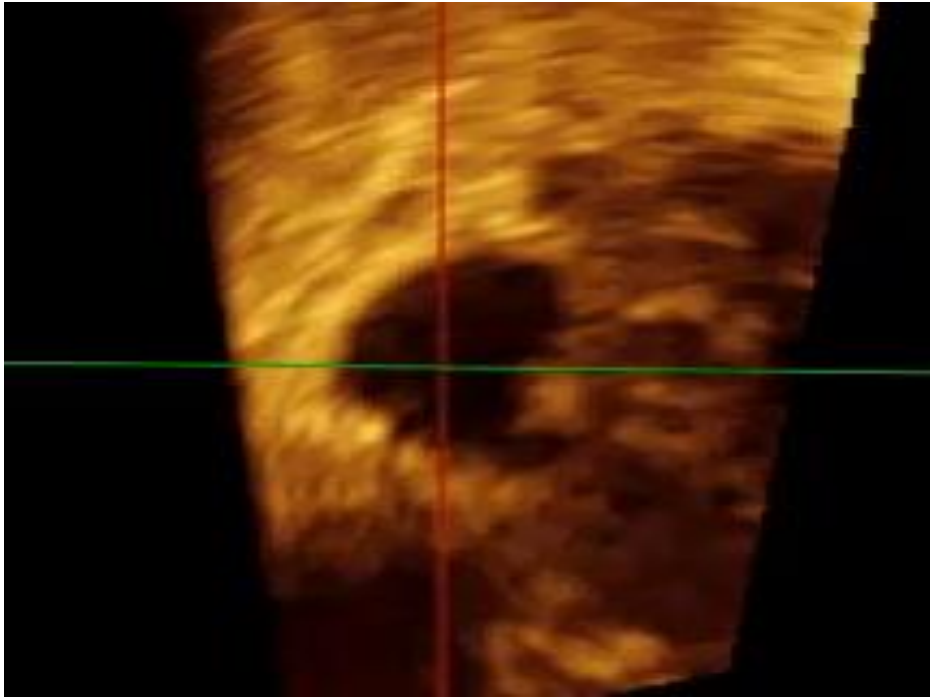

LAA assessment

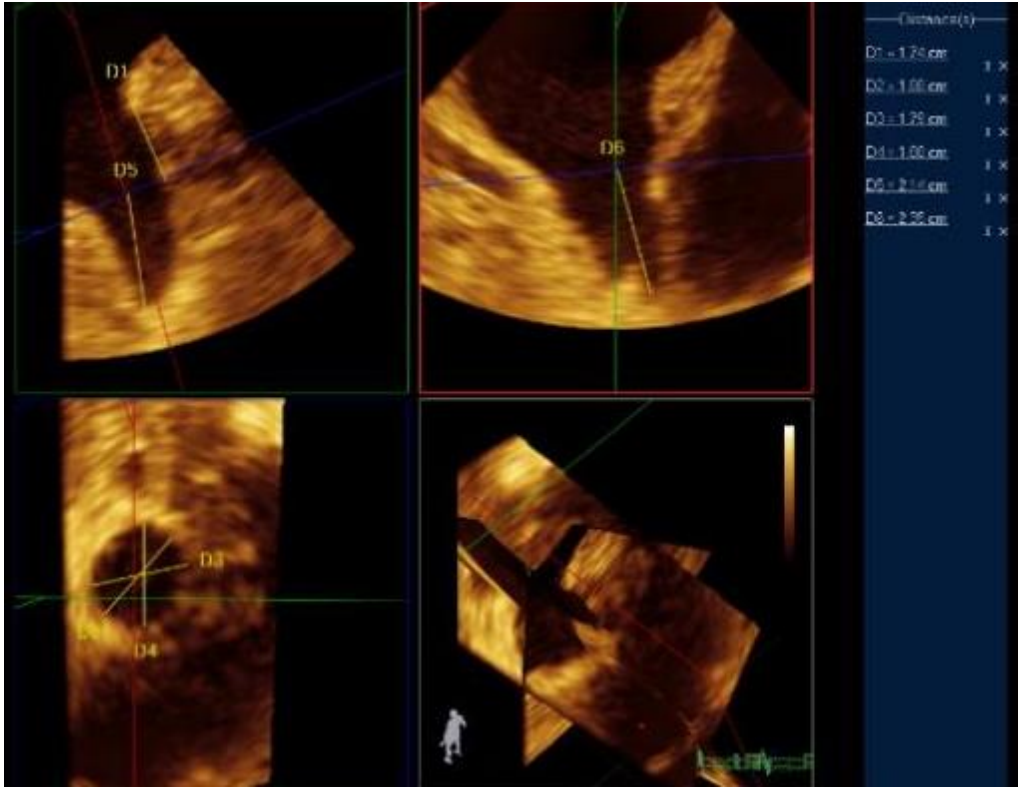

LAA assessment

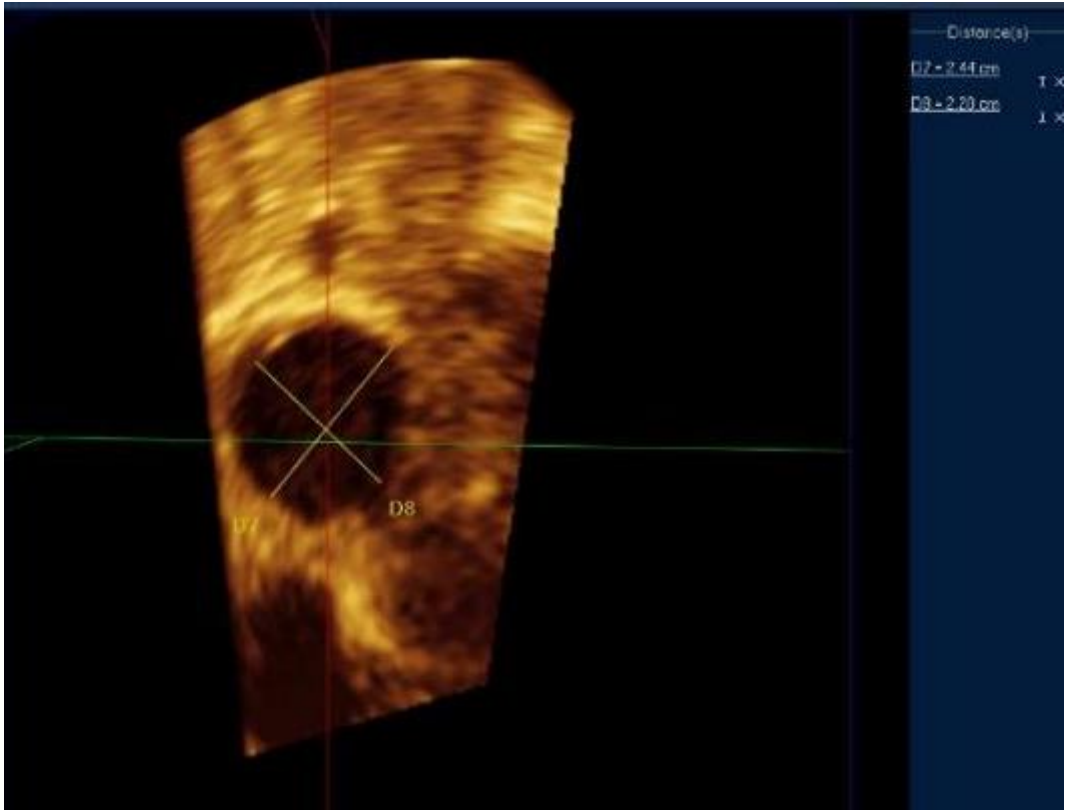

LAA assessment

3D-TOE

Circulation
Cardiovascular Imaging

American Heart Association®

Evaluation of the Left Atrial Appendage With Real-Time 3-Dimensional Transesophageal Echocardiography: Implications for Catheter-Based Left Atrial Appendage Closure

Gaetano Nucifora, Francesco F. Faletra, François Regoli, Elena Pasotti, Giovanni Pedrazzini, Tiziano Moccetti and Angelo Auricchio

Circ Cardiovasc Imaging. 2011;4:514-523; originally published online July 7, 2011;
doi: 10.1161/CIRCIMAGING.111.963892

LAA assessment

3D-TOE

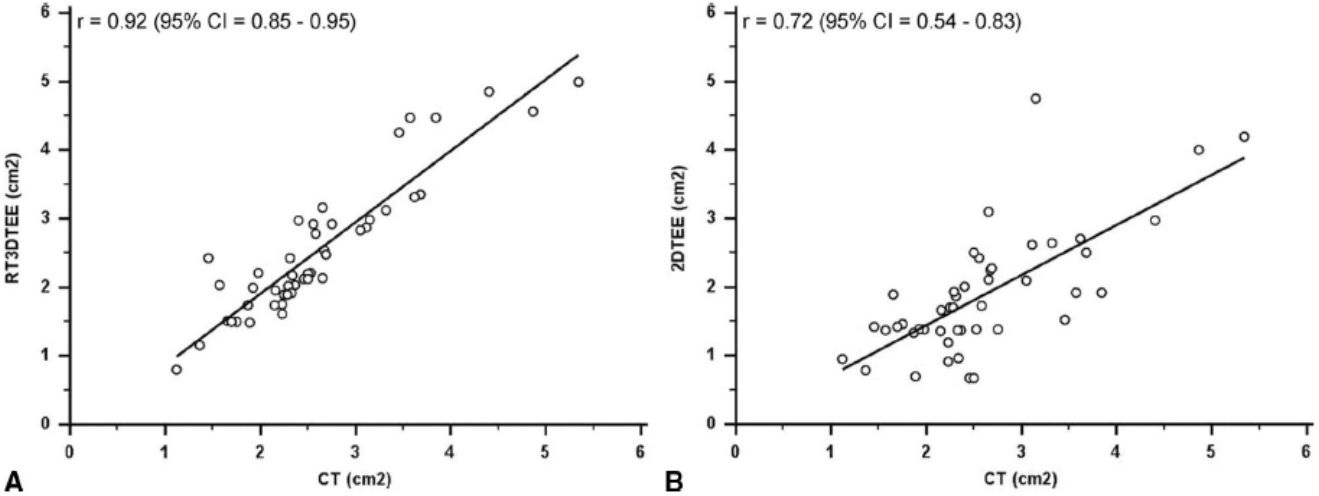

Figure 2. Scatterplots of linear regression analysis for real-time 3D transesophageal echocardiography (RT3DTEE) (**A**) and 2D transesophageal echocardiography (2DTEE) (**B**) measurements of the left atrial appendage (LAA) orifice area versus the computed tomography (CT) reference values.

Nucifora et al RT3DTEE Imaging of LAA Circ Cardiovasc 2011;4:514-523

Dr. Hani Mahmoud

CIC

مركز فحوصات القلب

CARDIAC INVESTIGATION CENTER

www.ciceg.net